

Staged Endovascular Treatment of Ruptured Vertebral Artery Dissection Involving the Posterior Inferior Cerebellar Artery

Abstract

In the treatment of vertebral artery (VA) dissection involving the origin of the posterior inferior cerebellar artery (PICA), the prevention of rebleeding and the preservation of VA and PICA patency are challenging. We report a case with ruptured VA dissection involving the origin of the PICA. In the acute stage, the fusiform dilatation of the dissection was first treated by means of stent-assisted coil embolization. Dual-antiplatelet therapy was administered just before stent placement. Seven days after the first treatment, two additional stents without coils were added. Rebleeding did not occur, and the lesion was thrombosed successfully 4 days after the second treatment, with the preservation of VA and PICA patency. This staged therapy appears to be beneficial in preventing rebleeding and in preserving VA and PICA patency.

Keywords: Antiplatelet therapy, endovascular treatment, stent-assisted coil embolization, vertebral artery dissection

Introduction

Ruptured vertebral artery (VA) dissection has a high risk of rapid rebleeding and must be treated quickly.^[1] In the treatment of VA, dissection involving the origin of the posterior inferior cerebellar artery (PICA), the prevention of rebleeding, and the preservation of VA and PICA patency are challenging. Herein, we first report a staged therapy of ruptured VA dissection involving PICA, with the preservation of the patency of VA and PICA without cerebral infarction.

Case Report

A 48-year-old male patient presenting with sudden headache and disturbance of consciousness was referred. A computed tomography scan revealed subarachnoid hemorrhage (SAH) with acute hydrocephalus, the World Federation of Neurosurgical Societies Grade IV [Figure 1a]. Emergency digital subtraction angiography (DSA) under general anesthesia demonstrated stenosis and fusiform dilatation of left VA [Figure 1b and c] and double origin of PICA^[2,3] [Figure 1c-e, white arrow]. The diameter of the left VA was 4.2 mm and the diameter of the main branch of the PICA

was 1.2 mm. A diagnosis of ruptured VA dissection involving PICA was made.

First, ventricular drainage was performed on day 0. Endovascular therapy was performed on day 1 under general anesthesia. For stenting, a Prowler Select Plus microcatheter (Codman and Shurtleff, Inc., Raynham, MA) was placed into the left VA, using a contralateral approach. For coil embolization, two Excelsior SL-10 microcatheters (Stryker, Kalamazoo, MI) were placed into the fusiform dilatation of left VA, using an ipsilateral approach. Immediately after the two coils were placed, loading doses of aspirin (200 mg) and clopidogrel (300 mg) were administered. An Enterprise 2 4.0 mm × 30 mm stent (Codman and Shurtleff, Inc.) was placed over the whole lesion of left VA. Then, coil embolization was added. Postoperative DSA (venous phase) showed contrast medium stagnated at the fusiform dilatation [Figure 1f, white arrowhead].

VA and PICA patency was preserved and a postoperative magnetic resonance imaging scan showed no infarction at the medulla oblongata or PICA territory. After the first treatment, to monitor the neurological condition, the patient was kept with the awake condition, under strict control of blood pressure. Dual-antiplatelet

Yukihiro Yamao^{1,2},
Eiji Ogino^{1,3},
Sadaharu
Torikoshi^{1,2},
Waro Taki¹,
Masaki Nishimura^{1,4}

¹Department of Neurosurgery,
Koseikai Takeda Hospital,

²Department of Neurosurgery,
Kyoto University Graduate
School of Medicine,

³Department of Neurosurgery,
Uji Tokushukai Medical
Center, Kyoto, ⁴Department of

Neurosurgery, National Cerebral
and Cardiovascular Center,
Suita, Osaka, Japan

Address for correspondence:

Dr. Masaki Nishimura,
Koseikai Takeda Hospital,
841-5, Higashi Shiokoji-cho,
Shimogyo-ku, Kyoto 600-8558,
Japan.

E-mail: masakins@kuhp.kyoto-u.ac.jp

Access this article online

Website: www.asianjns.org

DOI: 10.4103/ajns.AJNS_251_18

Quick Response Code:



How to cite this article: Yamao Y, Ogino E, Torikoshi S, Taki W, Nishimura M. Staged endovascular treatment of ruptured vertebral artery dissection involving the posterior inferior cerebellar artery. *Asian J Neurosurg* 2019;14:561-4.

This is an open access journal, and articles are distributed under the terms of the Creative Commons Attribution-NonCommercial-ShareAlike 4.0 License, which allows others to remix, tweak, and build upon the work non-commercially, as long as appropriate credit is given and the new creations are licensed under the identical terms.

For reprints contact: reprints@medknow.com

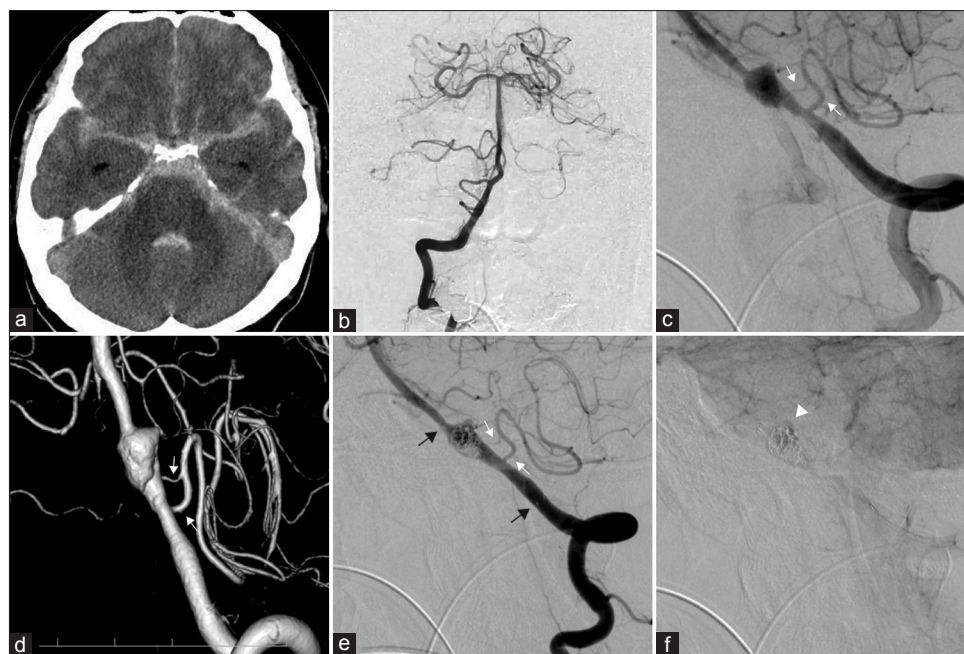


Figure 1: (a) A computed tomography scan on admission shows a massive subarachnoid hemorrhage. (b) Right vertebral angiography. (c) Left vertebral angiography demonstrates the stenosis and fusiform dilation of the left vertebral artery. (d) Three-dimensional digital subtraction angiography reveals double origin of the posterior inferior cerebellar artery: one from the dilatation itself, and the other from the stenosis proximal to the dilatation. (e) Coil embolization of the fusiform dilatation with stenting is performed (arrow; flared ends of the stent). Vertebral artery and posterior inferior cerebellar artery patency was preserved. (f) Postoperative digital subtraction angiography (venous phase) showed contrast medium stagnated in the fusiform dilatation. White arrows (c-e) show double origin of posterior inferior cerebellar artery

therapy (DAPT) continued with aspirin 100 mg/day and clopidogrel 75 mg/day.

Although rebleeding did not occur, follow-up DSA performed 2 days after the first treatment showed enlargement just proximal to the coil mass [Figure 2a, double arrows], but contrast medium still stagnated in the fusiform dilatation [Figure 2b, double white arrowheads]. After a plateau of inhibition of platelet aggregation achieved, a second endovascular therapy was performed 7 days after the first treatment. Under local anesthesia, an Enterprise 2 4.0 mm × 30 mm stent was placed at the enlargement of the dissection, and an Enterprise 2 4.0 mm × 39 mm stent was placed to overlap the two former stents [Figure 2c]. We expected a flow-diversion effect with the additional stent placement; thus, no coils were added.

Follow-up DSA on day 12 (4 days after the second treatment) showed thrombosis of the lesion [Figure 2d]. After it was confirmed that repeated DSA performed before the shunt operation did not show regrowth, DAPT was changed to single-antiplatelet therapy about 1 month after second treatment due to a lumboperitoneal shunt operation for hydrocephalus. DSA performed 6 months after the onset did not show regrowth [Figure 2e]. Single-antiplatelet therapy has been administered, and the patient has displayed no neurological deficits over 3 years after the onset [Figure 2f].

Discussion

VA dissection is normally idiopathic and is an uncommon cause of SAH. The rebleeding rate of ruptured VA dissection

has been reported to be as high as 71.4% of cases; moreover, rebleeding has led to a high mortality rate.^[1,4] All possible endovascular treatment options for ruptured VA dissection involving PICA were listed as follows: parent artery occlusion with/without bypass, stent-assisted coiling, and stenting. Internal trapping or proximal/distal occlusion of parent VA by coil embolization has become the first-line treatment for ruptured VA dissection; however, parent artery occlusion for VA dissection involving PICA carries a risk of severe ischemic complications, even if occipital artery-PICA anastomosis is performed.^[5,6] In addition, *de novo* VA dissecting aneurysms after trapping or occlusion of a dissecting aneurysm in contralateral VA have been reported, likely due to excessive hemodynamic stress, even if the occlusion side was not the dominant side.^[7,8] Therefore, preservation of VA and PICA patency in treatment for VA dissection involving PICA is necessary. To preserve PICA patency, it was reported that an Enterprise stent was deployed from the PICA to the proximal VA and the segment of dissection was completely occluded by coils.^[9] However, evidence detailing the feasibility, use, or safety of Enterprise stents in small cerebral vessels (<2 mm in diameter) is lacking. We did not use this strategy in this case, as the diameter of the PICA was 1.2 mm and the PICA had two origins.

We selected the strategy of stent-assisted coiling in the acute stage to prevent rebleeding. In a review of ruptured and unruptured VA dissection,^[10] rebleeding was found to occur in 6.9% of ruptured VA dissection

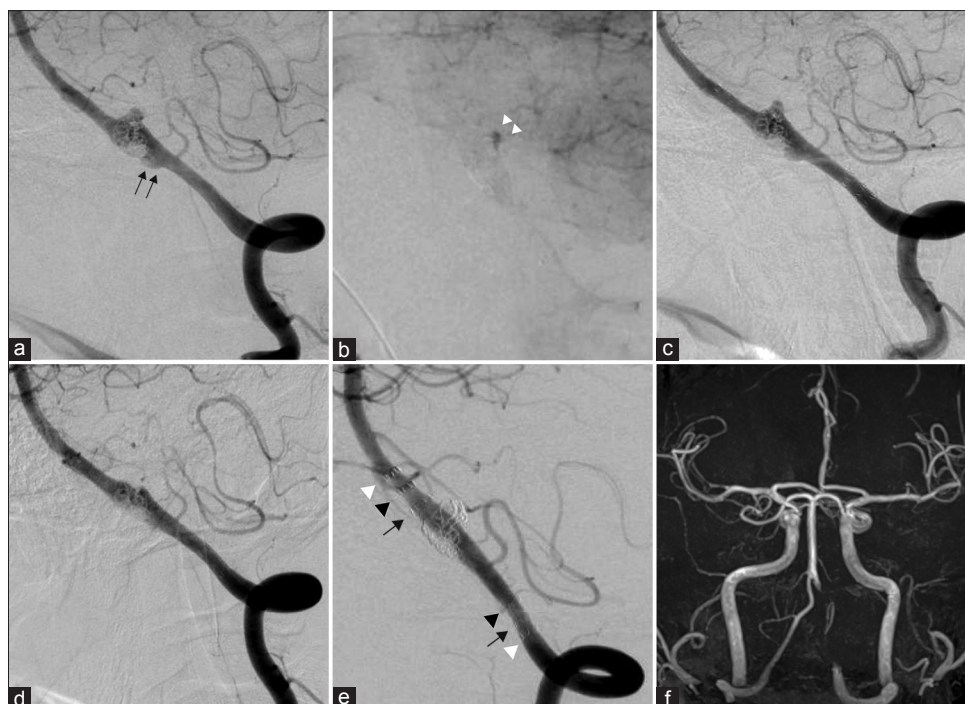


Figure 2: (a and b) Digital subtraction angiography 2 days after the first treatment demonstrates the enlargement of the fusiform dilatation (a, double arrows), but contrast medium remained stagnated (b, double white arrowheads). (c) Two stents were added at the fusiform dilatation (the second stent) and the left vertebral artery over the two stents (the third stent) 7 days after the first treatment. (d) Digital subtraction angiography 4 days after the second treatment demonstrates thrombosis. (e) Digital subtraction angiography 6 months after the onset shows no regrowth (arrow, flared ends of the first stent; arrowhead, those of the second stent; and white arrowhead, those of the third stent). (f) Magnetic resonance angiography 2 years after procedure shows preservation of left posterior inferior cerebellar artery and no dilatation of the right vertebral artery

treated using stent placement and coils. This suggests that stent-assisted coiling alone does not completely eliminate the risk of rebleeding or enlargement of dissection.^[11] Careful follow-up study is required to check for enlargement of residual dissection after stent-assisted coiling. On the contrary, due to a delay in aneurysmal occlusion and high complication rate, treatment using flow diverter stents without coil embolization may not be suitable for ruptured aneurysms in the acute stage.^[12,13] In addition, patients with ruptured VA dissection cannot receive premedication with antiplatelet agents, resulting in more frequent thromboembolic complications.^[11] Placement of multiple stents or flow diverter stents in the acute stage potentially risks inducing thromboembolic complications.^[13] In this case, DAPT continued after the first stent placement. After clopidogrel achieved a plateau of inhibition of platelet aggregation after 3–7 days,^[14] two additional Enterprise stents were added to achieve a “flow diversion” effect because a low-profile visualized intraluminal support (LVIS) stent (MicroVention/Terumo, Aliso Viejo, CA) was not available in Japan at that time. In an aneurysm model study,^[15] reduction in the velocity within the aneurysm sac using two Enterprise stents was not as significant as that achieved using flow diverter stents. Consistent with this finding, treatment using one Enterprise stent with coil embolization resulted in the enlargement of the fusiform dilatation, and 4 days after two additional Enterprise stents were deployed (three

Enterprise stents in total), the lesion was thrombosed. Therefore, at least three Enterprise stents might be needed to achieve the flow diversion effect.

No protocol has been established for the management of antiplatelet therapy in cases of stent-assisted coil embolization for ruptured VA dissection. In this case, DAPT was changed to single-antiplatelet therapy about 1 month after the procedure due to a shunt operation, since DAPT was a significant risk factor for hemorrhagic complications associated with ventriculoperitoneal shunt placement.^[16] In previous studies for unruptured aneurysms, the stent-containing vessel with incomplete aneurysm occlusion is a risk factor for a delayed thromboembolic event,^[17] and long-term DAPT did not prevent the incidence of delayed thromboembolic events.^[18] In this case, due to confirmation of thrombosis of the lesion, single-antiplatelet therapy has been administered without delayed thromboembolic event, but further studies are warranted to determine the optimal antiplatelet therapy for ruptured aneurysms.

Conclusion

Preventing rebleeding and preserving VA and PICA patency can be challenging in treatment of PICA-involved VA dissection. The reported therapy might be a treatment option.

Declaration of patient consent

The authors certify that they have obtained all appropriate patient consent forms. In the form the patient has given his consent for his images and other clinical information to be reported in the journal. The patient understands that his name and initials will not be published and due efforts will be made to conceal their identity, but anonymity cannot be guaranteed.

Financial support and sponsorship

Nil.

Conflicts of interest

There are no conflicts of interest.

References

- Mizutani T, Aruga T, Kirino T, Miki Y, Saito I, Tsuchida T, *et al.* Recurrent subarachnoid hemorrhage from untreated ruptured vertebrobasilar dissecting aneurysms. *Neurosurgery* 1995;36:905-11.
- Uchino A, Saito N, Ishihara S. Double origin of the posterior inferior cerebellar artery diagnosed by MR angiography: A report of two cases. *Neuroradiol J* 2015;28:187-9.
- Lesley WS, Rajab MH, Case RS. Double origin of the posterior inferior cerebellar artery: Association with intracranial aneurysm on catheter angiography. *AJR Am J Roentgenol* 2007;189:893-7.
- Aoki N, Sakai T. Rebleeding from intracranial dissecting aneurysm in the vertebral artery. *Stroke* 1990;21:1628-31.
- Endo H, Matsumoto Y, Kondo R, Sato K, Fujimura M, Inoue T, *et al.* Medullary infarction as a poor prognostic factor after internal coil trapping of a ruptured vertebral artery dissection. *J Neurosurg* 2013;118:131-9.
- Satow T, Ishii D, Iihara K, Sakai N, JR-NET Study Group. Endovascular treatment for ruptured vertebral artery dissecting aneurysms: Results from Japanese registry of neuroendovascular therapy (JR-NET) 1 and 2. *Neurol Med Chir (Tokyo)* 2014;54 Suppl 2:98-106.
- Inui Y, Oiwa Y, Terada T, Nakakita K, Kamei I, Hayashi S, *et al.* *De novo* vertebral artery dissecting aneurysm after contralateral vertebral artery occlusion – two case reports. *Neurol Med Chir (Tokyo)* 2006;46:32-6.
- Sakamoto S, Ohba S, Shibukawa M, Kiura Y, Okazaki T, Kurisu K, *et al.* Transient headache related to enlargement of the contralateral vertebral artery after vertebral artery occlusion. *Surg Neurol* 2008;70:463-5.
- Chung J, Kim BS, Lee D, Kim TH, Shin YS. Vertebral artery occlusion with vertebral artery-to-posterior inferior cerebellar artery stenting for preservation of the PICA in treating ruptured vertebral artery dissection. *Acta Neurochir (Wien)* 2010;152:1489-92.
- Suzuki S, Kurata A, Iwamoto K, Sato K, Niki J, Miyazaki T, *et al.* Endovascular surgery using stents for vertebral artery dissecting aneurysms and a review of the literature. *Minim Invasive Neurosurg* 2008;51:193-8.
- Ota T, Sato M, Amano T, Saito A, Matsumaru Y. Reconstructive endovascular treatment of ruptured vertebral artery dissection involving the posterior inferior cerebellar artery. *Acta Neurochir (Wien)* 2016;158:1089-93.
- Fischer S, Vajda Z, Aguilar Perez M, Schmid E, Hopf N, Bätzner H, *et al.* Pipeline embolization device (PED) for neurovascular reconstruction: Initial experience in the treatment of 101 intracranial aneurysms and dissections. *Neuroradiology* 2012;54:369-82.
- Cagnazzo F, di Carlo DT, Cappucci M, Lefevre PH, Costalat V, Perrini P. Acutely ruptured intracranial aneurysms treated with flow-diverter stents: A systematic review and meta-analysis. *AJNR Am J Neuroradiol* 2018;39:1669-75.
- Oprea AD, Popescu WM. Perioperative management of antiplatelet therapy. *Br J Anaesth* 2013;111 Suppl 1:i3-17.
- Kojima M, Irie K, Fukuda T, Arai F, Hirose Y, Negoro M, *et al.* The study of flow diversion effects on aneurysm using multiple enterprise stents and two flow diverters. *Asian J Neurosurg* 2012;7:159-65.
- Hudson JS, Nagahama Y, Nakagawa D, Starke RM, Dlouhy BJ, Torner JC, *et al.* Hemorrhage associated with ventriculoperitoneal shunt placement in aneurysmal subarachnoid hemorrhage patients on a regimen of dual antiplatelet therapy: A retrospective analysis. *J Neurosurg* 2018;129:916-21.
- Hwang G, Kim JG, Song KS, Lee YJ, Villavicencio JB, Suroto NS, *et al.* Delayed ischemic stroke after stent-assisted coil placement in cerebral aneurysm: Characteristics and optimal duration of preventative dual antiplatelet therapy. *Radiology* 2014;273:194-201.
- Kim T, Kim CH, Kang SH, Ban SP, Kwon OK. Relevance of antiplatelet therapy duration after stent-assisted coil embolization for unruptured intracranial aneurysms. *World Neurosurg* 2018;116:e699-708.