

# Pyothorax-associated Angiosarcoma Metastasized to the Brain with Multiple and Progressively Expanding Hematomas: Case Report and Literature Review

## Abstract

The brain metastasis of angiosarcoma is very rare, and little is known about its clinical features or therapeutic strategy. A 74-year-old male was hospitalized for disturbance of consciousness. Radiological examination revealed multiple cerebral hematomas. Gadolinium contrast-enhanced magnetic resonance imaging showed no significant enhancement at any of the lesions. To detect a suspected metastatic brain tumor or abscess, a full-body scan was performed but revealed only a poorly enhanced mass in the removal cavity caused by thoracoplasty in the left upper chest. After admission, a cascade of expansion of those hematomas occurred in the right frontal, left parietal, and right temporal lobes, and each lesion thus had to be sequentially removed by craniotomies. The pathological diagnosis of the right frontal lesion was an abscess with hematoma. However, a malignant vascular tumor was highly suspected because of many CD31(+)/Ki-67(+) cells in the left parietal lesion. A mass in the scar caused by thoracoplasty was suspected to be the primary lesion, and brain metastasis of angiosarcoma was finally diagnosed. Whole-brain irradiation and systemic paclitaxel administration were performed, and a complete response for the brain lesions was obtained for 22 months; the patient then died of an intratracheal hemorrhage. This case represents the first report of multiple brain metastases from pyothorax-associated angiosarcoma accompanied by sequentially and gradually expanding hematomas, as well as the first case with the control of metastatic brain lesions for over 1 year after the onset of neurological symptoms. Control of the lesions could be achieved by their total removal with complete hemostasis, as well as additional radio- and chemotherapy.

**Keywords:** *Angiosarcoma, brain metastasis, expanding hematoma, pyothorax*

## Introduction

Angiosarcomas are aggressive and rare malignancies, representing <1% of all sarcomas. Angiosarcomas can metastasize to various organs, but only a small number of reports have described brain metastasis<sup>[1-33]</sup> including only one pyothorax-associated angiosarcoma.<sup>[20]</sup> Therefore, the clinical features and therapeutic strategies for such cases have not been well elucidated. Here, we report a case of pyothorax-associated angiosarcoma metastasized to the brain with multiple and sequentially expanding intracerebral hematomas. This case represents the first report of the control of metastatic brain lesions for over 1 year after the onset of neurological symptoms. The specific clinical course, radiological findings, and therapeutic strategies are discussed, and a comprehensive literature review is included.

This is an open access journal, and articles are distributed under the terms of the Creative Commons Attribution-NonCommercial-ShareAlike 4.0 License, which allows others to remix, tweak, and build upon the work non-commercially, as long as appropriate credit is given and the new creations are licensed under the identical terms.

For reprints contact: [reprints@medknow.com](mailto:reprints@medknow.com)

## Methods

The informed consent of the patient's spouse was acquired for data publication, and Institutional Review Board approval of Shimane University was obtained, and the patient's informed consent was not required.

## Case Report

A 74-year-old male with past histories of thoracoplasty for tuberculosis (50 years earlier) and transurethral resection of bladder cancer (7 years earlier) was hospitalized with disturbance of consciousness. Head computed tomography (CT) revealed four hematomas with perifocal edema [Figure 1a-c], suggesting several different diagnoses, including a metastatic brain tumor, brain abscess, hemorrhage from bacterial aneurysms, or other vascular

How to cite this article: Hagiwara S, Miyazaki T, Ishikawa N, Nakagawa F, Maruyama R, Akiyama Y. Pyothorax-associated angiosarcoma metastasized to the brain with multiple and progressively expanding hematomas: Case report and literature review. *Asian J Neurosurg* 2017;XX:XX-XX.

**Shinya Hagiwara,  
Takeshi Miyazaki,  
Noriyoshi Ishikawa<sup>1</sup>,  
Fumio Nakagawa,  
Riruke Maruyama<sup>1</sup>,  
Yasuhiko Akiyama**

*Departments of Neurosurgery and <sup>1</sup>Pathology, Faculty of Medicine, Shimane University, Izumo, Shimane 693-8501, Japan*

### Address for correspondence:

*Dr. Takeshi Miyazaki,  
Department of Neurosurgery,  
Faculty of Medicine, Shimane  
University, 89-1 Enya, Izumo,  
Shimane 693-8501, Japan.  
E-mail: [takeshi@  
med.shimane-u.ac.jp](mailto:takeshi@med.shimane-u.ac.jp)*

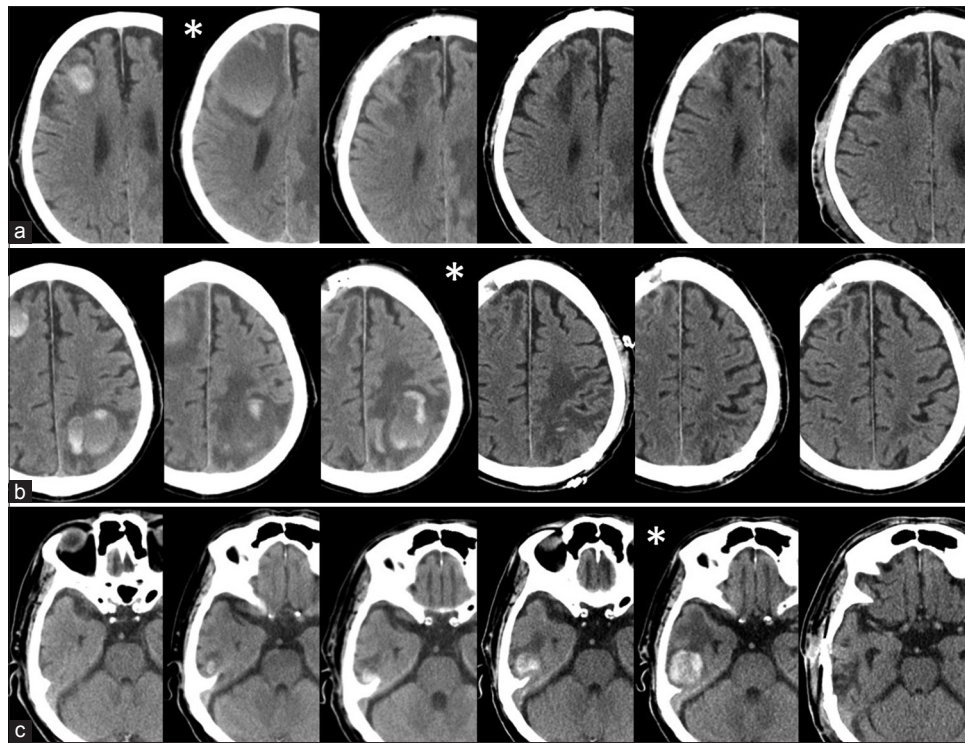
Access this article online

Website: [www.asianjns.org](http://www.asianjns.org)

DOI: 10.4103/ajns.AJNS\_250\_16

Quick Response Code:





**Figure 1:** Serial images of computed tomography; right frontal lobe hematoma (a), left parietal lobe hematoma (b), right temporal lobe hematoma (c). Each asterisk (\*) indicates the timing of surgical interventions

abnormality such as cavernoma. On the magnetic resonance imaging (MRI) results [Figure 2a-f], diffusion-weighted imaging showed low signal intensity [Figure 2e], and T2\* imaging exhibited very low signal intensity at all lesions [Figure 2d]. Gadolinium (Gd) contrast-enhanced MRI showed no significant enhancement at any of the lesions [Figure 2f]. Blood testing revealed no evidence of infection. A whole-body CT scan found a poorly enhanced mass in the removal cavity caused by thoracoplasty in the left upper chest [Figure 3a].

A CT-guided biopsy for the thoracic lesion was performed, but only necrotic tissue was obtained. The right frontal lobe hematoma gradually enlarged, and the patient's consciousness became drowsier. Therefore, total removal of the hematoma was performed through emergent craniotomy [Figure 1a]. The pathological diagnosis of the specimen was an abscess with bleeding, but the intraoperative view of the hematoma was that of a chronic subdural hematoma. Accordingly, carbapenem antibiotics were initiated based on the diagnosis. Various blood cultures and polymerase chain reaction results for acid-fast bacillus were all negative. One week later, the left parietal lobe hematoma began to enlarge, and disturbance of consciousness and right-side paralysis appeared. This hematoma was also removed through craniotomy [Figure 1b]. One month after the second surgery, disturbance of consciousness appeared once again. Head CT revealed that the right temporal lobe hematoma had enlarged [Figure 1c], and total removal of the hematoma through craniotomy was chosen again.

The pathological findings of the left parietal lesion also indicated an abscess, but irregular lumen-like structures consisting of epithelioid cells with highly atypical nuclei and distinct nucleoli were seen in part of the lesion [Figure 4a]. Immunohistologically, epithelial markers (AE1/AE3 and CK7) were strongly positive although CK20 was negative. Therefore, the lesion was diagnosed as a metastatic brain tumor. Because the immunohistological pattern of the patient's bladder cancer 7 years before was CK7-/CK20+ and no local recurrent lesions or peripheral lymph node swellings were detected, metastasis from the bladder cancer was considered unlikely. Positron-emission tomography was performed in a search for the primary lesion, and a faint accumulation was detected in the mass of the scar due to thoracoplasty [Figure 3b]. Further examination of the second surgical specimen showed strong positivity for the vascular endothelial marker CD31 [Figure 4b] although it was negative for CD34 [Figure 4c]. The lumen-like structures were thus thought to be blood vessel lumens. Considering these abnormal immune profiles, the high MIB-1 index of approximately 30% [Figure 4d] and a clinical diagnosis of pleural angiosarcoma related to continuous posttuberculosis inflammation of the thoracoplasty site, metastatic angiosarcoma was finally diagnosed.

Whole-brain irradiation of 40 Gy and local-thoracic irradiation of 75 Gy were performed based on a definitive diagnosis of metastatic brain tumor, and chemotherapy was



chosen using paclitaxel anticancer agents. No recurrence related to the brain lesions was seen for 22 months after surgery [Figure 5a-c] although the thoracic mass lesion began to expand gradually. At 24 months after the onset of neurological symptoms, the patient died of an airway obstruction caused by an intratracheal hemorrhage.

## Discussion

Angiosarcoma can metastasize to various organs, but metastasis to the brain is very rare.<sup>[34,35]</sup> Primary pleural angiosarcoma is also rare but occurs 3600 times more frequently in patients affected by chronic tuberculous pyothorax than in those without any specific inflammatory condition.<sup>[36]</sup> Only one report, containing no brain images, has described a case of pleural angiosarcoma metastasizing to the brain.<sup>[20]</sup> Our case represents the first report with detailed images of multiple brain metastases from pleural

angiosarcoma accompanied by unusual and gradually expanding hematomas; it is also the most controlled case of metastatic brain angiosarcoma in the literature.

Metastatic brain angiosarcoma often shows a well-circumscribed mass with hypointensity on T2-weighted MRI imaging and partial enhancement by Gd. The hypointensity on T1- and T2-weighted imaging is thought to be useful in differentiating angiosarcoma from other diseases.<sup>[8,21]</sup> In our patient, all lesions were signal hypointense areas on T1-, T2-, diffusion-, and T2\*-weighted imaging, showing almost no enhancement with Gd. Although these findings agree with those of previous reports, angiosarcoma could not be diagnosed. The cerebral hematomas in our case also gradually and sequentially expanded, with accompanying neurological deterioration. A history of chronic expanding intracerebral hematoma

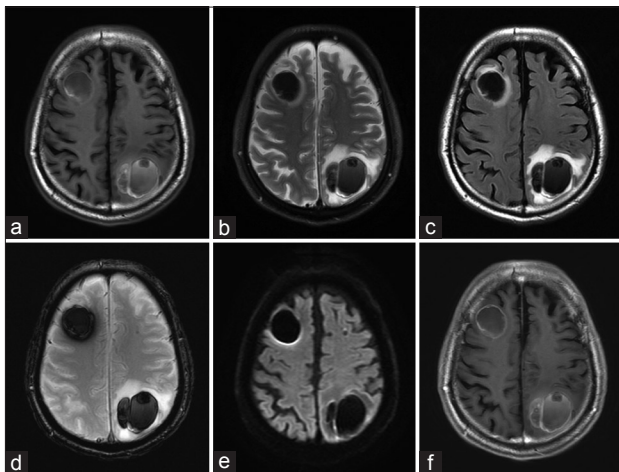


Figure 2: Magnetic resonance imaging at admission; T1-weighted image (a), T2-weighted image (b), fluid-attenuated inversion recovery image (c), T2\* image (d), diffusion-weighted image (e), gadolinium-enhanced image (f)

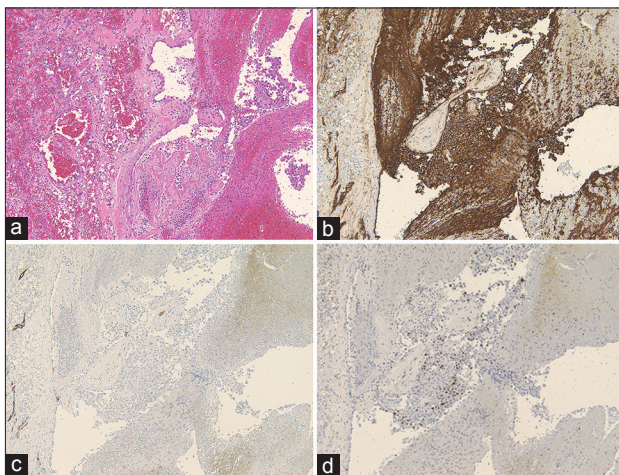


Figure 4: Hematoxylin-Eosin staining ( $\times 40$ ) shows necrotic portions, infiltration of inflammatory cells, and accumulated atypical cells, which formed an anastomosing vascular channel (a). Immunostaining by CD31 antibody shows many strong positive tumor cells (b). Immunostaining by CD34 antibody shows no positive tumor cells (c). Immunostaining by Ki-67 antibody (d) and the regional rate of positive cells was approximately 30%

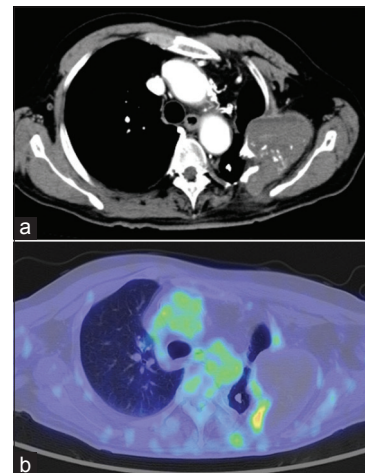


Figure 3: Postcontrast image of chest computed tomography shows fairly enhanced mass lesion arising from vestige of the old thoracoplasty (a). A fusion image of chest computed tomography and 18-F-fluorodeoxy glucose positron emission tomography (b). The image indicates fairly accumulation of 18-F-fluorodeoxy glucose at the mass lesion. Standardized uptake value maximum was 4.172

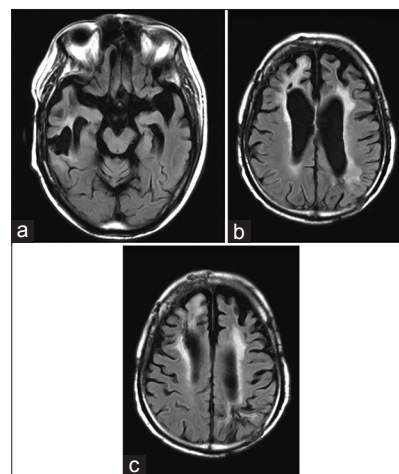


Figure 5: Fluid-attenuated inversion recovery image from magnetic resonance imaging at 22 months after onset of neurological symptoms; right temporal lesion (a), right frontal lesion (b), and left parietal lesion (c)

Table 1: Review of 34 cases of angiosarcoma metastasized to the brain

Authors	Age/sex	Primary site	Number of the brain lesion	Surgery for the brain lesion	Chemotherapy	Radiation for the brain lesion	Survival duration from the diagnosis/from neurological onset
Macaulay, 1978 <sup>[1]</sup>	18/male	Peripheral nerve	5	ND	ND	ND	2 months/-
Angrish et al., 1979 <sup>[2]</sup>	38/male	Heart (left atrium)	1	ND	ND	ND	28 months/2 months
Wasmer et al., 1981 <sup>[3]</sup>	61/male	Penis	ND	ND	DTX, CPA, methotrexate	ND	12 months/-
Seto et al., 1988 <sup>[4]</sup>	17/male	Liver	1	VP shunt (for the hydrocephalus)	ND	50 Gy (for whole brain)	15 months/-
Zhao, 1989 <sup>[5]</sup>	62/female	Uterus	ND in English	ND in English	ND in English	ND in English	25 years/-
Pötter et al., 1989 <sup>[6]</sup>	27/female	Heart (right atrium)	3	ND	VCR, DTX, CPA, prednisone, cytosine arabinoside	30 Gy (for whole brain)	15 months/-
Grollier et al., 1990 <sup>[7]</sup>	70/female	Heart (right atrium)	ND in English	ND in English	ND in English	ND in English	9 months/-
Vaquero et al., 1990 <sup>[8]</sup>	30/male	Heart (right auricle)	1	Craniotomy	ND	ND	12 months/6 months
Kuratsu et al., 1991 <sup>[9]</sup>	31/female	Femur	3	Craniotomy (for one of 3)	ND	40 Gy (for whole brain)	Alive at report
Søndenaa et al., 1993 <sup>[10]</sup>	73/female	Spleen	Multiple	ND	ND	ND	6 months/3 months
Crespo et al., 1993 <sup>[11]</sup>	31/male	Heart (right atrium)	1	Craniotomy	DTX	ND	8 months/2 months
Retmar et al., 1993 <sup>[12]</sup>	32/male	Heart (right atrium)	Multiple	ND	DTX	ND	9 months/2 months
	44/male	Heart (right atrium)	6	ND	VCR, IFM, VP16, carboplatin, actinomycin D	40 Gy (for whole brain)	11 months/2 months
Watanabe et al., 1993 <sup>[13]</sup>	30/male	Heart (right atrium)	Multiple	ND	ND	ND	5 months/20 days (diagnosed by autopsy)
Chaudhuri et al., 1994 <sup>[14]</sup>	31/female	Placenta	1	Craniotomy (total removal)	DTX	Radiotherapy (no detailed)	2 months/-
Chami et al., 1994 <sup>[15]</sup>	59/male	Small intestine	ND	ND	ND	ND	6 months/ND
Hwang et al., 1996 <sup>[16]</sup>	17/female	Heart (pericardium)	1	Craniotomy (total removal)	ND	ND	11 months/2 months
Nitta et al., 1998 <sup>[17]</sup>	50/male	Heart (right atrium)	ND	Craniotomy (total removal)	ND	ND	8 months/ND
Gallo et al., 2001 <sup>[18]</sup>	33/male	Heart (right atrium)	1	Craniotomy (total removal)	DTX, IFM, DTIC	ND	12 months/3 days
Eguchi et al., 2002 <sup>[19]</sup>	64/male	Chest wall	ND	ND	ND	ND	19 months/ND
Kimura et al., 2003 <sup>[20]</sup>	57/female	Lung (pyothorax)	2	Craniotomy	ND	ND	-/2 months
Akutsu et al., 2004 <sup>[21]</sup>	53/male	Aorta (abdominal)	1	Craniotomy (total removal)	Interleukin-2	ND	-/6 months
Liassides et al., 2004 <sup>[22]</sup>	24/female	Heart (right atrium)	2	ND	Chemotherapy (no detailed)	ND	-/6 months
Matsumoto et al., 2005 <sup>[23]</sup>	79/female	Heart (left atrium)	2	Craniotomy (for two of 2)	ND	ND	1 month/1 month

Contd...

**Table 1: Contd...**

Authors	Age/sex	Primary site	Number of the brain lesion	Surgery for the brain lesion	Chemotherapy	Radiation for the brain lesion	Survival duration from the diagnosis/from neurological onset
Ikeya <i>et al.</i> , 2006 <sup>[24]</sup>	49/male	Heart (right atrium)	1	ND	ND	ND	1 months/1 months
Plotnik <i>et al.</i> , 2008 <sup>[25]</sup>	61/female	Spleen	1	Craniotomy	Chemotherapy (no detailed)	ND	Over 5 years/-
Masih and McIlwaine, 2010 <sup>[26]</sup>	64/male	ND	2	ND	ND	ND	-/2 months
Jung <i>et al.</i> , 2012 <sup>[27]</sup>	36/male	Heart (right atrium)	2	Craniotomy (for two of 2)	Chemotherapy (no detailed)	30 Gy (for whole brain)	9 months/9 months
Mecklai <i>et al.</i> , 2014 <sup>[28]</sup>	56/female	Aorta (arch)	1	Craniotomy	ND	Gamma knife (for new lesion)	-/-
Scharl <i>et al.</i> , 2014 <sup>[29]</sup>	60/female	Aorta (arch)	Multiple	Biopsy	CDDP, VP16	30 Gy (for whole brain)	-/- (about 1 month)
Vital <i>et al.</i> , 2014 <sup>[30]</sup>	28/male	Heart (right atrium)	1	Craniotomy	DTX, PTX, IFM	ND	13 months/1.5 months
Shimabukuro, <i>et al.</i> , 2015 <sup>[31]</sup>	79/female	Pulmonary artery	Multiple	ND	ND	ND	3 months/-
Pan <i>et al.</i> , 2015 <sup>[32]</sup>	66/male	Subcutaneous (neck)	5	ND	ND	ND	1 month/-
Shimada <i>et al.</i> 2016 <sup>[33]</sup>	34/female	Heart (right atrium)	Multiple	ND	DTX, IFM	ND	14 months/2 months
Present case	74/male	Lung (pyothorax)	4	Craniotomy (for three of 4)	PTX	40 Gy (for whole brain)	24 months/24 months

ND – Not described and probably did not treat; PTX – Paclitaxel; IFM – Ifosfamide; CDDP – Cisplatin; VP16 – Etoposide; DTIC – Dacarbazine; VCR – Vincristine, CPA – Cyclophosphamide; VP shunt – Ventriculoperitoneal shunt; DTX – Docetaxel

and pulmonary tuberculosis has been used in differentiating angiosarcoma from conditions such as the progression of brain tuberculoma, but neither symptom was typical.<sup>[37,38]</sup> It was difficult to correctly diagnose the lesions based on the MRI results, and we struggled to establish a treatment plan.

Immunohistochemical examination of autopsy specimens has been performed for 98 cases diagnosed with angiosarcoma.<sup>[39]</sup> In the region of vascular formation, the proportion of markers in the cytoplasm or cell surfaces that showed diffuse positive reactions were as follows: factor VIII-related antigen (von Willebrand factor), 84%; CD31, 80%; and Ulex europaeus lectin type 1, 70%. Additional immunohistology results, such as those for CD34, cytokeratin, and vimentin, are reportedly useful in diagnosing angiosarcoma.<sup>[39]</sup> In the present case, angiosarcoma was diagnosed from the finding of strong positivity for CD31, which is thought to have a high level of specificity for vascular endothelium. Total removal of the thoracic mass that was thought to be the primary lesion would have been difficult, and no malignant findings were obtained from the biopsy specimen. However, the continued enlargement of the thoracic mass and subsequent fatal bleeding suggested that angiosarcoma also existed in parts of the lesion.

The prognosis of angiosarcoma is very poor, with a 2-year survival rate of 17% and a 5-year survival rate of 12%.<sup>[34]</sup> Even if the lesion disappears temporarily due to radiotherapy or surgical removal, recurrence or metastasis often occurs within 2 years.<sup>[9]</sup> Nearly all patients with pleural angiosarcoma developed from chronic tuberculosis pyothorax reportedly die within 1 year from onset, regardless of the presence of metastases.<sup>[36]</sup> To the best of our knowledge, 34 cases of metastatic brain angiosarcoma have been reported, half of which were metastases from the heart [Table 1].<sup>[1-33]</sup> Metastatic lesions of the brain are usually multiple at diagnosis, and differentiation from intracerebral hemorrhages<sup>[26]</sup> or cavernous angiomas<sup>[23,27]</sup> based only on radiological findings is difficult. Only two previous cases had a history of expanding hematoma in a short period as was observed in our case.<sup>[8,24]</sup> Although 11 cases survived over 1 year after diagnosis of the primary lesion, the mean survival time from the onset of neurological symptoms due to a metastatic brain lesion was approximately 2.7 months (3 days–9 months). The regulation methods for angiosarcoma include the selection of high dose (>50 Gy) and wide treatment fields for radiotherapy.<sup>[40]</sup> Doxorubicin, liposomal doxorubicin, and taxanes are reported as the most common chemotherapeutic agents for metastatic angiosarcoma.<sup>[41]</sup> Recently, weekly paclitaxel after radiotherapy has been reported as effective chemotherapy.<sup>[42,43]</sup> We selected 40 Gy whole-brain irradiation for the intracranial lesions and systemic administration of paclitaxel as adjuvant therapy, and the intracranial lesions were completely controlled through 22 months after surgery. Decompression of the intracranial lesions and complete hemostasis by surgical removal before whole-brain radiotherapy is thought to have successfully controlled the lesions.

## Conclusion

When multiple, gradually expanding, and atypical intracranial hematomas are seen, differentiation from brain metastases of angiosarcoma is necessary. Careful histopathological examination is required for definitive diagnosis. When the possibility of angiosarcoma is encountered, total removal of the lesions with complete hemostasis through craniotomy, followed by whole-brain irradiation, is important for their control.

## Financial support and sponsorship

Nil.

## Conflicts of interest

There are no conflicts of interest.

## References

1. Macaulay RA. Neurofibrosarcoma of the radial nerve in von Recklinghausen's disease with metastatic angiosarcoma. *J Neurol Neurosurg Psychiatry* 1978;41:474-8.
2. Angrish K, Manchanda SC, Shankar SK, Chopra P. Primary angiosarcoma of the heart. *Jpn Heart J* 1979;20:375-80.
3. Wasmer JM, Block NL, Politano VA, Tejada F. Penile angiosarcoma presenting in bladder. *Urology* 1981;18:179-80.
4. Seto H, Matsukado Y, Kuratsu J, Takaki S, Tomoda K. Angiosarcoma of the liver and pineal region. *No Shinkei Geka* 1988;16:409-13.
5. Zhao ZS. Primary malignant hemangioendothelioma (angiosarcoma) of the uterus – report of two cases and review of literature. *Zhonghua Zhong Liu Za Zhi* 1989;11:313-4.
6. Pötter R, Baumgart P, Greve H, Schnepfer E. Primary angiosarcoma of the heart. *Thorac Cardiovasc Surg* 1989;37:374-8.
7. Grollier G, Montécot L, Galateau F, Scanu P, Gofard M, Hédoire F, *et al.* Right-left shunt caused by sarcoma of the right atrium. *Arch Mal Coeur Vaiss* 1990;83:1007-10.
8. Vaquero J, Martínez R, Coca S, Oya S, Burgos R. Cerebral metastasis from angiosarcoma of the heart. Case report. *J Neurosurg* 1990;73:633-5.
9. Kuratsu J, Seto H, Kochi M, Itoyama Y, Uemura S, Ushio Y. Metastatic angiosarcoma of the brain. *Surg Neurol* 1991;35:305-9.
10. Søndena K, Heikkilä R, Nysted A, Søreide JA, Odegaard H, Pollard ML, *et al.* Diagnosis of brain metastases from a primary hemangiosarcoma of the spleen with magnetic resonance imaging. *Cancer* 1993;71:138-41.
11. Crespo MG, Pulpón LA, Pradas G, Serrano S, Segovia J, Vegazo I, *et al.* Heart transplantation for cardiac angiosarcoma: Should its indication be questioned? *J Heart Lung Transplant* 1993;12:527-30.
12. Rettmar K, Stierle U, Sheikhzadeh A, Diederich KW. Primary angiosarcoma of the heart. Report of a case and review of the literature. *Jpn Heart J* 1993;34:667-83.
13. Watanabe Y, Fukuda T, Araki M, Hiraki S. A case of angiosarcoma of the heart with cardiac tamponade and repeated hemoptysis. *Nihon Kyobu Shikkan Gakkai Zasshi* 1993;31:1485-8.
14. Chaudhuri KR, Jager R, Bridger J, Fusi L, Thomas DG, Frackowiak RS. Hemiplegia in pregnancy due to metastatic cerebral angiosarcoma. *Eur Neurol* 1994;34:295-7.



15. Chami TN, Ratner LE, Henneberry J, Smith DP, Hill G, Katz PO. Angiosarcoma of the small intestine: A case report and literature review. *Am J Gastroenterol* 1994;89:797-800.
16. Hwang SL, Howng SL, Sun ZM, Kwan AL. Brain metastasis from pericardial angiosarcoma. *J Formos Med Assoc* 1996;95:484-6.
17. Nitta R, Sakomura Y, Tanimoto K, Hidai T, Kasanuki H, Aomi S, *et al.* Primary cardiac angiosarcoma of the right atrium undiagnosed by transvenous endocardial tumor biopsy. *Intern Med* 1998;37:1023-6.
18. Gallo P, Dini LI, Saraiva GA, Sonda I, Isolani G. Hemorrhage in cerebral metastasis from angiosarcoma of the heart: Case report. *Arq Neuropsiquiatr* 2001;59:793-6.
19. Eguchi K, Ishi S, Sugiura H, Noga K. Angiosarcoma of the chest wall in a patient with fibrous dysplasia. *Eur J Cardiothorac Surg* 2002;22:654-5.
20. Kimura M, Ito H, Furuta T, Tsumoto T, Hayashi S. Pyothorax-associated angiosarcoma of the pleura with metastasis to the brain. *Pathol Int* 2003;53:547-51.
21. Akutsu H, Tsuboi K, Sakamoto N, Nose T, Honma S, Jikuya T. Cerebral metastasis from angiosarcoma of the aortic wall: Case report. *Surg Neurol* 2004;61:68-71.
22. Liassides C, Katsamaga M, Deretzi G, Koutsimanis V, Zacharakis G. Cerebral metastasis from heart angiosarcoma presenting as multiple hematomas. *J Neuroimaging* 2004;14:71-3.
23. Matsuno A, Nagashima T, Tajima Y, Sugano I. A diagnostic pitfall: Angiosarcoma of the brain mimicking cavernous angioma. *J Clin Neurosci* 2005;12:688-91.
24. Ikeya E, Taguchi J, Yamaguchi M, Shibuya M, Kanabuchi K. Primary cardiac angiosarcoma: Presenting with cardiac tamponade followed by cerebral hemorrhage with brain metastases. *Jpn J Thorac Cardiovasc Surg* 2006;54:528-31.
25. Plotnik AN, Schweder P, Tsui A, Kavar B. Splenic angiosarcoma metastasis to the brain. *J Clin Neurosci* 2008;15:927-9.
26. Masih I, McIlwaine W. Metastatic angiosarcoma: A vascular tumour or an intracranial haemorrhage? *BMJ Case Rep* 2010;2010. pii: Bcr1020092344.
27. Jung SH, Jung TY, Joo SP, Kim HS. Rapid clinical course of cerebral metastatic angiosarcoma from the heart. *J Korean Neurosurg Soc* 2012;51:47-50.
28. Mecklai A, Rosenzweig B, Applebaum R, Axel L, Grossi E, Chan A, *et al.* Intimal sarcoma in the aortic arch partially obstructing the aorta with metastasis to the brain. *Tex Heart Inst J* 2014;41:433-6.
29. Scharl M, Bode B, Rushing E, Knuth A, Rordorf T. Uncommon case of brain metastasis in a patient with a history of heavy smoking. *Curr Oncol* 2014;21:e728-31.
30. Vital RB, Hamamoto Filho PT, Lima Neto NM, Caldeira Xavier JC, Santos DC, Romero FR, *et al.* Brain metastasis from cardiac angiosarcoma. *Neurol India* 2014;62:451-2.
31. Shimabukuro I, Yatera K, Noguchi S, Kawanami Y, Iwanami T, Nishida C, *et al.* Primary pulmonary angiosarcoma presenting with hemoptysis and ground-glass opacity: A case report and literature review. *Tohoku J Exp Med* 2015;237:273-8.
32. Pan Z, An Z, Li Y, Zhou J. Diffuse alveolar hemorrhage due to metastatic angiosarcoma of the lung: A case report. *Oncol Lett* 2015;10:3853-5.
33. Shimada N, Shiomi D, Kaki N, Kiyama H. Primary cardiac angiosarcoma with superior vena cava syndrome. *Kyobu Geka* 2016;69:370-3.
34. Naka N, Ohsawa M, Tomita Y, Kanno H, Uchida A, Aozasa K. Angiosarcoma in Japan. A review of 99 cases. *Cancer* 1995;75:989-96.
35. Shweikeh F, Bukavina L, Saeed K, Sarkis R, Suneja A, Sweiss F, *et al.* Brain metastasis in bone and soft tissue cancers: A review of incidence, interventions, and outcomes. *Sarcoma* 2014;2014:475175.
36. Aozasa K, Naka N, Tomita Y, Ohsawa M, Kanno H, Uchida A, *et al.* Angiosarcoma developing from chronic pyothorax. *Mod Pathol* 1994;7:906-11.
37. Chakraborti S, Mahadevan A, Govindan A, Nagarathna S, Santosh V, Yasha TC, *et al.* Clinicopathological study of tuberculous brain abscess. *Pathol Res Pract* 2009;205:815-22.
38. Yamamoto S, Momose T, Aoyagi M, Ohno K. Spontaneous intracerebral hematomas expanding during the early stages of hemorrhage without rebleeding. Report of three cases. *J Neurosurg* 2002;97:455-60.
39. Ohsawa M, Naka N, Tomita Y, Kawamori D, Kanno H, Aozasa K. Use of immunohistochemical procedures in diagnosing angiosarcoma. Evaluation of 98 cases. *Cancer* 1995;75:2867-74.
40. Young RJ, Brown NJ, Reed MW, Hughes D, Woll PJ. Angiosarcoma. *Lancet Oncol* 2010;11:983-91.
41. D'Angelo SP, Munhoz RR, Kuk D, Landa J, Hartley EW, Bonafede M, *et al.* Outcomes of systemic therapy for patients with metastatic angiosarcoma. *Oncology* 2015;89:205-14.
42. Penel N, Bui BN, Bay JO, Cupissol D, Ray-Coquard I, Piperno-Neumann S, *et al.* Phase II trial of weekly paclitaxel for unresectable angiosarcoma: The ANGIOTAX study. *J Clin Oncol* 2008;26:5269-74.
43. Penel N, Italiano A, Ray-Coquard I, Chaigneau L, Delcambre C, Robin YM, *et al.* Metastatic angiosarcomas: Doxorubicin-based regimens, weekly paclitaxel and metastasectomy significantly improve the outcome. *Ann Oncol* 2012;23:517-23.