

Parietal Arteriovenous Malformation Mimicking Carotid-cavernous Fistula in Context of Sinus Thrombosis: Bidirectional or Unidirectional Relationship? Literature Review

Abstract

Cortically located arteriovenous malformations (AVMs) constitute majority of brain AVMs. A common drainage is through respective cortical veins into superior sagittal or transverse sinuses. Through a case report and literature review, we discuss three issues: first, the anomalous drainage of a cortical AVM into an anterior orbital venous drainage system; second, the impact of this drainage on the clinical picture; and third, importantly, the bidirectional versus unidirectional relationship of AVM and old venous sinus thrombosis.

Keywords: Arteriovenous malformations, carotid-cavernous fistula, ophthalmic vein, orbital venous drainage, venous sinus thrombosis

**Waseem Aziz,
Mohammed Abdel
Hady¹,
Hadeel Awad
Shihan²**

Departments of Neurosurgery and ¹Neurology and Psychiatry, Alexandria University, Alexandria, Egypt, ²Qasmi Hospital, UAE

Introduction

Brain arteriovenous malformations (AVMs) occur in about 0.1% of the population.^[1] They constitute the majority of AVM. Commonly, the ultimate venous drainage in most cases is into one of the three major venous sinuses of the brain, namely the superior sagittal, transverse, and the internal cerebral vein.^[2] The scientific literature contains rare case reports of parietal AVM with orbital venous drainage. We report an orbitally drained parietal AVM presenting with proptosis (similar to carotid-cavernous fistula) in the context of the past history of pseudotumor cerebri secondary to transverse sinus thrombosis, postulating a bidirectional etiologic relationship.

Case Report

We report a 44-year-old female who presented with a 3 months' history of the right eye proptosis associated with a progressive visual decline. She previously sought medical advice for a painless nonproptotic bilateral visual impairment over 7 years. She reported associated chronic headache, with no associated motor, sensory, visceral, or bulbar complaints.

The patients' records (during the 7 years) were notable for visual field defect. Her previous fundus examination showed bilateral optic atrophy, more on the right side, while the perimetry showed a contraction of peripheral visual field [Figure 1]. Otherwise, her neurologic examination was reported to be unremarkable. Brain imaging at that time revealed normal computed tomography (CT) examination, on which lumbar puncture was performed, which showed an opening pressure of 40 mm H₂O with normal physical, chemical, and microscopic analyses. Conservative treatment with repeated lumbar puncture and carbonic anhydrase inhibitors were instituted, on which she showed partial improvement over time with stabilization of visual field loss.

The examination (for the current presentation: proptosis) revealed episcleral and conjunctival injection, yet without ophthalmoplegia, visibly pulsating globe, or diplopia [Figures 2 and 3]. Again, her motor, cortical, and sensory examinations were unremarkable.

Based on the previous findings, CT and magnetic resonance imaging were requested. Both showed a right parietal AVM with prominent superior ophthalmic

Address for correspondence:
Dr. Waseem Aziz,
Department of Neurosurgery,
Alexandria University,
Alexandria, Egypt.
E-mail: wasim.aziz@alexmed.
edu.eg

Access this article online

Website: www.asianjns.org

DOI: 10.4103/ajns.AJNS_249_17

Quick Response Code:



How to cite this article: Aziz W, Hady MA, Shihan HA. Parietal arteriovenous malformation mimicking carotid-cavernous fistula in context of sinus thrombosis: Bidirectional or unidirectional relationship? Literature review. Asian J Neurosurg 2020;15:458-61.

Submitted: 07-Sep-2019 **Accepted:** 29-Sep-2019
Published: 07-Apr-2020

This is an open access journal, and articles are distributed under the terms of the Creative Commons Attribution-NonCommercial-ShareAlike 4.0 License, which allows others to remix, tweak, and build upon the work non-commercially, as long as appropriate credit is given and the new creations are licensed under the identical terms.

For reprints contact: reprints@medknow.com




Figure 1: Demonstration of the contracted visual field after the diagnosis of pseudotumor cerebri




Figure 3: Demonstration of the current visual field defect

vein [Figure 4], so a six-vessel diagnostic subtraction angiography was performed [Figure 5].

Diagnostic angiography revealed a left parieto-occipital AVM with its feeders from inferior middle cerebral artery division (notably, posterior parietal and angular arteries), and a drainage system of superficial cortical veins (having venous varix) draining into superior sagittal sinus, which, in turn, drains to basal vein of Rosenthal, ultimately draining into superior ophthalmic vein, with nonvisualization of both transverse sinuses nor sigmoid ones.

Therapeutic injection with Onyx liquid embolic system (ev3, Irvine, California, USA) was performed over two sessions, which showed a complete obliteration [Figure 6].

Follow-up postoperatively, 1 and 6 months later, revealed the resolution of her exophthalmos, with a steady visual acuity.

Discussion

Although this case apparently represents a common type of AVM regarding the location and the feeding system^[3-5]

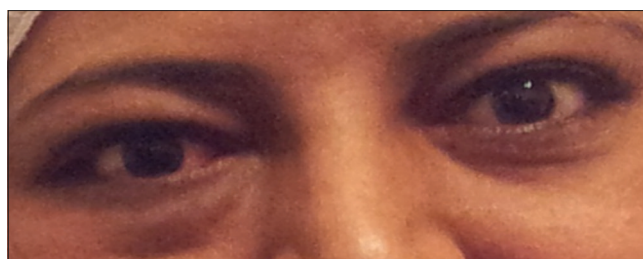


Figure 2: Demonstration of the episcleral and conjunctival injection

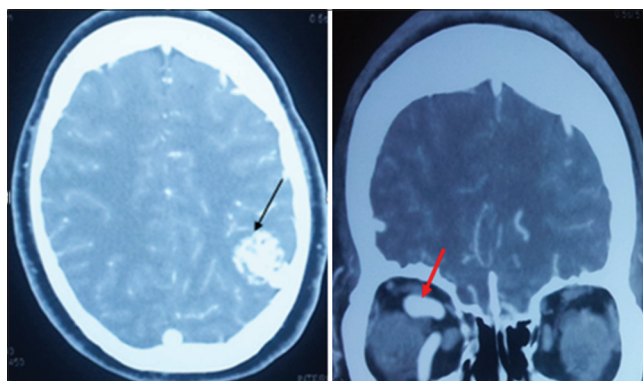


Figure 4: Demonstration of the left parieto-occipital arteriovenous malformations (black arrow) and drainage in the superior ophthalmic vein (red arrow)

(sulcal AVM supplied by cortical feeders according to Valvanis),^[6] yet this is not the case in different aspects:

First, the venous drainage of our case is through the superior sagittal-ophthalmic pathway into internal jugular vein, in contrast to the expected drainage through superior sinus-transverse sinus-sigmoid sinus pathway. The orbital drainage of posteriorly located AVM is a matter of rarity, being described only in case reports.^[7-12]

Accordingly, this aberrant venous drainage has led to atypical clinical presentation with proptosis mimicking carotid-cavernous fistula. This was described in the previous case reports of similar drainage pathway, with different presentations ranging from anterior visual pathway compression, visual field defects^[10,11] to oculomotor nerve palsies and raised intracranial pressure.^[12] A noteworthy point is the clinical differentiation of this aberrant presentation from carotid-cavernous fistula, with the lack of classic pulsating proptosis, ophthalmoplegia, and diplopia in our case.^[12]

Finally, the past history of pseudotumor cerebri together with nonvisualization of both transverse sinuses on digital subtraction angiography raises the possibility of transverse sinus thrombosis as an overlooked cause of increased intracranial pressure. Furthermore, the thrombosis explains the rerouting of parietal AVM through anterior pathway instead of the transverse-sigmoid one, as evidenced in the figure below.

The bidirectional relationship between AVM and sinus thrombosis is a matter of consistent debate, with abundant

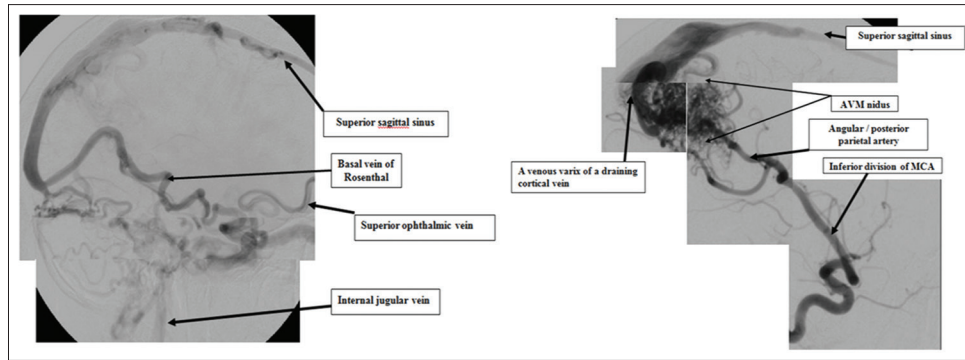


Figure 5: Demonstration of the angiographic picture of the left parieto-occipital arteriovenous malformations with its feeders from inferior middle cerebral artery division (notably posterior parietal and angular arteries), draining into superior sagittal sinus, (with a venous varix) followed by basal vein of Rosenthal, ending into superior ophthalmic vein, with nonvisualization of both transverse and sigmoid sinuses

literature favoring the AVM-related thrombosis,^[13-18] in contrast to the limited data concerning thrombosis-induced AVM.^[19,20] In our point of view, this can be demonstrated in the following mechanisms [Figure 7].

Spontaneous arteriovenous malformations-induced thrombosis

Several case reports address the spontaneous regression of AVM through postulated thrombosis of unclear mechanism, whether intracranial^[13] or spinal,^[14] even the following hemorrhage. In these cases, AVM was observed, followed for a period, then it regressed, and they came to the understanding that thrombosis happened as a result of the AVM and led to the subsequent regression of the AVM. Increased incidence of seizures related to this course was hypothesized by postthrombotic transient edema.^[13] Vascular endothelial growth factor (VEGF) and its receptors, Flt-1 and Flk, were demonstrated within the vascular endothelium and the subendothelial layers, raising the possibility of active thrombosis.^[14] Another possibility is the coexistence of intrinsic hypercoagulable state, such as prothrombin gene mutation.^[15]

Iatrogenic arteriovenous malformation-induced thrombosis

There are individual case reports of thrombosed AVM with resultant regression, or thrombosed draining vein with resultant hemorrhage, both temporally related to different neurointerventional procedures from angiography^[16] to radiosurgery.^[17-19] Some postulate the preexistence of venous stenosis as predisposing substrate.^[16]

Thrombosis-induced arteriovenous malformation

There are different reports of AVM related to the previous history of dural sinus thrombosis^[20,21] or moyamoya disease^[22] although more reported to develop dural rather than pial-based AVM.^[18,19] Ischemic state is the common pathway and supposed to act through angiogenic mechanisms, through increased expression of VEGF receptors on endothelial cells.^[20,21]

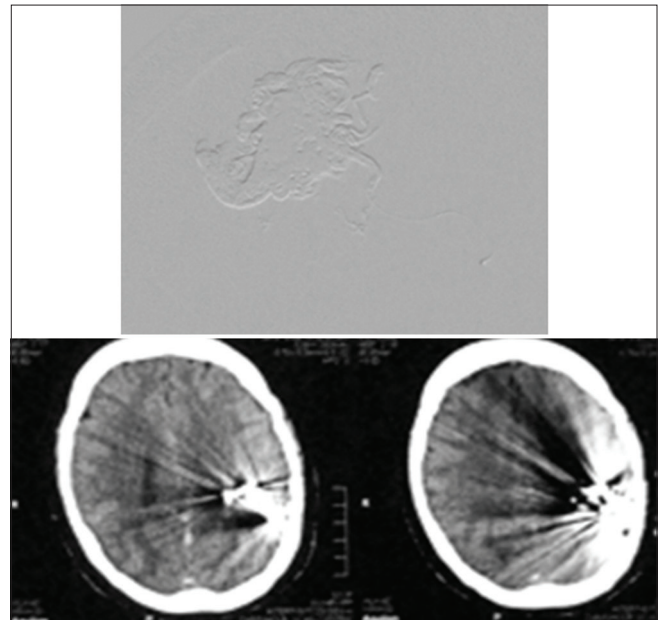


Figure 6: Demonstration of Onyx cast and follow-up computed tomography brain showing complete obliteration

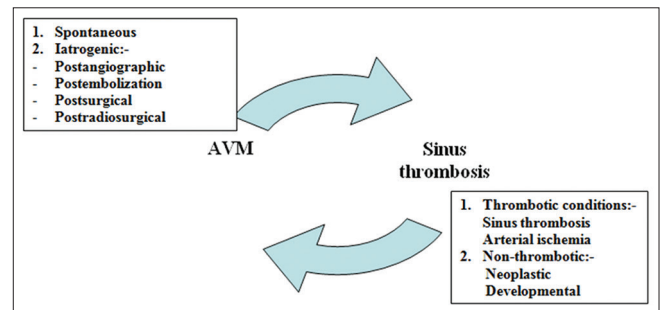


Figure 7: The proposed bidirectional relation between arteriovenous malformations and thrombosis

Nonthrombotic conditions related to acquired arteriovenous malformation

Discrete reports relate *de novo* appearance of AVM following neoplastic conditions (such as resection of

pilocytic astrocytoma)^[23] or on a spontaneous basis.^[24] Again, increased the expression of angiogenic mediators or undetected thrombophilia (such as protein S deficiency)^[23] are common postulated mechanisms.

Conclusion

This case though initially simple-looking conveys the symptomatic differentiation of carotid-cavernous fistula versus orbitally drained AVM. Furthermore, it stirs up the etiologic issue of sinus thrombosis, which raises the need for revising the truth of the bidirectional versus unidirectional relationship of AVM and thrombosis.

Declaration of patient consent

The authors certify that they have obtained all appropriate patient consent forms. In the form the patient(s) has/have given his/her/their consent for his/her/their images and other clinical information to be reported in the journal. The patients understand that their names and initials will not be published and due efforts will be made to conceal their identity, but anonymity cannot be guaranteed.

Financial support and sponsorship

Nil.

Conflicts of interest

There are no conflicts of interest.

References

- Mohr JP, Keaja-Scharler J, Pile-Spellman J. Diagnosis and treatment of arteriovenous malformations. *Curr Neurol Neurosci Rep* 2013;13:324.
- Casikar V, Ramaswamy GS, Bhagat M. The developmental anatomy and fluid dynamics of cerebral AVMs. *Ann Vasc Med Res* 2017; 4:1052.
- Al-Shahi R, Fang JS, Lewis SC, Warlow CP. Prevalence of adults with brain arteriovenous malformations: A community based study in Scotland using capture-recapture analysis. *J Neurol Neurosurg Psychiatry* 2002;73:547-51.
- Suzuki H, Maki H, Taki W. Evaluation of cerebral arteriovenous malformations using image fusion combining three-dimensional digital subtraction angiography with magnetic resonance imaging. *Turk Neurosurg* 2012;22:341-5.
- Stapf C, Mast H, Sciacca RR, Berenstein A, Nelson PK, Gobin YP. The New York Islands AVM study: Prospective population-based detection rates for brain AVM and incident AVM hemorrhage. *Stroke* 2002;33:396.
- Valavanis A. The role of angiography in the evaluation of cerebral vascular malformations. *Neuroimaging Clin N Am* 1996;6:679-704.
- Gregory ME, Berry-Brincat A, Ghosh YK, Syed RN, Diaz PL, Jordan TL. An arteriovenous malformation masquerading as a carotid-cavernous sinus fistula. *Am J Ophthalmol* 2005;140:548-50.
- Squirell D, Puri P, Rundle PA, Romanowski C, Rennie IG. Anomalous venous drainage of a plexiform (pial) arteriovenous malformation mimicking an indirect carotid-cavernous sinus fistula. *Br J Ophthalmol* 2002;86:702-4.
- Buchanan TA, Harper DG, Hoyt WF. Bilateral proptosis, dilatation of conjunctival veins, and papilloedema: A neuro-ophthalmological syndrome caused by arteriovenous malformation of the torcular herophili. *Br J Ophthalmol* 1982;66:186-9.
- Volpe NJ, Sharma MC, Galetta SL, Langer DJ, Liu GT, Hurst RW, et al. Orbital drainage from cerebral arteriovenous malformations. *Neurosurgery* 2000;46:820-4.
- Newton TH, Weidner W, Greitz T. Dural arteriovenous malformation in the posterior fossa. *Radiology* 1968;90:27-35.
- Moster MR, Kennerdell JS. B-scan ultrasonic evaluation of a dilated superior ophthalmic vein in orbital and retro-orbital arteriovenous anomalies. *J Clin Neuroophthalmol* 1983;3:105-8.
- Krapf H, Siekmann R, Freudenstein D, Küker W, Skalej M. Spontaneous occlusion of a cerebral arteriovenous malformation: Angiography and MR imaging follow-up and review of the literature. *AJNR Am J Neuroradiol* 2001;22:1556-60.
- Chun JY, Gulati M, Halbach V, Lawton MT. Thrombosis of a spinal arteriovenous malformation after hemorrhage: Case report. *Surg Neurol* 2004;61:92-4.
- Taha M, Patel U, Wharton SB, Cooper PC, Makris M. Fatal spontaneous thrombosis of a cerebral arteriovenous malformation in a young patient with a rare heterozygous prothrombin gene mutation. Case report. *J Neurosurg* 2007;106:143-6.
- Gupta V, Rizvi T, Garg A, Gaikwad SB, Mishra NK. Postangiographic thrombosis of a spinal arteriovenous malformation: Case report. *J Neurosurg Spine* 2005;2:486-90.
- Bendok BR, Getch CC, Ali MJ, Parish T, Batjer HH. Spontaneous thrombosis of a residual arteriovenous malformation in eloquent cortex after surgery: Case report. *Neurosurgery* 2002;50:1142-5.
- Celix JM, Douglas JG, Haynor D, Goodkin R. Thrombosis and hemorrhage in the acute period following gamma knife surgery for arteriovenous malformation. Case report. *J Neurosurg* 2009;111:124-31.
- Shimizu S, Irikura K, Miyasaka Y, Mochizuki T, Kurata A, Kan S, Fujii K. Rupture of pial arteriovenous malformation associated with early thrombosis of the draining system following stereotactic radiosurgery: Case report. *Neurol Med Chir* 2001;41:599-602.
- Ozawa T, Miyasaka Y, Tanaka R, Kurata A, Fujii K. Dural-pial arteriovenous malformation after sinus thrombosis. *Stroke* 1998;29:1721-4.
- Phatouros CC, Halbach VV, Dowd CF, Lempert TE, Malek AM, Meyers PM. Acquired pial arteriovenous fistula following cerebral vein thrombosis. *Stroke* 1999;30:2487-90.
- Fujimoto K, Iida J, Kawaguchi S, Sakaki T, Nakagawa H, Kichikawa K, et al. A case of arteriovenous malformation associated with moyamoya phenomenon. *Surg Neurol* 2004;32:291-5.
- Yassari R, Jahromi B, Macdonald R. Dural arteriovenous fistula after craniotomy for pilocytic astrocytoma in a patient with protein S deficiency. *Surg Neurol* 2002;58:59-64.
- Stevens J, Leach JL, Abruzzo T, Jones BV. *De novo* cerebral arteriovenous malformation: Case report and literature review. *AJNR Am J Neuroradiol* 2009;30:111-2.