

A Novel Technique for Mitigation of the Ledge Effect Caused by the Use of a Large-Lumen Catheter during Neurointervention: Beanstalk Method

Abstract

Navigating a large-caliber catheter into the intracranial artery may generate a “ledge effect,” which disturbs successful neurointervention. Particularly, navigation of a large-lumen aspiration catheter is often required to achieve fast recanalization in acute ischemic stroke cases. Occasionally, the aspirator cannot be passed through the ophthalmic artery origin because of the ledge effect. Here, we report a new technique for mitigation of the ledge effect that involves the use of double micro-guidewires (MGWs). We refer to this technique as the “beanstalk method.” We evaluated the efficacy of our idea using a silicon vascular model. Two 0.014” MGWs are used for navigation of a 0.068” aspirator. After one guidewire is navigated to the distal portion, another MGW is advanced along with the former guidewire, in a spiral fashion, similar to the growth of a beanstalk. The aspirator can then pass with the coaxial double-guidewire, although there is a severe gap in the vessel. We performed an *in vitro* study to demonstrate the effectiveness of the beanstalk method. The beanstalk method was very useful, even under challenging conditions that did not allow for passage of a conventional coaxial catheter or buddy-wire. The beanstalk method effectively decreases the ledge effect because of the shape of the two wires just ahead of the catheter, which contrasts with the hardness of the spiral wires. In cases involving challenging vasculature, the beanstalk method achieves smoother catheter navigation than the conventional coaxial method or buddy-wire technique.

Keywords: Beanstalk method, catheter, ledge effect, neurointervention

Introduction

The ledge effect is one of the most important barriers to successful endovascular treatment. A large-caliber aspirator is often used to perform endovascular thrombectomy for the treatment of acute ischemic stroke.^[1,2] When navigating the aspirator through the carotid siphon, the ledge effect is often encountered at the origin of the ophthalmic artery. The gold standard technique for mitigating the ledge effect is reduction of the gap between the aspirator and the inner catheter; however, this approach is not effective in some challenging cases. We performed an *in vitro* study to find an alternative to mitigate the ledge effect. Here, we report a new technique called the “beanstalk method,” which allows for safe navigation of a large-caliber catheter through a model of challenging vasculature, and discuss the utility of this approach.

This is an open access journal, and articles are distributed under the terms of the Creative Commons Attribution-NonCommercial-ShareAlike 4.0 License, which allows others to remix, tweak, and build upon the work non-commercially, as long as appropriate credit is given and the new creations are licensed under the identical terms.

For reprints contact: WKHLRPMedknow_reprints@wolterskluwer.com

Materials and Methods

In this study, we used the 5MAX™ ACE68™ reperfusion catheter (Penumbra Inc., Alameda, CA, USA) as the large-lumen catheter. A silicon vascular model with a notch in the middle of the curvature was used [Figure 1a]. In the model, the ACE68 catheter never passed through the notch, even when using a coaxial 3MAX catheter (Penumbra Inc.) [Figure 1b and c].

Beanstalk method

Two 0.014” micro-guidewires (MGWs) (Chikai 14 MGW: Asahi Intecc, Aichi, Japan) are used for navigation of the ACE68 catheter. After one MGW is navigated to the distal portion, another MGW, with a modified pigtail-shaped tip [Figure 2a], is advanced along with the original MGW spirally, similar to the growth of a beanstalk. A schematic drawing is shown in Figure 2b. Then, the ACE68 catheter is advanced with the coaxial double

How to cite this article: Ohshima T, Miyachi S. A novel technique for mitigation of the ledge effect caused by the use of a large-lumen catheter during neurointervention: Beanstalk method. *Asian J Neurosurg* 2020;15:753-5.

Submitted: 18-May-2020

Revised: 14-Jun-2020

Accepted: 25-Jun-2020

Published: 28-Aug-2020

Tomotaka Ohshima¹, Shigeru Miyachi^{1,2}

¹Neuroendovascular Therapy Center, Aichi Medical University, ²Department of Neurosurgery, Aichi Medical University, Nagakute, Aichi, Japan

Address for correspondence:

Dr. Tomotaka Ohshima, Neuroendovascular Therapy Center, Aichi Medical University, 1-1 Yazakokarimatoa, Nagakute, Aichi 480-1195, Japan. E-mail: tmtkoh@gmail.com

Access this article online

Website: www.asianjns.org

DOI: 10.4103/ajns.AJNS_238_20

Quick Response Code:



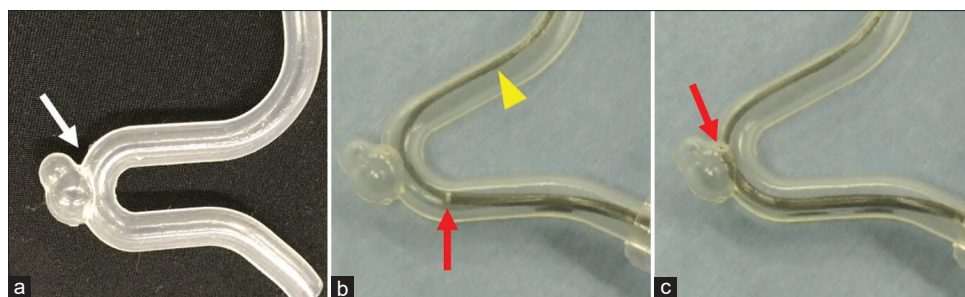


Figure 1: (a) Photograph of a silicon vascular model with a notch in the middle of the curvature (arrow). (b and c) The red arrows indicate the tip of the 5MAX ACE68 reperfusion catheter (Penumbra Inc., Alameda, CA, USA). The yellow arrowhead indicates the coaxial 3MAX catheter (Penumbra Inc.). The ACE68 catheter never passed beyond the notch because of the ledge effect

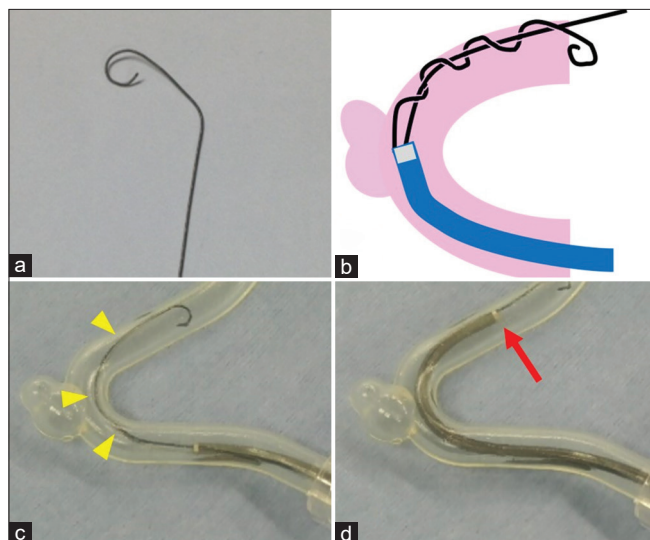


Figure 2: (a) Photograph of a 0.014'' microguidewire formed into a modified pigtail shape. (b) Schematic drawing of the beantstalk method. After one guidewire is navigated to the distal portion, another is advanced along the first, in a spiral fashion. (c and d) The yellow arrowheads indicate twined wire surrounding the other wire. The red arrows indicate the tip of the ACE68, which was advanced easily, without any resistance caused by the ledge effect

MGW. We performed an *in vitro* study to investigate the mechanism that allowed for the success of this beantstalk method.

Results

When the two MGWs were navigated in a simple parallel fashion, the ACE68 catheter could not follow the MGWs. However, navigation of the second MGW added torque to the MGW; the tip was twisted (3–5 times) around the former wire [Figure 2c]. The ACE68 catheter could then be advanced easily [Figure 2d].

We thought that the effect of the beantstalk method reflected increased support from the harder MGWs, compared with the parallel double MGW. Therefore, we compared hardness using a 1-g addition at each tip. There was no apparent difference in flexibility between the parallel and spiral MGWs [Figure 3]. The results obtained did not confirm our hypothesis.

Next, we investigated the shapes of the two MGWs at the tip of the ACE68 catheter. When using parallel MGWs, the outer edge of the ACE68 was independent of the MGWs [Figure 4a and b]. However, when using the beantstalk method, one of the MGWs could be traced to the outer edge of the ACE68 catheter [Figure 4c and d]. We concluded that the beantstalk method could reduce the ledge effect because there was less gap between the catheter and MGWs at the outer side with the use of the beantstalk method, compared with the use of the parallel double MGW.

Discussion

We found that the severe ledge effect caused by the use of a large-caliber catheter could be mitigated by the use of a spiral double MGW. The ledge effect is one of the most important barriers to successful endovascular treatment. Large-caliber aspirators are often used to perform endovascular thrombectomy as treatment for acute ischemic stroke. The aspirator may be used alone or in combination with the stent retriever.^[1,2]

The ledge effect is often encountered at the origin of the ophthalmic artery when navigating the aspirator through the carotid siphon. Reduction of the gap between the aspirator and the inner catheter is considered the first-line approach to mitigating the ledge effect. However, this approach is not effective in some challenging cases. Although the stent retrieving into an aspiration catheter with proximal balloon technique^[2] allows for the use of a stent retriever deployed in the distal portion as a strong anchor during navigation of the aspirator, this approach may not be effective in patients with a challenging vasculature.

Some authors have reported on the effectiveness of a buddy-wire technique in reducing the ledge effect.^[3,4] Muraoka *et al.*^[4] reported that the ledge effect associated with the use of a microcatheter with a lumen of 0.027'' was mitigated by the use of 0.014'' and 0.010'' MGWs. The authors concluded that it was important to fill the inner lumen of the catheter to the extent possible using two MGWs to reduce the ledge effect. Although thick guidewires are generally required to fill the lumen of a large-caliber aspirator, the particular anatomy of the case




Figure 3: (a and b) Photograph depicting the *in vitro* study. The white arrowheads indicate a 1-g weight. The black arrow indicates the parallel double-wires. The red arrow showing spiral double-wires. In contrast to our expectations, there was no apparent difference in flexibility between the parallel and spiral wires

presented here prevents the navigation of thick wires into the intracranial artery. We, therefore, elected to use thin, soft MGWs.

The use of parallel MGWs was not effective for navigation of the aspirator. We next tried to navigate the aspirator with spiral MGWs. When this “sheep technique”^[5] failed, we had already used the spiral wires, in a fashion similar to the growth of a beanstalk, to follow the guidewire. We used an MGW with a modified pigtail shape to achieve this spiral pattern.^[6,7] The results obtained show that the beanstalk method may be effective for decreasing the ledge effect. The gap between the catheter and the MGW traveling along the exterior of a tortuous vessel decreased in size with the use of this novel technique, compared with the use of a parallel double MGW. This technique did not require the use of thick, hard guidewires in order to fill the catheter lumen. We recommend the navigation of two microwires one after another. If the two wires are advanced into the large-caliber catheter simultaneously, they might be broken due to negotiations.

This study had some limitations. First, the creation of the modified pigtail wire required a specific skill set. It is difficult to create a small-diameter tip. Second, the use of two MGWs results in high cost, which may not be covered by a medical insurance. Third, the use of MGWs in an excessively spiral fashion may damage intracranial arteries. Studies involving larger number of experiments and cases are necessary to confirm the efficacy of the beanstalk method.

In cases with a challenging vasculature, the beanstalk method is associated with smoother navigation of large-caliber catheters than the conventional coaxial method or the buddy-wire technique.

Financial support and sponsorship

Nil.




Figure 4: Photograph of *in vitro* experiments. (a and b) When using parallel wires, the outer edge of the ACE68 was independent of the wires (black arrow). (c and d) When using the beanstalk method, one of the wires can be traced at the outer edge of the ACE68 catheter (red arrow)

Conflicts of interest

There are no conflicts of interest.

References

1. Turk AS, Frei D, Fiorella D, Mocco J, Baxter B, Siddiqui A, *et al.* ADAPT FAST study: A direct aspiration first pass technique for acute stroke thrombectomy. *J Neurointerv Surg* 2014;6:260-4.
2. Goto S, Ohshima T, Ishikawa K, Yamamoto T, Shimato S, Nishizawa T, *et al.* A stent-retrieving into an aspiration catheter with proximal balloon (ASAP) technique: A technique of mechanical thrombectomy. *World Neurosurg* 2018;109:e468-75.
3. Kizilkilic O. Vertebral artery origin stenting with buddy wire technique in tortuous subclavian artery. *Eur J Radiol* 2007;61:120-3.
4. Muraoka K, Kuwahara K, Okuma Y, Tanabe T, Terada K, Meguro T, *et al.* Successful mitigation of the ledge effect of the Excelsior XT-27 Flex using a double-wire technique: Technical note. *J Neuroendovasc Ther* 2014;8:166-71.
5. Chapot R, Nordmeyer H, Heddier M, Velasco A, Schooss P, Stauder M, *et al.* The sheeping technique or how to avoid exchange maneuvers. *Neuroradiology* 2013;55:989-92.
6. Sato M, Ohshima T, Ishikawa K, Goto S, Yamamoto T, Izumi T, *et al.* A novel technique of safe and versatile microguidewire shaping with neuroendovascular therapy: Modified pigtail method. *J Neuroendovasc Ther* 2017;11:266-71.
7. Ohshima T, Shamim Ul Haq Siddiqi, Miyachi S, Matsuo N, Kawaguchi R, Kato Y, *et al.* Usefulness of modified pigtail-shaped microguidewire guidance for microcatheter navigation in difficult vasculatures during neuroendovascular interventions. *Nagoya J Med Sci* 2018;80:551-7.