

# Efficacy of Computed Tomography Perfusion – Alberta Stroke Program Early Computed Tomography Score for Identifying Patients with Anterior Circulation Acute Ischemic Stroke that Would Benefit from Endovascular Treatment

## Abstract

**Background:** The identification of criteria that improves the selection of ischemic stroke patients most suitable for mechanical thrombectomy (MT) will improve clinical outcomes. The aim of this study was to identify the computed tomography (CT) imaging parameter that best predicts patients who will benefit from endovascular treatment among patients with anterior circulation ischemic stroke. **Materials and Methods:** This retrospective study was conducted in patients with acute middle cerebral artery (MCA) stroke with/without internal carotid artery occlusion who underwent successful MT at Siriraj Hospital from November 2009 to October 2016. Evaluated parameters were compared between those with and without a favorable outcome. **Results:** Forty-four consecutive patients with acute MCA occlusion were included, and 61.4% had unfavorable clinical outcome. Regarding CT perfusion – Alberta stroke program early CT score (CTP-ASPECTS) at the 50% cut point, patients with favorable outcome had higher Cerebral blood volume-ASPECTS (CBV-ASPECTS) and mean transit time-ASPECTS (MTT-ASPECTS) than those with unfavorable outcome. For CTP-ASPECTS at the 75% cut point, patients with favorable outcome had higher CBV-ASPECTS, cerebral blood flow-ASPECTS, and MTT-ASPECTS than those with unfavorable outcome. **Conclusions:** CTP-ASPECTS at the 50% and 75% cut points of abnormality could not predict the clinical outcome of anterior ischemic stroke after thrombectomy. Of the ASPECTS evaluated in this study, MTT-ASPECTS at the 75% cut point was the most predictive parameter. Older age was associated with unfavorable outcome after thrombectomy.

**Keywords:** Anterior circulation acute ischemic stroke, computed tomography perfusion-Alberta stroke program early computed tomography score, efficacy, endovascular treatment, Thailand

## Introduction

Radiologists and neurointerventionists have not yet conclusively identified the imaging parameter or combination of imaging parameters that best assess parenchymal changes, and that predict favorable clinical outcome after mechanical thrombectomy (MT) in patients with anterior circulation ischemic stroke.

The area or quantity of brain ischemia or infarction is an important factor when attempting to predict clinical outcome in this patient population. The common imaging parameter for assessing brain parenchyma involvement is the Alberta Stroke Program Early Computed Tomography (CT) Score (ASPECTS). Noncontrast CT (NCCT) of the brain is

the first-line diagnostic test in suspected acute stroke due to its widespread availability, fast processing time, reasonable affordability, and its ability to exclude acute hemorrhage. NCCT-ASPECTS is a widely accepted tool for guiding further treatment, and for predicting clinical outcome in patients with acute ischemic stroke with large vessel occlusion, mainly Middle cerebral artery (MCA) occlusion.<sup>[1]</sup> Hill *et al.*<sup>[2]</sup> reported a relative risk of the favorable outcome in the ASPECTS >7 group of 5.0 (95% confidence interval [CI]: 1.3–19.2), compared with 1.0 (95% CI: 0.6–1.9) in the ASPECTS ≤7 group.

CT perfusion (CTP)-ASPECTS is a new imaging parameter that has been investigated for its ability to predict the

**Dittapong  
Songsaeng,  
Thewaporn  
Khamduang,  
Thipthara  
Tarathipayakul,  
Chulaluck Boonma,  
Timo Krings<sup>1</sup>**

*Division of Diagnostic Radiology, Department of Radiology, Faculty of Medicine Siriraj Hospital, Mahidol University, Bangkok, Thailand, <sup>1</sup>Division of Neuroradiology, Department of Medical Imaging, Faculty of Medicine, University of Toronto, Canada*

## Address for correspondence:

*Dr. Dittapong Songsaeng,  
Department of Radiology,  
Division of Diagnostic  
Radiology, Faculty of Medicine,  
Siriraj Hospital, Mahidol  
University, 2 Wanglang Road,  
Bangkoknoi, Bangkok 10700,  
Thailand.*

*E-mail: dsongsaeng@gmail.com*

## Access this article online

**Website:** [www.asianjns.org](http://www.asianjns.org)

**DOI:** 10.4103/ajns.AJNS\_237\_18

## Quick Response Code:



**How to cite this article:** Songsaeng D, Khamduang T, Tarathipayakul T, Boonma C, Krings T. Efficacy of computed tomography perfusion – Alberta stroke program early computed tomography score for identifying patients with anterior circulation acute ischemic stroke that would benefit from endovascular treatment. *Asian J Neurosurg* 2019;14:785-94.

This is an open access journal, and articles are distributed under the terms of the Creative Commons Attribution-NonCommercial-ShareAlike 4.0 License, which allows others to remix, tweak, and build upon the work non-commercially, as long as appropriate credit is given and the new creations are licensed under the identical terms.

**For reprints contact:** [reprints@medknow.com](mailto:reprints@medknow.com)

area of brain ischemia/infarction and clinical outcome. Finlayson *et al.*<sup>[3]</sup> reported that total ASPECTS, when compared with NCCT brain, CT angiography (CTA) brain, and CTP brain, had very good concordance, internal consistency, and internal reliability. They also found that cerebral blood volume (CBV), which is one parameter of CTP, had the best reliability for the evaluation of ischemic brain parenchyma in all area of ASPECTS compared with NCCT brain, and in almost area of ASPECTS compared with CTA brain. Lin *et al.*<sup>[4]</sup> found the accuracy of NCCT, CTA source images, and CTP CBV for detecting regional infarct to be 80.0%, 84.3%, and 96.8%, respectively ( $P < 0.0001$ ). They found correlations between final ASPECTS and NCCT-ASPECTS, CTA-ASPECTS, and CBV-ASPECTS of  $r^2 = 0.34$ ,  $r^2 = 0.42$ , and  $r^2 = 0.91$ , respectively. Aviv *et al.*<sup>[5]</sup> reported that CBV-ASPECTS  $\geq 8$  predicted major neurologic improvement (increase in National Institutes of Health Stroke Scale [NIHSS]) to  $\geq 8$  points at 24 h after recombinant tissue plasminogen activator [rt-PA] treatment) ( $P = 0.02$ ), and predicted good clinical outcome (Modified Rankin Scale [mRS]  $\leq 2$  at 3 months after rt-PA treatment). That group also found CBV-ASPECTS and NCCT-ASPECTS to have similar radiologic correlations (0.6 and 0.5, respectively) and best-predicted infarct size in the absence of major neurologic improvement.

The identification of criteria that improves the selection of ischemic stroke patients that is most suitable for MT will improve clinical outcomes. Accordingly, the aim of this study was to identify the CT imaging parameter that best predicts the patients who will benefit from endovascular treatment among patients with anterior circulation ischemic stroke. More specifically, we set forth to identify association between CTP-assessment, the CTP-ASPECTS, with variable CTP parameters and final treatment outcome (mRS) at 3 months in patients with ischemic anterior circulation stroke who were treated with MT.

## Materials and Methods

This study involved the retrospective review of the clinical and imaging findings of 44 acute stroke patients who presented at Siriraj Hospital – Thailand's largest and oldest medical school and national tertiary referral

center – from the November 2009 to October 2016 study period. The protocol for this study was approved by the Siriraj Institutional Review Board, Faculty of Medicine Siriraj Hospital, Mahidol University, Bangkok, Thailand (COA no. Si 093/2017).

Patients with proximal MCA with/without intracranial internal carotid artery (ICA) occlusion within 6 h who underwent admission NCCT brain and CTP brain (cerebral blood flow [CBF], [CBV], mean transit time [MTT], and time to peak [TTP]) and successful MT were included. Patients with unsuccessful MT, with no mRS evaluation at 3-month post-MT, and/or that were lost to follow-up were excluded.

Both authors (DS and TK) reviewed and scored by consensus the baseline NCCT and CTP (CBF, CBV, MTT, and TTP); however, both authors were blinded to clinical information and follow-up imaging.

The baseline NCCT brain was scored using ASPECTS for early ischemic changes [Figure 1]. Four perfusion mapping techniques of CTP, included CBF, CBV, MTT, and TTP, were applied to assess ASPECTS (i.e., CBF-ASPECTS, CBV-ASPECTS, MTT-ASPECTS, and TTP-ASPECTS, respectively). Cut points of 50% and 75% abnormality that correspond to a color scale bar were used to define the ischemic/infarction area [Figure 2].

Demographic data, stroke symptom onset time (duration from the last time point, the patient was observed without stroke symptoms until the hospital arrival time), NIHSS, and 90-day mRS were collected from the patient medical chart and/or telephone interview with patients or relatives. Good clinical outcome was defined when the patients have mRS  $\leq 2$  at 3 months after MT.

## Imaging

A Discovery CT750 HD multi-section scanner (GE Healthcare, Milwaukee, WI, USA) was used to scan all included patients. The stroke fast-track protocol is described in Table 1.

CTP 4-dimension with Advantage Workstation 4.6 (GE Healthcare), which is an image processing software program designed for multiplanar reconstruction and volume rendering, was used to create and evaluate images.

**Table 1: Stroke fast track protocol**

Image type	Coverage	Contrast injection	Delayed time (s)	kV	mAs	Slice thickness (mm)
NCCT brain	Foramen magnum through vertex	-	-	120	400	1.25, 5
CTA brain	Foramen magnum through vertex	50 ml, rate 50 ml/s	Use SmartPrep	120	450	0.625, 5
CTA carotid	Aortic arch through vertex	70 ml, rate 50 ml/s	Use SmartPrep	120	Auto mA 300-440	0.625, 5
CTP	16 slices (coverage 8 cm)	45 ml, rate 50 ml/s	5	80	250	5
PCCT brain	Aortic arch through vertex	Scan immediately after complete CTP scan		120	Auto mA 300-440	1.25, 5

NCCT – Noncontrast computed tomography; CTP – Computed tomography perfusion; CTA – Computed tomography angiography; PCCT – Postcontrast computed tomography

### Alberta stroke program early computed tomography score

For NCCT-ASPECTS, ASPECTS was assessed by systematically scoring each of 10 regions on the CT scan [Figure 1], and assigning a score of “1” for a normal region and “0” for a region showing signs of ischemia.<sup>[2]</sup> Signs of ischemia were defined as hypoattenuation, loss of gray-white boundary (which is due to hypoattenuation of the gray matter), and/or effacement of cortical sulci. Only new areas of acute ischemia were scored. The regions

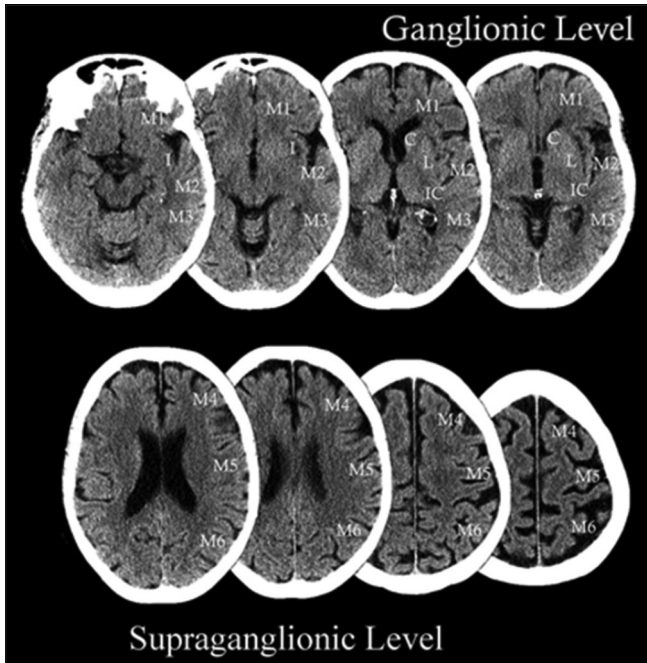


Figure 1: Alberta stroke program early computed tomography score is assessed by systematically scoring each of 10 regions on the computed tomography scan<sup>[2]</sup>

include the subcortical structures, including the caudate nucleus, lentiform nucleus, and internal capsule, genu, and posterior limb only (3 points); and the MCA cortex, including the insular cortex – M1 through M6 (7 points). The score combines localization and volume into a semi-quantitative topographic score. A score of 10 implies, no evidence of new early signs of ischemia in MCA territory, and a progressively lower score indicates more extensive ischemic changes.

For CTP-ASPECTS, ASPECTS was assessed by systematically scoring each of 10 regions on the CTP image (the same regions that were scored for NCCT-ASPECTS), and assigning a score of “1” for a normal region and “0” for an ischemic region. We designed three steps for scoring of brain ischemia in each region, as follows: (1) comparison between bilateral cerebral hemispheres to identify the region of perfusion abnormality; (2) define the abnormal perfusion region as an ischemic area by using cut point at 50% of the color scale bar; and (3) define the same abnormal perfusion region identified in step 2 as an ischemic area by using cut point at 75% of the color scale bar. We applied this 3-step method for all perfusion mapping techniques of CTP (i.e., CBF, CBV, MTT, and TTP). For CBF and CBV, regions of brain parenchyma that displayed color scale <50% and 75% compared with the color scale bar were defined as ischemic. For MTT and TTP, regions of brain parenchyma that displayed color scale >50% and 75% compared with the color scale bar were defined as ischemic [Figure 2]. Therefore, two groups of CTP-ASPECTS data (one at 50% and one at 75%) were collected for each patient.

### Statistical analysis

The study data were analyzed using SPSS Statistics version 21 (SPSS, Inc., Chicago, IL, USA). Two-sample

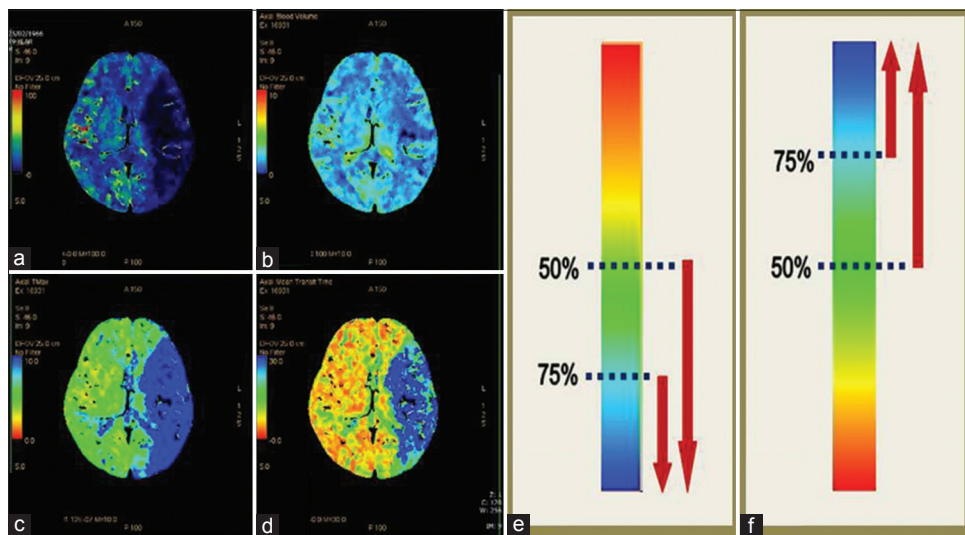


Figure 2: Four perfusion mapping techniques of CTP, including CBF (a), CBV (b), TTP (c), and MTT (d) are shown. The color scale bar of CBF and CBV (e), and TTP and MTT (f), with 50% and 75% cut points. CTP – Computed tomography perfusion; CTA – Computed tomography angiography; TTP – Time to peak; CBF – Cerebral blood flow; MTT – Mean transit time



*t*-test was used to test the difference in quantitative variables with and without normal distribution between patients with favorable and unfavorable clinical outcome. Pearson's correlation coefficient was used to test association between NCCT-ASPECTS and CTP-ASPECTS (CBF-ASPECTS, CBV-ASPECTS, MTT-ASPECTS, and TTP-ASPECTS). Pearson's Chi-square test or Fisher's exact test was used to test the difference in qualitative variables (e.g., gender, side of cerebral hemisphere, and CTP mismatch) between groups. Data are presented as mean  $\pm$  standard deviation or number and percentage. Receiver Operating Characteristic curve was used to evaluate the score that predicts clinical outcome after treatment. A two-tailed  $P < 0.05$  was considered to be statistically significant.

## Results

Data from 44 acute MCA stroke patients that underwent successful MT were included in the final analysis. Eight patients had tandem ICA/proximal MCA occlusion, 34 patients had occlusion of M1 segment of MCA, one patient had occlusion of M2 segment of MCA, and one patient had occlusion of M1 and M2 segment of MCA.

Seventeen patients (38.6%) had favorable clinical outcome (mRS at 3 months: 0–2), and 27 patients (61.4%) had unfavorable clinical outcome (mRS at 3 months: 3–6; 5 patients (11.4%) died). Patients with favorable clinical outcome were significantly more likely to be younger ( $P = 0.009$ ) and to have higher NCCT-ASPECTS ( $P = 0.751$ ), more presence of CTP mismatch ( $P = 1.000$ ), and smaller CTP core infarction ( $P = 1.000$ ) than those with the unfavorable clinical outcome. Females and those with left-sided MCA occlusion were more likely to have an unfavorable clinical outcome ( $P = 0.096$  and  $P = 0.054$ , respectively).

For CTP-ASPECTS at the 50% cut point, patients with favorable clinical outcome had higher CBV-ASPECTS ( $P = 0.630$ ) and higher MTT-ASPECTS ( $P = 0.731$ ) than those with unfavorable clinical outcome. For CTP-ASPECTS at the 75% cut point, patients with favorable clinical outcome had a higher CBV-ASPECTS ( $P = 0.817$ ), CBF-ASPECTS ( $P = 0.603$ ), and MTT-ASPECTS ( $P = 0.063$ ) than those with unfavorable clinical outcome [Table 2, Figures 3 and 4].

Regarding association between NCCT-ASPECTS and CTP-ASPECTS, CBV-ASPECTS at the 50% cut point had the highest correlation with NCCT-ASPECTS ( $r = 0.514$ ), while TTP-ASPECTS at the 50% cut point had the lowest correlation with NCCT-ASPECTS ( $r = 0.026$ ) [Table 3].

The distribution of CTP-ASPECTS data for all measured parameters was not significantly different between the favorable and unfavorable clinical outcome groups. Therefore, no appropriate score to predict the clinical outcome after treatment in this setting was revealed in this study [Figure 5].

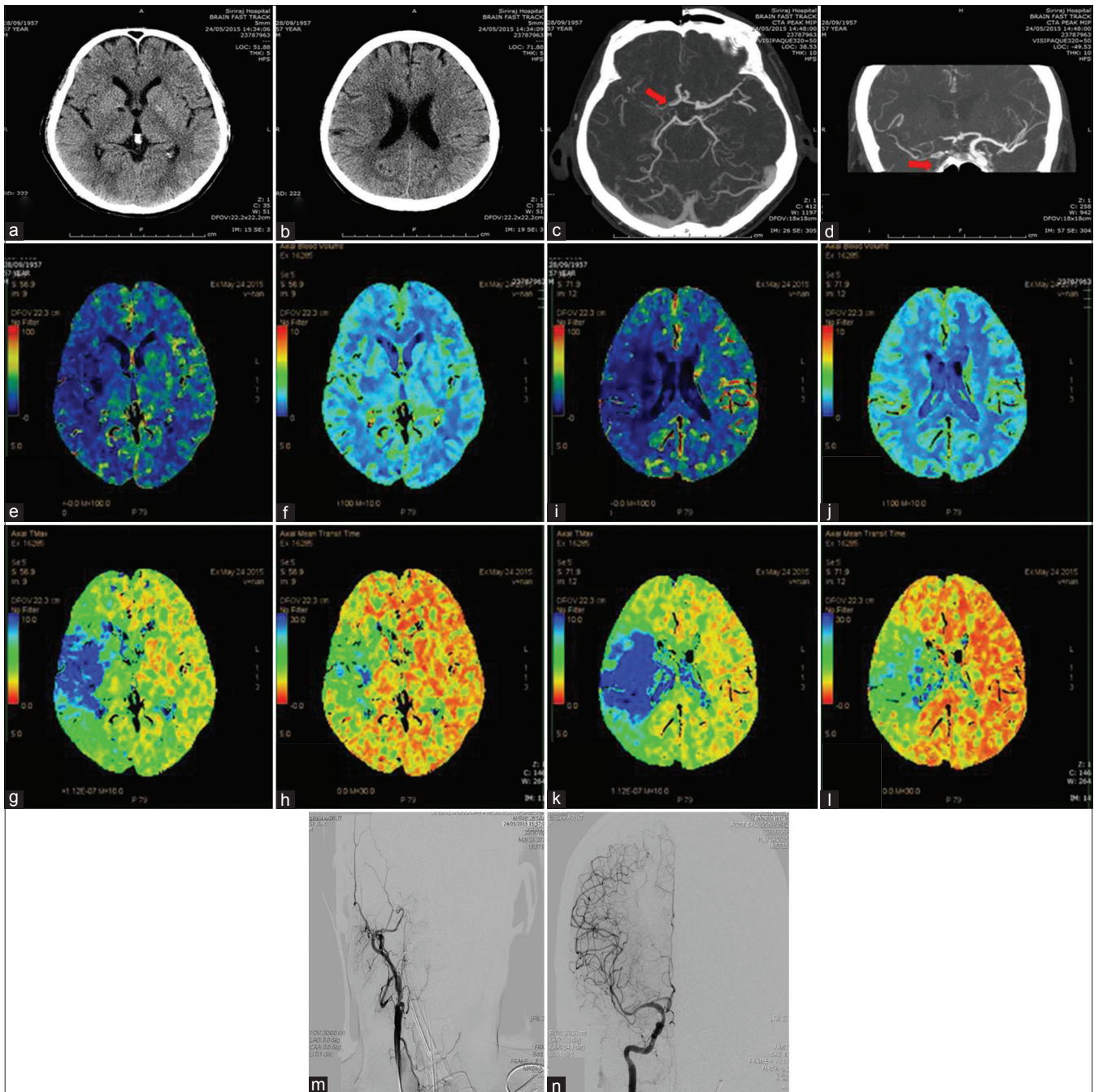
## Discussion

The identification of criteria that improves the selection of ischemic stroke patients most suitable for MT will improve clinical outcomes. ASPECTS is a well-known and widely accepted scoring tool that is easy to learn and easy to teach. ASPECTS provides those who are not expert in CT scan interpretation with a framework to assess acute stroke using CT imaging.<sup>[6,7]</sup> Additionally, ASPECTS is more sensitive to smaller areas of ischemic change than the one-third MCA rule. ASPECTS was first used as a method for scoring NCCT brain to predict clinical outcome.<sup>[2,8]</sup> Recent studies using contrast-enhanced CT techniques, such as the multiphase CTA study by Menon *et al.*<sup>[9]</sup> found benefit for triage of anterior circulation stroke regardless of whether the patient would or would not benefit from immunoaugmentative therapy (IAT) treatment. CTP, an imaging tool that is good for the evaluation of affected brain parenchyma is currently being investigated for its ability to predict clinical outcome after MT in anterior circulation acute ischemic stroke. Given the relative scarcity of data about CTP-ASPECTS,<sup>[5,6]</sup> we set forth to further investigate the efficacy of CTP-ASPECTS for predicting clinical outcome in the immediately aforementioned clinical setting.

Regarding qualitative variables, we found that younger patients were significantly more likely to have a favorable outcome (mRS: 0–2) after MT than older patients ( $P = 0.009$ ). That result corresponds with the result of a study by Beumer *et al.*<sup>[10]</sup> that found a significant inverse association between age and good functional outcome (mRS 0–2) (adjusted odds ratio [aOR]: 0.80, 95% CI: 0.66–0.98) after IAT for every 10-year increase in age. They also reported a significant association between age and the occurrence of all adverse events (aOR: 1.27, 95% CI: 1.08–1.50), as well as the occurrence of nonneurologic adverse events (aOR: 1.34, 95% CI: 1.11–1.61).

Concerning quantitative variables, a recent study by Hill *et al.*<sup>[2]</sup> reported the relative risk of favorable outcome in the NCCT-ASPECTS  $>7$  and  $\leq 7$  groups of 5.0 (95% CI: 1.3–19.2) and 1.0 (95% CI: 0.6–1.9), respectively. In contrast, our study found no significant difference for NCCT-ASPECTS ( $P = 0.751$ ) between the favorable and unfavorable clinical outcome groups.

CT perfusion (CTP) has been used for evaluation of patients with acute stroke for a while.<sup>[11–14]</sup> A recent study by Benson *et al.*<sup>[15]</sup> described the strong correlation between the core infarction on the CTP summary map and the volume of the infarct on diffusion-weighted image relative to reliable estimation of the actual infarct volume. Area infarction is known to be associated with the final clinical outcome. However, our study found no significant difference for any perfusion abnormality on CTP, either area matched or mismatched between outcome groups. Favorable clinical outcome patients had more presence of CTP mismatch ( $P = 1.000$ )



**Figure 3:** A 57-year-old man presented with left hemiparesis for 2 h, with favorable outcome after successful mechanical thrombectomy. Axial NCCT brain at ganglionic level (a) and supraganglionic level (b) showed hypodense area at right MCA cortex lateral to the insular ribbon (M2), and at the superior territory of the right lateral MCA (M5); NCCT-ASPECTS was 8 points. CTA brain axial (c) and coronal (d) images showed filling defect along cavernous and supraclinoid parts of right ICA, and the M1 and M2 segments of right MCA (red arrow). CTP brain at ganglionic level (e-h) and supraganglionic level (i-l) showed mismatch area between CBV (f and j) and MTT (h and l) at rightfrontoparietal area. (CTP-ASPECTS at 50% cut point: CBF-ASPECTS = 1, CBV-ASPECTS = 8, TTP-ASPECTS = 0, MTT-ASPECTS = 1; CTP-ASPECTS at 75% cut point: CBF-ASPECTS = 2, CBV-ASPECTS = 9, TTP-ASPECTS = 4, MTT-ASPECTS = 6). Cerebral angiogram AP view of right CCA pre-IAT (m) showed total occlusion at right carotid bulb and M1 segment of right MCA. AP view of right ICA post-IAT (n) showed recanalization of the right carotid bulb and M1 segment of right MCA. TICI 2b was achieved, and the patient's mRS score at 3 months was 1 point. NCCT – Noncontrast computed tomography; CTP – Computed tomography perfusion; CTA – Computed tomography angiography; MCA – Middle cerebral artery; TTP – Time to peak; CBF – Cerebral blood flow; IAT – Immunoaugmentative therapy; ASPECTS – Alberta stroke program early computed tomography score; MTT – Mean transit time; AP – Anteroposterior

and smaller CTP core infarction ( $P = 1.000$ ) than unfavorable clinical outcome patients. Thus, the use of the established CTP reporting method is likely to be of little value.

Finlayson *et al.*<sup>[3]</sup> reported that CBV had the best reliability for evaluating ischemic brain parenchyma in all areas of ASPECTS compared with NCCT brain, and in almost all areas of ASPECTS compared with CTA brain. Lin *et al.*<sup>[4]</sup>

**Table 2: Demographic, clinical, and imaging data compared between the favorable and unfavorable outcome groups**

	<i>n</i> (%) or mean±SD		<i>P</i>
	Clinical outcome		
	Favorable ( <i>n</i> =17)	Unfavorable ( <i>n</i> =27)	
Age (years)	53.71±18.75	67.67±14.98	0.009 <sup>a</sup>
Gender			
Male	10 (52.6)	9 (47.4)	0.096 <sup>b</sup>
Female	7 (28.0)	18 (72.0)	
Side			
Right	12 (52.2)	11 (47.8)	0.054 <sup>b</sup>
Left	5 (23.8)	16 (76.2)	
NCCT-ASPECTS	7.59±1.46	7.44±1.45	0.751 <sup>a</sup>
CTP-ASPECTS (50% cut point)			
CBV-ASPECTS	7.47±2.29	7.11±2.45	0.630 <sup>a</sup>
CBF-ASPECTS	3.29±2.34	3.33±2.22	0.956 <sup>a</sup>
MTT-ASPECTS	2.71±1.65	2.52±1.81	0.731 <sup>a</sup>
TTP-ASPECTS	2.00±1.41	2.33±1.62	0.489 <sup>a</sup>
CTP-ASPECTS (75% cut point)			
CBV-ASPECTS	7.76±2.31	7.59±2.44	0.817 <sup>a</sup>
CBF-ASPECTS	3.71±2.31	3.33±2.29	0.603 <sup>a</sup>
MTT-ASPECTS	4.18±2.01	2.93±2.18	0.063 <sup>a</sup>
TTP-ASPECTS	2.53±1.33	3.04±1.81	0.324 <sup>a</sup>
CTP mismatch			
No	0 (0.0)	1 (100.0)	1.000 <sup>c</sup>
Yes	17 (39.5)	26 (60.5)	
CTP core infarction			
≤1/3	14 (40.0)	21 (60.0)	1.000 <sup>c</sup>
>1/3	3 (33.3)	6 (66.7)	

<sup>a</sup>Two-sample *t*-test, <sup>b</sup>Pearson’s Chi-square test, <sup>c</sup>Fisher’s exact test, *P*<0.05 indicates statistical significance. SD – Standard deviation; CTP – Computed tomography perfusion; ASPECTS – Alberta stroke program early computed tomography score; NCCT – Noncontrast computed tomography; CBV – Cerebral blood volume; CBF – Cerebral blood flow; MTT – Mean transit time; TTP – Time to peak

**Table 3: Correlation between noncontrast computed tomography-Alberta stroke program early computed tomography score and computed tomography perfusion-Alberta stroke program early computed tomography score**

	NCCT-ASPECTS ( <i>n</i> =44)
	<i>r</i>
CTP-ASPECTS (50% cut point)	
CBV-ASPECTS	0.514
CBF-ASPECTS	0.375
MTT-ASPECTS	0.093
TTP-ASPECTS	0.026
CTP-ASPECTS (75% cut point)	
CBV-ASPECTS	0.489
CBF-ASPECTS	0.366
MTT-ASPECTS	0.237
TTP-ASPECTS	0.212

Test by Pearson correlation coefficient. CTP – Computed tomography perfusion; ASPECTS – Alberta stroke program early computed tomography score; NCCT – Noncontrast computed tomography; CBV – Cerebral blood volume; CBF – Cerebral blood flow; MTT – Mean transit time; TTP – Time to peak

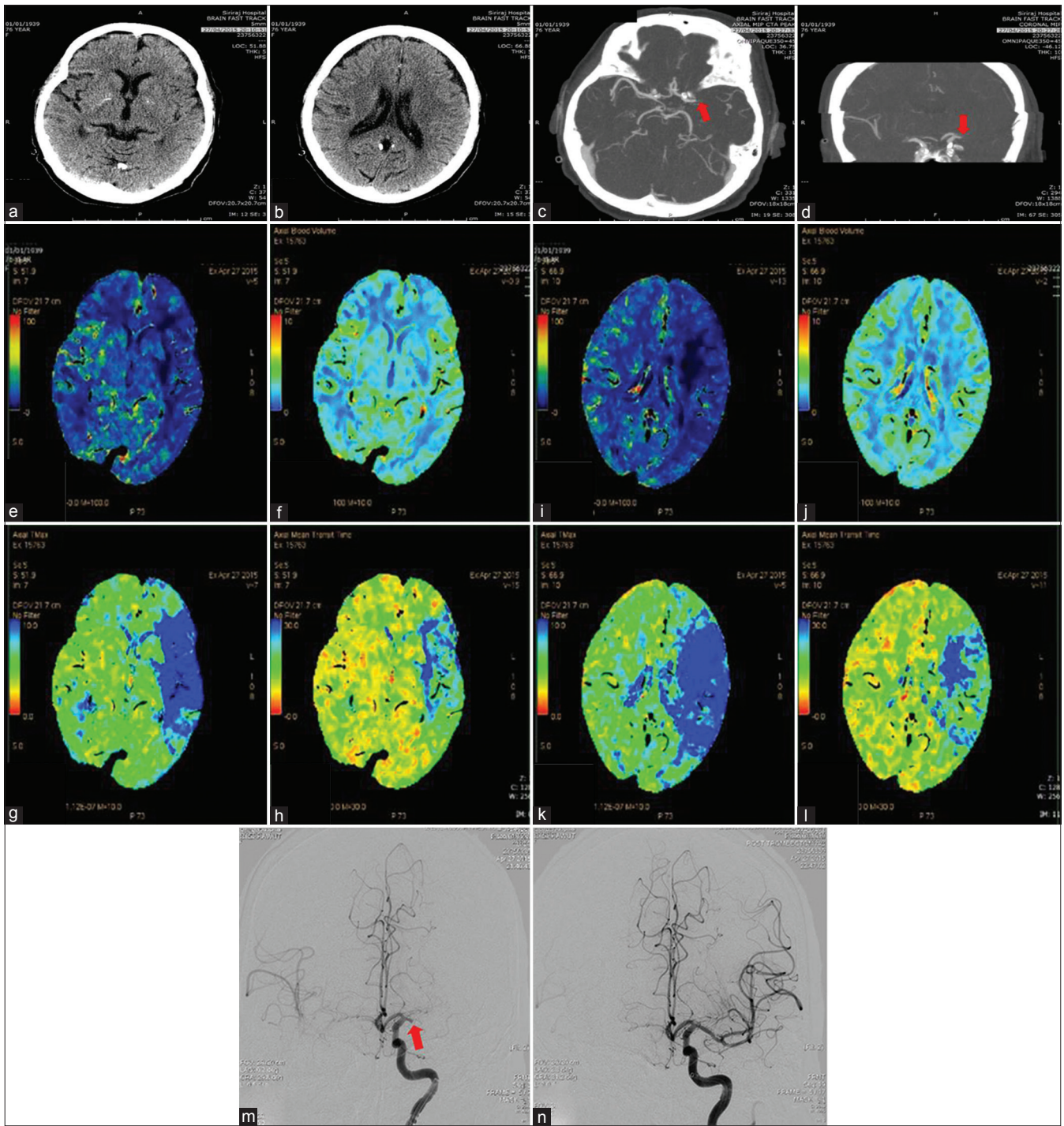
showed the accuracy of NCCT, CTA source images, and CTP (CBV) for detecting regional infarct to be 80.0%,

84.3%, and 96.8%, respectively (*P* < 0.0001). Based on the findings of those two studies, area with a different degree of ischemia and area of infarction is considered to be easily separated.

We then set forth to predict the clinical outcome by assessing the degree of parenchymal ischemia/infarction using CTP-ASPECTS, which was determined using cut points at 50% and 75% of abnormality as observed on the color scale bar. The results our analysis showed no statistically significant differences for CTP-ASPECTS (CBF-ASPECTS, CBV-ASPECTS, MTT-ASPECTS, and TTP-ASPECTS) at the 50% and 75% cut points of abnormality between the favorable and unfavorable clinical outcome groups. Of all measured parameters, MTT-ASPECTS at the 75% cut point was the parameter that came closest to significantly predicting clinical outcome (*P* = 0.063).

Finlayson, *et al.*<sup>[3]</sup> also reported that total ASPECTS, when compared with NCCT brain CTA brain, and CTP brain, had very good concordance, internal consistency, and internal reliability. Regarding the correlation between NCCT-ASPECTS and CTP-ASPECTS (included their mean value), CBV-ASPECTS at the 50% cut





**Figure 4:** A 76-year-old woman with history of diabetes mellitus type 2 and hypertension presented with right hemiparesis for approximately 2 h, with unfavorable outcome after successful mechanical thrombectomy. Axial NCCT brain at ganglionic level (a) and supraganglionic level (b) showed hypodense area at left insular cortex, left lentiform nucleus, left anterior MCA cortex (M1), and superior territory of left lateral MCA (M5); NCCT-ASPECTS was 6 points. CTA brain axial (c) and coronal (d) images showed abrupt filling defect at M1 segment of left MCA (red arrow). CTP brain at ganglionic level (e-h) and supraganglionic level (i-l) showed core infarction at left lentiform nucleus (less than 1/3 of left MCA territory) and mismatch area between CBV (f and j) and MTT (h and l) at left frontotemporoparietal area (CTP-ASPECTS at 50% cut point: CBF-ASPECTS = 1, CBV-ASPECTS = 6, TTP-ASPECTS = 2, MTT-ASPECTS = 2; CTP-ASPECTS at 75% cut point: CBF-ASPECTS = 0, CBV-ASPECTS = 8, TTP-ASPECTS = 2, MTT-ASPECTS = 2). Cerebral angiogram AP view of left ICA pre-IAT (m) showed total occlusion at M1 segment of left MCA (red arrow). The same view post-IAT (n) showed recanalization of M1 segment of left MCA. Although TIC1 3 was achieved, the patient's mRS score at 3 months was 5 points. NCCT – Noncontrast computed tomography; CTP – Computed tomography perfusion; CTA – Computed tomography angiography; MCA – Middle cerebral artery; TTP – Time to peak; CBF – Cerebral blood flow; IAT – Immunoaugmentative therapy; ASPECTS – Alberta stroke program early computed tomography score; MTT – Mean transit time; AP – Anteroposterior

point was found to have the highest correlation with NCCT-ASPECTS ( $r = 0.514$ ), while TTP-ASPECTS

at the 50% cut point had the lowest correlation with NCCT-ASPECTS ( $r = 0.026$ ). No statistically significant

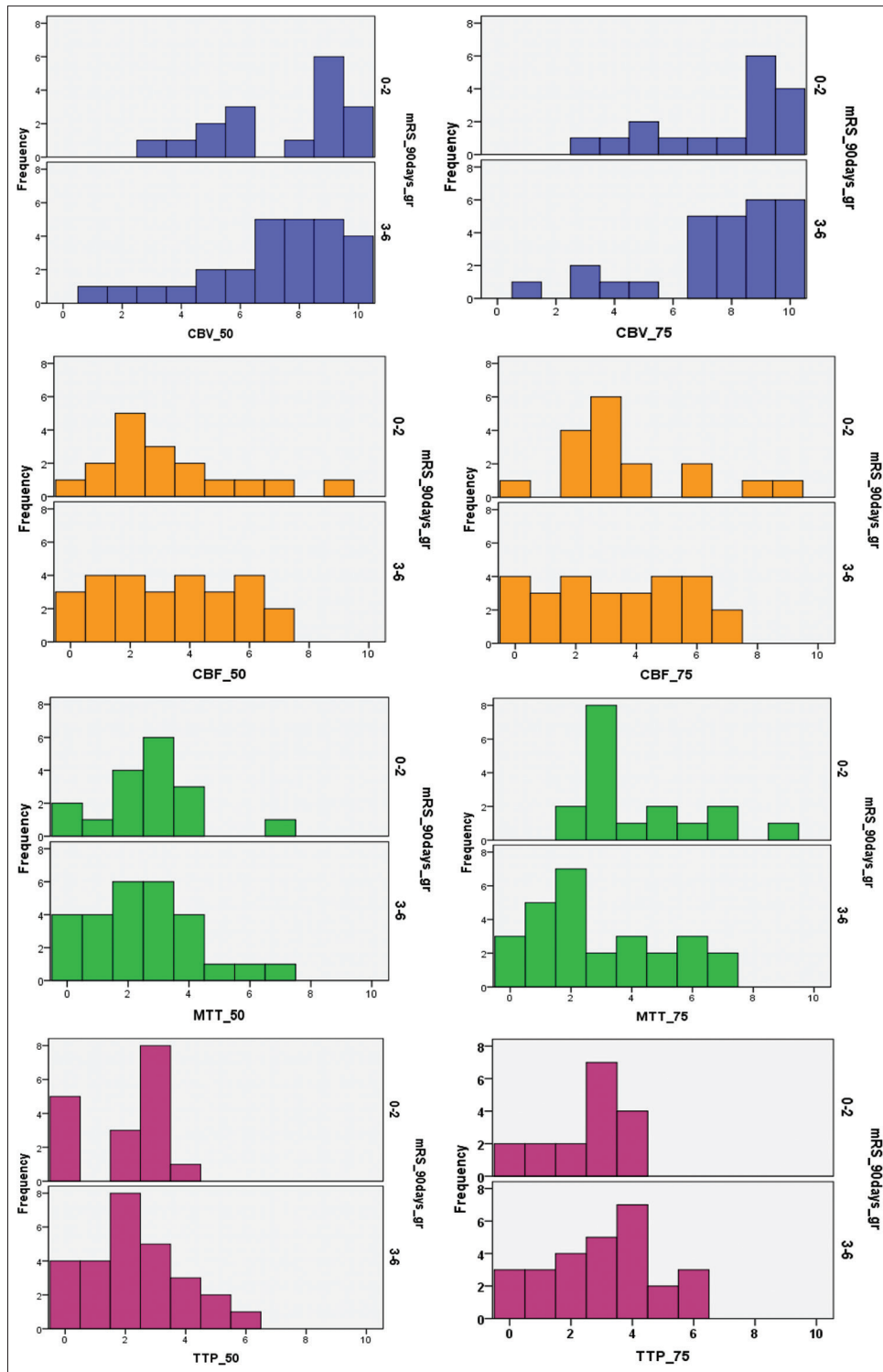


Figure 5: Distribution of computed tomography score-Alberta stroke program early computed tomography score in the favorable (top section of each bar graph) clinical outcome and unfavorable (bottom section of each bar graph) clinical outcome groups

association was observed between NCCT-ASPECTS and CTP-ASPECTS (CBF-ASPECTS, CBV-ASPECTS, MTT-ASPECTS, and TTP-ASPECTS) at 50% and 75% cut points in this study. Our small study population may have limited our ability to identify a statistically significant association between these

parameters. Our finding is consistent with that of Aviv *et al.*<sup>[5]</sup> who reported a cut point for CBV-ASPECTS of  $\geq 8$  for predicting major neurologic improvement (increase in NIHSS to  $\geq 8$  points at 24 h after tPA treatment) ( $P = 0.02$ ), and good clinical outcome (mRS of  $\leq 2$  at 3 months after tPA treatment).



Color images from any type of CTP are better able to demonstrate abnormality when compared with gray-scale images from NCCT. However and in general, CTP-ASPECTS was not shown to be a suitable alternative to NCCT-ASPECTS. Only CBV-ASPECTS was shown to be closely correlated with NCCT-ASPECTS, and is, therefore, the only parameter that we can recommend for use in routine practice. The reason the other CTP parameters did not correlate with NCCT-ASPECTS is unclear, but it could be due to the way that the image processes and represents the pathology. NCCT-ASPECTS demonstrates ischemic/infarction area by process of cytotoxicity with or without vasogenic edema, which results in increased brain water that, in turn, results in a reduction of brain parenchyma density and hypodensity. In contrast, changes on CTP were related to changes in cerebral blood perfusion and brain reaction that happens earlier than the process of edema. Changes in the parameter related to blood flow (CBF) and the parameters related to time (TTP and MTT) that convey the blood to the brain parenchyma are generally vivid, exaggerated, and unequal to CBV, which reflects the volume of blood change. These factors influence our visualization and scoring of CTP-ASPECTS, which was originally developed on NCCT.

Based on the findings of this study and from our experience in routine practice, we recommend the use of CTP-ASPECTS, especially CBV-ASPECTS, in borderline NCCT-ASPECTS (NCCT-ASPECTS 6–7) that has clinical-imaging mismatch, which indicates that there is probably some salvageable area remaining that may benefit from MT. The use of CTP-ASPECTS in combination with the old method of CTP-interpretation (the mismatched concept) is a cause of potential concern. Further study for this issue might be helpful in find out the best imaging for selection patient who will benefit from MT.

The present study was unable to identify a cut point for any of the measured CTP-ASPECTS parameters at either 50% abnormality or 75% abnormality for predicting clinical outcome after thrombectomy. It is important to note that no cut point for any of the studied parameters has been previously reported in this setting.

The limitations of this study were its single-center retrospective design and its small study population, which was due to the fact that we included only MCA occlusion that underwent successful MT. Further study with a larger sample size may have more power to identify significant associations or differences between groups and also benefit in additional radiation dose from CTP.

## Conclusions

CTP-ASPECTS at the 50% and 75% cut points of abnormality could not predict the clinical outcome of anterior ischemic stroke after MT. Of the ASPECTS evaluated in this study, MTT-ASPECTS at the 75% cut

point was the most predictive CT parameter. Older age was associated with unfavorable clinical outcome after MT.

## Declaration of patient consent

The authors certify that they have obtained all appropriate patient consent forms. In the form, the patients have given their consent for their images and other clinical information to be reported in the journal. The patient understands that name and initials will not be published, and due efforts will be made to conceal identity, but anonymity cannot be guaranteed.

## Financial support and sponsorship

Nil.

## Conflicts of interest

There are no conflicts of interest.

## References

1. Jauch EC, Saver JL, Adams HP Jr., Bruno A, Connors JJ, Demaerschalk BM, *et al.* Guidelines for the early management of patients with acute ischemic stroke: A guideline for healthcare professionals from the American Heart Association/American Stroke Association. *STROKE* 2013;44:870-947.
2. Hill MD, Rowley HA, Adler F, Eliasziw M, Furlan A, Higashida RT, *et al.* Selection of acute ischemic stroke patients for intra-arterial thrombolysis with pro-urokinase by using ASPECTS. *Stroke* 2003;34:1925-31.
3. Finlayson O, John V, Yeung R, Dowlatshahi D, Howard P, Zhang L, *et al.* Interobserver agreement of ASPECT score distribution for noncontrast CT, CT angiography, and CT perfusion in acute stroke. *Stroke* 2013;44:234-6.
4. Lin K, Rapalino O, Law M, Babb JS, Siller KA, Pramanik BK. Accuracy of the alberta stroke program early CT score during the first 3 hours of middle cerebral artery stroke: Comparison of noncontrast CT, CT angiography source images, and CT perfusion. *AJNR Am J Neuroradiol* 2008;29:931-6.
5. Aviv RI, Mandelcorn J, Chakraborty S, Gladstone D, Malham S, Tomlinson G, *et al.* Alberta stroke program early CT scoring of CT perfusion in early stroke visualization and assessment. *AJNR Am J Neuroradiol* 2007;28:1975-80.
6. Pexman JH, Barber PA, Hill MD, Sevick RJ, Demchuk AM, Hudon ME, *et al.* Use of the alberta stroke program early CT score (ASPECTS) for assessing CT scans in patients with acute stroke. *AJNR Am J Neuroradiol* 2001;22:1534-42.
7. Goyal M, Menon BK. Understanding Alberta Stroke Program Early CT Score. Available from: <http://aspectsinstroke.com>. [Last accessed on 2014 Oct 10].
8. Barber PA, Demchuk AM, Zhang J, Buchan AM. Validity and reliability of a quantitative computed tomography score in predicting outcome of hyperacute stroke before thrombolytic therapy. ASPECTS study group. Alberta stroke programme early CT score. *Lancet* 2000;355:1670-4.
9. Menon BK, d'Este CD, Qazi EM, Almekhlafi M, Hahn L, Demchuk AM, *et al.* Multiphase CT angiography: A new tool for the imaging triage of patients with acute ischemic stroke. *Radiology* 2015;275:510-20.
10. Beumer D, Rozeman AD, Lycklama À Nijeholt GJ, Brouwer PA, Jenniskens SF, Algra A, *et al.* The effect of age on outcome after intra-arterial treatment in acute ischemic stroke: A MR CLEAN pretrial study. *BMC Neurol* 2016;16:68.

11. Shetty SK, Lev MH. CT perfusion in acute stroke. *Neuroimaging Clin N Am* 2005;15:481-501, ix.
12. Nabavi DG, Kloska SP, Nam EM, Freund M, Gaus CG, Klotz E, *et al.* MOSAIC: Multimodal stroke assessment using computed tomography: Novel diagnostic approach for the prediction of infarction size and clinical outcome. *Stroke* 2002;33:2819-26.
13. Gasparotti R, Grassi M, Mardighian D, Frigerio M, Pavia M, Liserre R, *et al.* Perfusion CT in patients with acute ischemic stroke treated with intra-arterial thrombolysis: Predictive value of infarct core size on clinical outcome. *AJNR Am J Neuroradiol* 2009;30:722-7.
14. Prabhakaran S, Soltanolkotabi M, Honarmand AR, Bernstein RA, Lee VH, Connors JJ, *et al.* Perfusion-based selection for endovascular reperfusion therapy in anterior circulation acute ischemic stroke. *AJNR Am J Neuroradiol* 2014;35:1303-8.
15. Benson J, Payabvash S, Salazar P, Jagadeesan B, Palmer CS, Truwit CL, *et al.* Comparison of CT perfusion summary maps to early diffusion-weighted images in suspected acute middle cerebral artery stroke. *Eur J Radiol* 2015;84:682-9.