

Scedosporium apiospermum: An Emerging Fatal Cause of Fungal Abscess and Ventriculitis after Near-drowning

Abstract

Herein, we describe a fatal case of central nervous system (CNS) pseudallescheriasis following near-drowning. A 13-year-old boy, who had been successfully resuscitated after near-drowning, presented with a transient episode of mental confusion during a hospital stay after recovering from severe aspiration pneumonia and respiratory failure. A magnetic resonance imaging (MRI) scan of the brain showed a small brain abscess in the left basal ganglia and ventriculitis in the left lateral ventricle. The brain abscess and ventriculitis did not respond to 4 weeks of antibiotic treatment and appeared even worse on a follow-up MRI. A diagnosis of CNS pseudallescheriasis was only possible with invasive stereotactic biopsy and aspiration of the abscess that showed the presence of hyphae and *Scedosporium apiospermum*. CNS pseudallescheriasis did not respond to multiple combinations of antifungal agents, including amphotericin B, isoconazole, itraconazole, and voriconazole. Two ventricular drainages and insertion of Ommaya reservoirs with intraventricular injection of voriconazole were insufficient to halt the infection. The patient passed away from sudden septic shock 2 months after identification of the brain abscess and ventriculitis. The patient's diagnosis was delayed because multiple examinations of the cerebrospinal fluid did not show positive cultures and could only be obtained from the aspirates of stereotactic biopsy. Physicians should be aware of CNS pseudallescheriasis associated with near-drowning because of the difficulty of diagnosis and the high mortality rate (70%) owing to poor responses to currently available antifungal agents.

Keywords: Brain abscess, cerebral infections, fungal meningitis, near-drowning, *Pseudallescheria boydii*, *Scedosporium apiospermum*

Introduction

Drowning is one of the three leading causes of accidental death in young, otherwise healthy individuals.^[1] Near-drowning, defined as a submersion episode severe enough to warrant hospital admission, is estimated to occur 2–20 times more frequently than drowning. Infection is one of the complications of near-drowning that may result in premature death or permanent disability. Fungal infection caused by the presence of generally harmless saprophytes in victims of near-drowning is increasingly being reported to cause serious or lethal infections, even in immunocompetent individuals.^[2] *Scedosporium apiospermum* and its teleomorph (sexual form) *Pseudallescheria boydii* are increasingly recognized as causes of localized and disseminated mycotic infections in near-drowning victims.^[3–6] These fungi are ubiquitous and are present in soil, manure,

sewage, polluted water and decaying vegetation.^[4–6]

Over the last two decades, at least 21 cases of *S. apiospermum*/*P. boydii* infection associated with near-drowning in polluted waters have been reported; two of those cases involved survivors of the tsunami in Southeast Asia in December 2004.^[7] Currently, *P. boydii*/*S. apiospermum* is recognized as the fungus most commonly implicated in invasive disease after near-drowning. Scedosporiosis after near-drowning was reported to be associated with high mortality (70%), even in immunocompetent hosts and showed a slow progression (mean survival time, 87 days).^[3,8] Dissemination to the central nervous system (CNS) resulting in multiple brain abscesses was also high (91%) and the diagnosis is typically delayed (mean time to diagnosis 28 days).^[3] We report a fatal case of *S. apiospermum* which presented as a brain abscess and ventriculitis in a boy following a near-drowning accident. This study was approved by the Institutional Review Board of our institute (KC16ZISE0596).

Min-gi Lee¹,
Jin-gyu Choi¹,
Byung-chul Son^{1,2}

¹Department of Neurosurgery, College of Medicine, The Catholic University of Korea, Seoul St. Mary's Hospital, ²Catholic Neuroscience Institute, College of Medicine, The Catholic University of Korea, Seoul, Republic of Korea

Address for correspondence:
Prof. Byung-chul Son,
Department of Neurosurgery,
Seoul St. Mary's Hospital,
College of Medicine, Catholic
Neuroscience Institute, The
Catholic University of Korea,
222 Banpo-daero, Seocho-gu,
Seoul 06591, Republic of Korea.
E-mail: sbc@catholic.ac.kr

Access this article online

Website: www.asianjns.org

DOI: 10.4103/ajns.AJNS_236_16

Quick Response Code:



How to cite this article: Lee MG, Choi JG, Son BC. *Scedosporium apiospermum*: An emerging fatal cause of fungal abscess and ventriculitis after near-drowning. Asian J Neurosurg 2018;13:792-6.

This is an open access journal, and articles are distributed under the terms of the Creative Commons Attribution-NonCommercial-ShareAlike 4.0 License, which allows others to remix, tweak, and build upon the work non-commercially, as long as appropriate credit is given and the new creations are licensed under the identical terms.

For reprints contact: reprints@medknow.com

Case Report

A 13-year-old boy was referred to the Department of Neurosurgery for stereotactic biopsy for a brain abscess which did not respond to over 4 weeks of treatment with antifungal agents. Seventy-five days before consultation, he had experienced an accidental near-drowning event in a river and had been revived from cardiac arrest. Severe aspiration pneumonia associated acute respiratory failure and acute renal failure subsequently developed, and he was treated with ventilator support, extracorporeal membrane oxygenation, and continuous renal replacement therapy in an intensive care unit (ICU) for 1 month. During the stay in the ICU, multiple bacteria were cultured from his sputum, including *Acinetobacter baumannii*, *Elizabethkingia meningoseptica*, and methicillin-resistant *Staphylococcus aureus*. Several antibiotics were prescribed according to the culture results, and he was weaned from the ventilator with improvement of pneumonia.

He was then transferred to the general ward specializing in *vancomycin-resistant enterococci* and was managed for poor oral intake, nausea, and general weakness. Forty days after admission, a transient episode of mental confusion with disorientation developed and a magnetic resonance imaging (MRI) scan of the brain was performed. The brain MRI scan showed an approximately 8 mm diameter contrast-enhancing lesion in the left frontal white matter [Figure 1]. Examination of the cerebrospinal fluid (CSF) showed red blood cell (RBC), 0 cells/ μ l; white blood cell (WBC), 1600 cells/ μ l (neutrophils, 58%, lymphocytes, 12%, eosinophils, 1%, monocytes, 28%, and basophils, 1%); protein, 141.3 mg/dl; and glucose, 36 mg/dl. The CSF culture was negative for bacteria and fungi. Under a diagnosis of brain abscess and ventriculitis, antibiotics (vancomycin, cefotaxime, metronidazole, Cotrim® [trimethoprim and sulfamethoxazole], and amphotericin B) with broad-spectrum coverage including action against anaerobes were prescribed. The patient's mental confusion improved immediately, and intravenous antibiotics were maintained for 4 weeks.

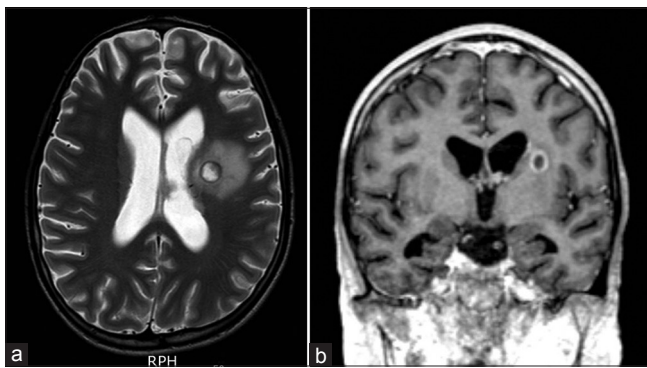


Figure 1: Magnetic resonance imaging findings in central nervous system pseudallescheriasis. T2-weighted axial (a) and enhanced T1-weighted coronal (b) images showing an aggravation of brain edema with enhancement of the left lateral ventricle.

However, surrounding edema became enlarged, and enhancement of the left lateral ventricle indicating ventriculitis was present on the follow-up MRI taken after 4 weeks of antibiotic treatment [Figure 2]. The antibiotic regimen was changed to a combination of voriconazole, meropenem, and Cotrim®. The CSF culture did not reveal any growth of bacteria or fungi, despite of CSF pleocytosis. Considering antibiotic resistance and the possibility of a fungal abscess, a stereotactic biopsy was performed. During aspiration of the abscess, a greenish-yellow pus was observed and multiple hyphae were found on H- and E-stained sections [Figure 2c]. The analysis of CSF at the time of biopsy revealed RBC, 0 cells/ μ l; WBC, 16,500 cells/ μ l (neutrophils, 65%, lymphocytes, 15%, and macrophages, 20%); protein, 141.3 mg/dl, and glucose, 36 mg/dl.

S. apiospermum was found in a culture of the aspirate. The intravenous antibiotics were changed to voriconazole, isoconazole, and amphotericin B and maintained as such. After 3 weeks of treatment with multiple antifungal agents and maintenance of an alert mentality without neurologic impairment, more diffuse contrast enhancement and dilation of the left lateral ventricle and aggravation of the edema around the abscess were observed on a follow-up MRI. Extraventricular drainage of the left lateral ventricle was performed, and CSF drainage (150–200 ml/day) was maintained along with continued treatment with multiple antifungal agents, including voriconazole.

After 2 weeks of left frontal external ventricular drain (EVD), an intraventricular injection of voriconazole (5 mg) was performed through an Ommaya valve in the left lateral ventricle. However, the patient became quite drowsy on the day following intraventricular injection of voriconazole, and an emergent MRI revealed a marked dilation with acute hydrocephalus, along with

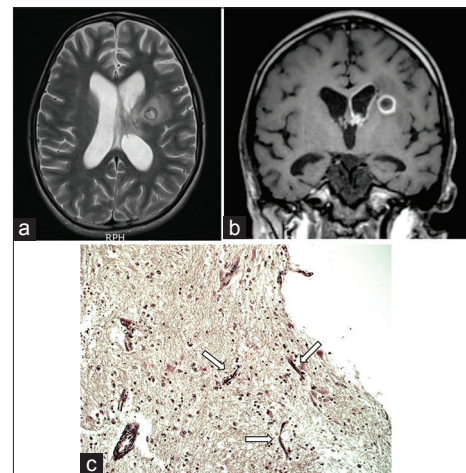


Figure 2: Magnetic resonance imaging findings after 4 weeks of antibiotic treatment. T2-weighted axial (a) and enhanced T1-weighted coronal (b) images showing an aggravation of brain edema with enhancement of the left lateral ventricle. (c) A photograph showing the appearance of multiple hyphae (arrows) in the aspirates (silver stain, $\times 40$)

septations within the left lateral ventricle [Figure 3]. Following mannitol treatment, he became alert and reported experiencing a minimal headache. A repeated EVD associated with endoscopic septostomy was performed with an occipital burr-hole trephination the next day. After EVD, the patient was alert and no signs or symptoms of increased intracranial pressure were observed. His vital signs were stable. On the day following the occipital EVD, sudden hypotension with respiratory distress consistent with acute septic shock developed and the patient was transferred to the ICU. Despite maximal vasopressor and ventilator treatment, the patient expired after 12 h.

Discussion

Central nervous system pseudallescheriasis after near-drowning

The members of the *P. boydii* species complex are commonly found in soil, sewage, mud, and the polluted waters of streams and ponds with still water.^[9,10] *P. boydii* is, after *Aspergillus*, one of the most prevalent molds that give rise to human disease. These fungi show a particular tropism for the CNS.^[10] *P. boydii* are known to consist of a complex that includes several phylogenetic species^[11] and *S. apiospermum*, traditionally considered the anamorph (asexual state of *P. boydii*), and *S. apiospermum* are two different species.^[12]

According to a comprehensive review,^[8] only 99 cases of CNS pseudallescheriasis had been reported until 2008, and 25 of them were associated with near-drowning.^[8] It was found that CNS pseudallescheriasis affected both previously healthy, immunocompetent patients (44%) and immunosuppressed patients (56%).^[8] Fifty-five percent of immunocompetent patients had a prior history of aspiration of polluted water in association with near-drowning; they included tsunami survivors^[7] or those involved in motor vehicle accidents.^[8,13] Medically induced

immunosuppression in transplant recipients is a major risk in immunocompromised patients.^[8] The main clinical spectrums of CNS involvement are brain abscess (69%), coinfection of brain and/or spinal cord meninges (10%), and meningitis (9%).^[3,8] Cerebral abscess with concomitant ventriculitis, as in the clinical findings in the present case, was reported in four previous cases (4%).^[8]

Near-drowning can cause pulmonary and neurological damage, and infection is a potentially life-threatening complication.^[2] The incidence of pneumonia has been reported to be as high as 71% among patients with CNS pseudallescheriasis after near-drowning.^[8] One interesting finding is that an antemortem diagnosis of *P. boydii* complex pulmonary infection following a near-drowning episode is quite rare,^[8,14] and the first symptoms exhibited by such patients are usually evident in the brain. Furthermore, sputum and/or other respiratory sample cultures included bacteria belonging to numerous genera but not the *P. boydii* complex.^[8] In line with these previous findings, *P. boydii* was not found in cultures taken during the patient's stay in the ICU for respiratory failure or while under ventilatory care for 1 month.

The time of onset of CNS pseudallescheriasis is greatly affected by the route of infection and inoculum size.^[8] The incubation period in near-drowned patients, who aspirated a sufficient amount of mold, is approximately 1–3 weeks.^[8,15] However, an occurrence of brain abscess secondary to bilateral *P. boydii* complex endophthalmitis 1 year after surgery in a cadaveric kidney recipient who had been transplanted with a cadaveric kidney of a victim of near-drowning has been reported.^[16] Although inhalation of airborne conidia followed by hematogenous spread to the brain is the most common route of CNS pseudallescheriasis,^[8,17,18] hematogenous spread after invasive pneumonitis was suspected in the present.

The CSF cultures obtained from lumbar punctures before stereotactic biopsy were negative in the present case, and a diagnosis of brain abscess from pseudallescheriasis was, as usual, delayed (75 days after admission). A relatively high percentage of negative CSF cultures (35%) was reported,^[8] and encapsulated abscess formation by the fungus in the brain was suggested as a cause.^[8] Even a pachymeningitis case secondary to pansinusitis showed negative culture results.^[19] Therefore, a diagnosis is established postmortem in 30% of cases of pseudallescheriasis,^[8] and the median time to diagnosis was reported to be 28 days.^[3]

Difficulties in early diagnosis

The diagnosis of pseudallescheriasis is typically delayed and difficult.^[3,8,9] In the present case, clinical manifestations of CNS involvement took 75 days after initial resuscitation to develop, and a definite diagnosis of brain abscess and ventriculitis by *P. boydii* took an additional 30 days until an invasive, stereotactic biopsy was performed. Although

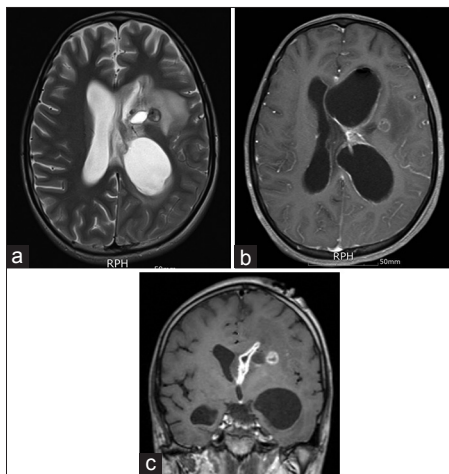


Figure 3: Further aggravation of brain edema (a) and further enhancement of the lateral ventricle with septated hydrocephalus in T1-weighted axial (b) and coronal (c) images

the possibility of a fungal abscess had been kept in mind given poor antibiotics response seen on repeated MRI examinations and antifungal agents were started 4 weeks before stereotactic biopsy, we could not identify the organism causing brain abscess with ventriculitis until the identifying hyphae on the stain and taking a culture of the aspirate through stereotactic biopsy. CSF culture was revealed to not be a very important tool in the diagnosis of pseudallescheriasis.^[3,8] It seems that a history of near-drowning, a latent period, and a preceding pulmonary infection could be clues to a diagnosis of CNS pseudallescheriasis.

Treatment and prognosis of central nervous system pseudallescheriasis

CNS infection caused by *P. boydii* complex has a poor prognosis. It nearly always proves fatal even when it occurs in previously healthy individuals. The overall mortality of scedosporiosis after near-drowning is approximately 74%^[3,8] while the prognostic factors remain largely unknown. The mortality rates are high regardless of the patient's immune status (immunocompetent or immunocompromised) or the infection type and/or location.^[3,8]

The main reason for the poor prognosis is the resistance of *P. boydii* to conventional antifungal agents, including amphotericin B, and difficulty in early diagnosis. In the absence of controlled clinical trials on an optimal anti-scedosporial treatment, treatment options are based almost entirely on *in vitro* and experimental animal studies and published cases reports.^[3] *In vitro* susceptibility studies have shown that *S. apiospermum* isolates are susceptible to miconazole, voriconazole, and posaconazole, resistant to fluconazole and flucytosine, and appear to have variable susceptibility to ketoconazole, itraconazole, and amphotericin B.^[3,20,21] Most successfully treated cases were reported relatively recently, and the beneficial effect of voriconazole was underlined.^[14,21-23] According to a review of cases,^[3] it was suggested that voriconazole be used very early in cases of suspected scedosporiosis after near-drowning or even prophylactically in all near-drowned patients.^[3]

Conclusions

To date, few cases of CNS pseudallescheriasis have been described. Considering the difficulties in establishing a correct diagnosis, the high mortality rate, and the resistance to antifungal agents, as seen in the present case, pseudallescheriasis should always be suspected in individuals who have suffered near-drowning events.

Financial support and sponsorship

Nil.

Conflicts of interest

There are no conflicts of interest.

References

- Bierens JJ, Knape JT, Gelissen HP. Drowning. *Curr Opin Crit Care* 2002;8:578-86.
- Ender PT, Dolan MJ. Pneumonia associated with near-drowning. *Clin Infect Dis* 1997;25:896-907.
- Katragkou A, Dotis J, Kotsiou M, Tamiolaki M, Roilides E. *Scedosporium apiospermum* infection after near-drowning. *Mycoses* 2007;50:412-21.
- Tadros TS, Workowski KA, Siegel RJ, Hunter S, Schwartz DA. Pathology of hyalohyphomycosis caused by *Scedosporium apiospermum* (*Pseudallescheria boydii*): An emerging mycosis. *Hum Pathol* 1998;29:1266-72.
- O'Bryan TA. Pseudallescheriasis in the 21st century. *Expert Rev Anti Infect Ther* 2005;3:765-73.
- Guarro J, Kantarcioglu AS, Horr e R, Rodriguez-Tudela JL, Cuenca Estrella M, Berenguer J, et al. *Scedosporium apiospermum*: Changing clinical spectrum of a therapy-refractory opportunist. *Med Mycol* 2006;44:295-327.
- Garzoni C, Emonet S, Legout L, Benedict R, Hoffmeyer P, Bernard L, et al. Atypical infections in tsunami survivors. *Emerg Infect Dis* 2005;11:1591-3.
- Kantarcioglu AS, Guarro J, de Hoog GS. Central nervous system infections by members of the *Pseudallescheria boydii* species complex in healthy and immunocompromised hosts: Epidemiology, clinical characteristics and outcome. *Mycoses* 2008;51:275-90.
- Kowacs PA, Soares Silvado CE, Monteiro de Almeida S, Ramos M, Abr o K, Madaloso LE, et al. Infection of the CNS by *Scedosporium apiospermum* after near drowning. Report of a fatal case and analysis of its confounding factors. *J Clin Pathol* 2004;57:205-7.
- de Hoog GS, Marvin-Sikkema FD, Lahpoor GA, Gottschall JC, Prins RA, Gu ho E. Ecology and physiology of the emerging opportunistic fungi *Pseudallescheria boydii* and *Scedosporium prolificans*. *Mycoses* 1994;37:71-8.
- Gilgado F, Cano J, Gen e J, Guarro J. Molecular phylogeny of the *Pseudallescheria boydii* species complex: Proposal of two new species. *J Clin Microbiol* 2005;43:4930-42.
- Gilgado F, Cano J, Gen e J, Sutton DA, Guarro J. Molecular and phenotypic data support distinct species status for *Scedosporium apiospermum* and *Pseudallescheria boydii* and the new species *Scedosporium dehoogii*. *J Clin Microbiol* 2008;46:766-71.
- Kershaw P, Freeman R, Templeton D, DeGirolami PC, DeGirolami U, Tarsy D, et al. *Pseudallescheria boydii* infection of the central nervous system. *Arch Neurol* 1990;47:468-72.
- Chaney S, Gopalan R, Berggren RE. Pulmonary *Pseudallescheria boydii* infection with cutaneous zygomycosis after near drowning. *South Med J* 2004;97:683-7.
- R ichel R, Wilichowski E. Cerebral *Pseudallescheria* mycosis after near-drowning. *Mycoses* 1995;38:473-5.
- Caya JG, Farmer SG, Williams GA, Franson TR, Komorowski RA, Kies JC. Bilateral *Pseudallescheria boydii* endophthalmitis in an immunocompromised patient. *Wis Med J* 1988;87:11-4.
- Walker DH, Adamec T, Krigman M. Disseminated petriellidiosis (allescheriosis). *Arch Pathol Lab Med* 1978;102:158-60.
- Shih LY, Lee N. Disseminated petriellidiosis (allescheriasis) in a patient with refractory acute lymphoblastic leukaemia. *J Clin Pathol* 1984;37:78-82.
- Schiess RJ, Coscia MF, McClellan GA. *Petriellidium boydii* pachymeningitis treated with miconazole and ketoconazole. *Neurosurgery* 1984;14:220-4.

20. Cuenca-Estrella M, Ruiz-Díez B, Martínez-Suárez JV, Monzón A, Rodríguez-Tudela JL. Comparative *in-vitro* activity of voriconazole (UK-109,496) and six other antifungal agents against clinical isolates of *Scedosporium prolificans* and *Scedosporium apiospermum*. *J Antimicrob Chemother* 1999;43:149-51.
21. Meletiadis J, Meis JF, Mouton JW, Rodriguez-Tudela JL, Donnelly JP, Verweij PE; EUROFUNG Network. *In vitro* activities of new and conventional antifungal agents against clinical *Scedosporium* isolates. *Antimicrob Agents Chemother* 2002;46:62-8.
22. Mursch K, Trnovec S, Ratz H, Hammer D, Horré R, Klinghammer A, *et al.* Successful treatment of multiple *Pseudallescheria boydii* brain abscesses and ventriculitis/ependymitis in a 2-year-old child after a near-drowning episode. *Childs Nerv Syst* 2006;22:189-92.
23. Chakraborty A, Workman MR, Bullock PR. *Scedosporium apiospermum* brain abscess treated with surgery and voriconazole. Case report. *J Neurosurg* 2005;103 1 Suppl:83-7.