

Primary Intracranial Dural-Based Ewing Sarcoma/Peripheral Primitive Neuroectodermal Tumor with Extracranial Extension: An Uncommon Case

Sir,

Ewing sarcoma/peripheral primitive neuroectodermal tumor (ES/pPNET) is a malignant small, round cell tumor arising from bone and soft tissue in children and young adults. It can occur at osseous and extrasosseous sites.^[1] Intracranial ES/pPNET is usually metastases from extracranial sites of ES/pPNET. When primary ES/pPNET affects central nervous system (CNS), which is rare, it is usually intraparenchymal located supratentorially or in the spinal cord.^[2] An extraaxial/dural presentation of ES/pPNET mimicking meningioma is extremely rare. We report a case of intracranial ES/pPNET presenting as meningioma in a 22-year-old pregnant female with complaints of a headache.

A 22-year-old primigravida with 37 weeks of pregnancy presented with 1-month history of moderate-to-severe headache and localized scalp swelling in the left parieto-occipital region. On examination, Glasgow Coma Score was E4V5M6 with no obvious motor or sensory deficit. Contrast-enhanced computed tomography (CT) showed an extraaxial hyperdense mass lesion in the left parieto-occipital region with homogeneous contrast enhancement and similar type of lesion in overlying scalp. Significant mass effect in the form of contralateral shift of lateral ventricle was noted [Figure 1]. Radiological features suggested the possibility of meningioma. The patient was taken up for emergency caesarian section followed by left parieto-occipital craniotomy to remove the tumor.

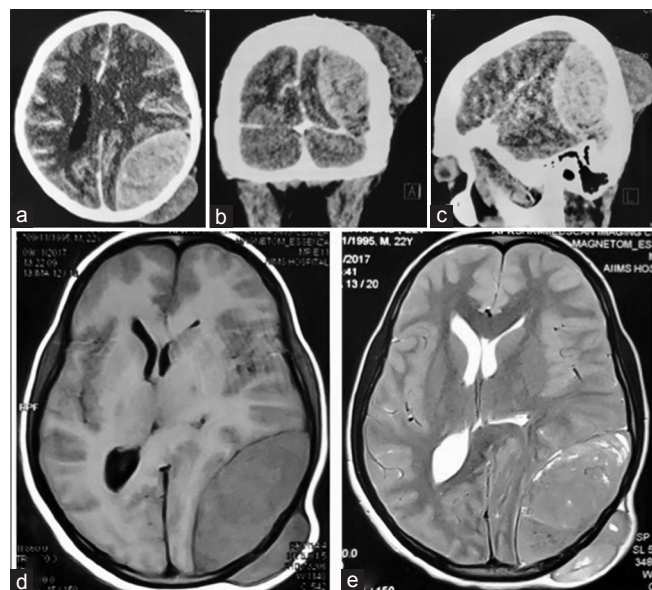


Figure 1: Preoperative contrast computed tomography head showed large left parieto-occipital dural based with extracranial extension with homogenous contrast enhancement (a-c). Tumor was hypointense on T1 weighted and isointense on T2 weighted (d and e)

Scalp tumor followed by intracranial tumor was excised. Intraoperatively, the tumor was a soft reddish highly vascularized mass attached to the dura with scalloping of inner table of overlying bone. Gross total resection of the tumor with the attached dura was done. Tumor attachment to the left transverse sinus was coagulated. Dura repaired with pericranium, and bone flap replaced. Postoperative magnetic resonance imaging showed excision of tumor [Figure 2]. Rest of the course in the hospital was uneventful.

The histopathological analysis showed a cellular tumor with dural invasion. The tumor is arranged in sheets and lobule. The cells were round blue cells with vesicular nucleus, granular chromatin, conspicuous nucleoli, and scant cytoplasm. Perivascular pseudorosettes with geographic area of necrosis were seen. Brisk mitotic activity (30–40/10 high power fields) was noted. Both the intracranial and extracranial tumors showed similar histomorphology. Immunohistochemistry showed diffuse and strong immunopositivity for CD99 (membrane) while negativity for leukocyte common antigen and transferase [Figure 3]. It was diagnosed as ES/pPNET.

Metastatic workup in the form of CT scan of thorax, whole body bone scan and bone marrow biopsy, was done to rule out extracranial primary sites or metastatic deposits, which were all negative. Chemotherapy and radiotherapy were given. The patient improved in her symptoms in follow-up visits. The total follow-up period was 14 months, and she remained asymptomatic in that period.

Primary intracranial ES/pPNET is a recently recognized entity of CNS-PNET. There are about 15 cases in the literature.^[3,4] These tumors clinically present with signs of increased intracranial pressure, headache, vomiting, or seizures. ES and PNET are defined as round cell sarcomas showing varying degrees of neuroectodermal differentiation. The term “ES” is used for tumors with absent or limited neuroectodermal differentiation whereas “PNET” is employed for tumors demonstrating definite neuroectodermal features. “ES/pPNET” best describes this overlapping entity.

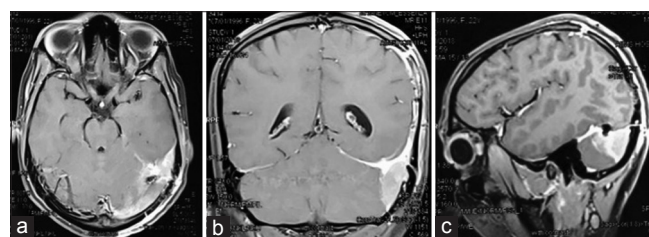


Figure 2: Postoperative contrast magnetic resonance imaging brain showed good excision of tumor with some residual tumor attached to the left transverse sinus region (a-c)

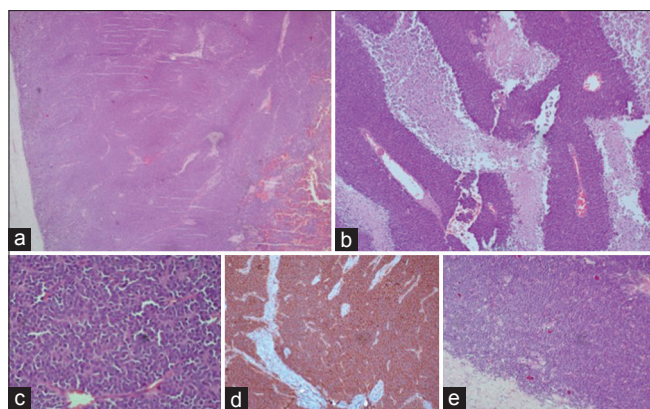


Figure 3: (a) Tumor cells arranged in diffuse sheets (H and E, ×4), (b) perivascular pseudorosettes with geographic areas of necrosis (H and E, ×4), (c) brisk mitotic activity (H and E, ×40), (d) tumor cells show strong and diffuse immunopositivity for CD 99 (membrane), (e) tumor with adhered dura (H and E, ×10)

The central PNET (cPNET) is defined as an embryonal tumor composed of undifferentiated or poorly differentiated neuroepithelial cells displaying divergent differentiation along neuronal, astrocytic, muscular, or melanocytic lines occurring within any region of the CNS other than cerebellum.^[5] It is clinically important to differentiate the two as their clinical presentation, treatment, and prognosis differ variably.

Compared to cPNET, ES/pPNET is relatively well-circumscribed tumors with broad implantation on the dura, which allows gross total resection of the lesion.^[6] pPNETs remain largely localized to the CNS and rarely metastasizes elsewhere while cPNETs involve the cerebrospinal fluid in 10%–30% of cases at the time of diagnosis. The present case also showed a localized tumor attached to dura with no distant metastasis. The long-term disease-free survival is reported in ES/pPNET cases, which is uncommon among patients with intracranial cPNET patient. Immunohistochemistry for CD99 shows strong membranous positivity in 97% of ES/pPNET cases while cPNETs are reported to be negative for CD99.

ES/pPNET is rarely arising as a primary dural-based neoplasm radiologically mimicking meningioma. Meningiomas are the most common dural-based tumor accounting for approximately 20%–30% of all primary intracranial tumors. They are mostly benign cured by surgical resection alone. On the other hand, pPNET is a rare intracranial aggressive tumor, which needs multimodality treatment combining surgery, chemotherapy, and radiotherapy. The distinction of both carries great prognostic and therapeutic significance. Awareness of unusual presentations of ES/pPNET is important for early diagnosis of the tumor and having a high clinical suspicion for this infrequent tumor.

Declaration of patient consent

The authors certify that they have obtained all appropriate patient consent forms. In the form the patient(s) has/have given his/her/their consent for his/her/their images and other clinical information to be reported in the journal. The patients understand that their names and initials will not

be published and due efforts will be made to conceal their identity, but anonymity cannot be guaranteed.

Financial support and sponsorship

Nil.

Conflicts of interest

There are no conflicts of interest.

**Sumit Bansal, Rabi Narayan Sahu,
Pritinanda Mishra¹, Saubhagya Kumar Jena²**

Departments of Neurosurgery, ¹Pathology and Lab Medicine and ²Obstetrics and Gynecology, All India Institute of Medical Sciences, Bhubaneswar, Odisha, India

*Address for correspondence: Dr. Sumit Bansal,
Department of Neurosurgery, All India Institute of Medical Sciences,
Room No. 419, Bhubaneswar - 751 019, Odisha, India.
E-mail: drsumitbansal@gmail.com*

References

1. Choudhury KB, Sharma S, Kothari R, Majumder A. Primary extraosseous intracranial Ewing's sarcoma: Case report and literature review. *Indian J Med Paediatr Oncol* 2011;32:118-21.
2. Dedeurwaerdere F, Giannini C, Sciort R, Rubin BP, Perilongo G, Borghi L, *et al.* Primary peripheral PNET/Ewing's sarcoma of the Dura: A clinicopathologic entity distinct from central PNET. *Mod Pathol* 2002;15:673-8.
3. Amita R, Sandhyamani S, Nair S, Kapilamoorthy TR. Intracranial Ewings sarcoma/peripheral primitive neuroectodermal tumor. *Neurol India* 2014;62:432-3.
4. Kumar V, Singh A, Sharma V, Kumar M. Primary intracranial dural-based Ewing sarcoma/peripheral primitive neuroectodermal tumor mimicking a meningioma: A rare tumor with review of literature. *Asian J Neurosurg* 2017;12:351-7.
5. Louis DN, Ohgaki H, Wiestler OD, Cavenee WK. WHO Classification of Tumours of the Central Nervous System. 4th ed. Lyon: IARC; 2007. p. 141-6.
6. Schmidt D, Herrmann C, Jürgens H, Harms D. Malignant peripheral neuroectodermal tumor and its necessary distinction from Ewing's sarcoma. A report from the Kiel pediatric tumor registry. *Cancer* 1991;68:2251-9.

This is an open access journal, and articles are distributed under the terms of the Creative Commons Attribution-NonCommercial-ShareAlike 4.0 License, which allows others to remix, tweak, and build upon the work non-commercially, as long as appropriate credit is given and the new creations are licensed under the identical terms.

Access this article online	
Quick Response Code: 	Website: www.asianjns.org
	DOI: 10.4103/ajns.AJNS_22_19

How to cite this article: Bansal S, Sahu RN, Mishra P, Jena SK. Primary intracranial dural-based ewing sarcoma/peripheral primitive neuroectodermal tumor with extracranial extension: An uncommon case. *Asian J Neurosurg* 2019;14:1052-3.

© 2019 Asian Journal of Neurosurgery | Published by Wolters Kluwer - Medknow