

# Surgical Training for the Management of Intraoperative Aneurysm Rupture Using a Three-Dimensional Artificial Model

## Abstract

**Background:** Intraoperative aneurysm rupture (IAR) is one of the most dreaded complications of microsurgical cerebral aneurysm clipping. The surgical result is directly affected by whether an operator can control IAR. However, the development of endovascular treatment has decreased the probability of exposure to this situation for neurosurgical residents. Therefore, neurovascular surgeons must develop the skills and mental attitude to deal with IAR through off-the-job training, without conducting actual operations. **Materials and Methods:** We have developed a tabletop training system using three-dimensional artificial modeling that can be used for daily clinical practice.

**Results and Conclusions:** Our model is useful for training because of its low cost, reusability, and ease of preparation and practice.

**Keywords:** Intraoperative aneurysm rupture, surgical training, three-dimensional artificial model

**Kosuke Kumagai,  
Kentaro Mori,  
Satoru Takeuchi,  
Kojiro Wada**

*Department of Neurosurgery,  
National Defense Medical  
College, Tokorozawa, Saitama,  
Japan*

## Introduction

Intraoperative aneurysm rupture (IAR) is one of the most dreaded complications of microsurgical cerebral aneurysm clipping. If the surgeon cannot control the bleeding appropriately, IAR is more likely to cause undesirable results.<sup>[1-10]</sup> However, the development of endovascular treatment has decreased the exposure of neurosurgical residents to this situation. Therefore, neurosurgical residents must develop the skills and mental attitude through off-the-job training, without conducting actual operations. Several models with three-dimensional (3D) modeling have been developed, and they are useful for improving the surgical techniques of neurosurgeons.<sup>[11-15]</sup> However, there are a limited number of reports of models for training for the management of IAR. Aboud *et al.*<sup>[16]</sup> reported the use of a cadaver model, which is remarkably similar to the real situation and was very available. However, it requires a human cadaver, specific materials and facilities, and incurs considerable costs. Hence, we have developed a tabletop training system for the management of IAR using 3D modeling and materials used in daily clinical practice. Our low-cost model is useful for off-the-job

training and is both reusable and easy to prepare and practice.

## Materials and Methods

Initially, we prepared the following: the cerebral hemispheric brain retractable soft model with the bone model (Kezlex®; Ono and Co., Ltd., Tokyo, Japan), the cerebral aneurysm model (Kezlex®; Ono and Co., Ltd., Tokyo, Japan), a suction unit, a large syringe, aneurysm clips and applier, red ink, and an operating microscope [Figure 1].

Subsequently, a pinhole was made using an 18-G needle at the aneurysmal wall by an assistant so that a trainee could not recognize the location of the hole. The aneurysm model was set in the cerebral hemispheric brain retractable soft model with bone model through a hole at the bottom. The flush system was made using the large syringe containing red ink in tap water [Figure 1]. The total cost of this system was approximately 1000 dollars.

Following the setup, training was conducted with the use of an operating microscope. When the trainee was peeling around the aneurysm, he or she encountered the scene of aneurysm rupture once the assistant flushed the artificial blood [Figure 2]. First, point suction was performed calmly. The larger suction tubes were used for trying to clean the operative field. Next, a tentative

### Address for correspondence:

*Dr. Kosuke Kumagai,  
Department of Neurosurgery,  
National Defense Medical  
College, 3-2 Namiki,  
Tokorozawa, Saitama 359-8513,  
Japan.  
E-mail: kumagaikousuke0714@  
gmail.com*

Video Available on:  
[www.asianjns.org](http://www.asianjns.org)

### Access this article online

Website: [www.asianjns.org](http://www.asianjns.org)

DOI: 10.4103/ajns.AJNS\_197\_18

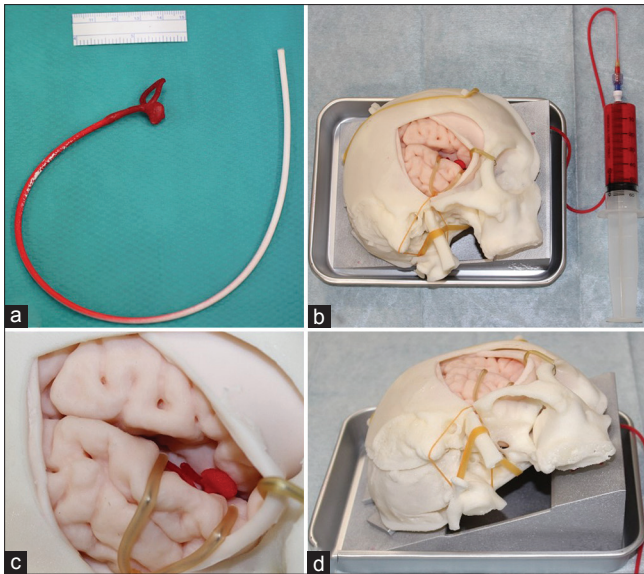
### Quick Response Code:



**How to cite this article:** Kumagai K, Mori K, Takeuchi S, Wada K. Surgical training for the management of intraoperative aneurysm rupture using a three-dimensional artificial model. *Asian J Neurosurg* 2019;14:172-4.

This is an open access journal, and articles are distributed under the terms of the Creative Commons Attribution-NonCommercial-ShareAlike 4.0 License, which allows others to remix, tweak, and build upon the work non-commercially, as long as appropriate credit is given and the new creations are licensed under the identical terms.

For reprints contact: [reprints@medknow.com](mailto:reprints@medknow.com)



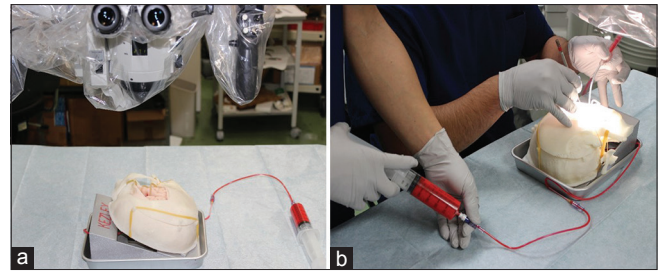
**Figure 1: The preparations and the whole system. (a) The cerebral aneurysm model. (b) The whole system containing the right cerebral hemispheric brain model with the bone model, the cerebral aneurysm model, and a syringe. (c) The enlargement view. (d) The inferior oblique view**

clipping of the aneurysm or temporary clipping of M1 was performed to stop the bleed temporarily. Because this model was a closed model, the assistant had to control the flush. Once the aneurysm could be viewed as much as possible, a permanent clip was applied across the neck of the aneurysm. If needed, another permanent clip was applied additionally to the aneurysm. Finally, the training was completed once the surroundings of the aneurysm were checked [Figure 3, Video 1].

## Discussion

Microsurgical cerebral aneurysm clipping is a standard surgical treatment performed by neurosurgeons. IAR is the most serious and stressful complication encountered during clipping surgery. A recent study demonstrated that IAR occurs in a wide range of all cranial aneurysm surgeries (7%–40%).<sup>[1-10]</sup> Because the inappropriate management of this critical situation may lead to the most dreaded complications, the surgeon's abundant experience, technical skills, and mental attitude are needed to handle this situation.<sup>[1-10]</sup>

There are three important steps in the management of IAR.<sup>[17,18]</sup> The first step is to ensure the operative field. The rupture point should be identified using one or two large and strong suctions. It is important not to use the suctions blindly but instead perform the point suction calmly, despite the visual field being restricted with overflowing blood. Because this model simulates the IAR using artificial blood and a pressurized bag, the trainee can experience the first step. The second step is to achieve hemostasis. Tentative or temporary clipping is the typical way to achieve hemostasis. Tentative clipping has a



**Figure 2: The training scene. (a) Before the training. (b) During the training**

lower tendency to cause brain ischemia than a temporary clipping, which temporarily interrupts the parent artery. Depending on the situation, tentative clipping, if possible, is preferable over temporary clipping. In addition to an aneurysm, this model includes a trunk of the middle cerebral artery made from silicon so that the trainee can experience both a temporary clipping and a tentative clipping. The third step is to aim for the final form. The aneurysm is carefully separated from the surrounding tissue after achieving hemostasis using tentative or temporary clipping. Once the aneurysm is identified to the maximum extent, a permanent clip should be applied across the neck of the aneurysm. The trainee can experience this final step of neck clipping.

Advantages of our model include that it is reusable, low cost, and no need for large-scale preparations or special facilities. These advantages ensure this model is suitable for off-the-job training. In addition, the trainee can practice in a simulated situation, resembling the real situation, because he or she is unaware of the rupture point and the artificial blood is pooled in the Sylvian fissure.

Disadvantages of this model include that it is a closed circuit system rather than a perfusion system. A different point of the model may be destroyed if the assistant creates too much flush of the artificial blood once the clipping has been performed. Therefore, the assistant must control the flush while assessing the situation. Moreover, it is better to put the aneurysm model in a cerebral hemispheric brain model directly, not in a silicone cup, as this is more practical.

## Conclusions

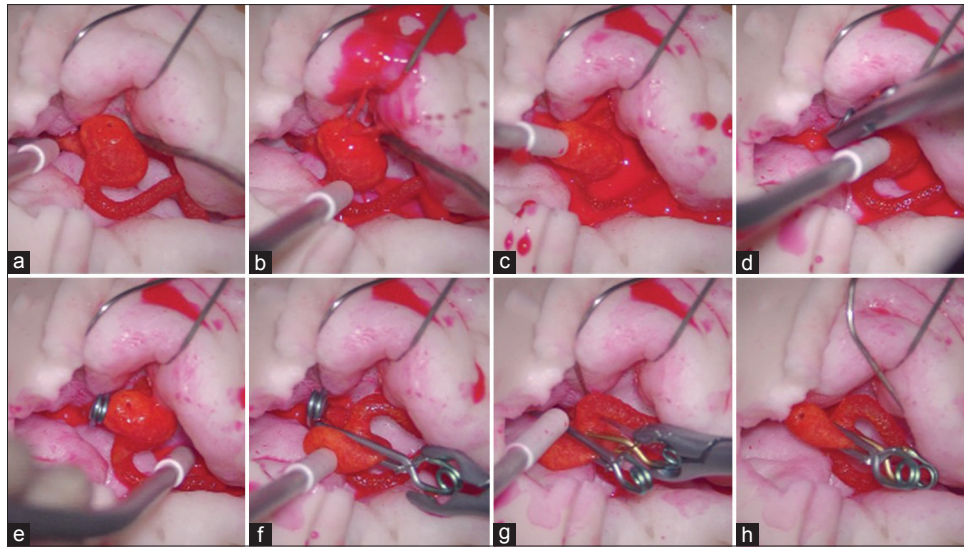
We have developed a tabletop training system for the management of IAR using 3D modeling. Our model is useful for the training of neurosurgical residents because of its low cost, reusability, and ease of preparation and practice. However, this model could be improved to ensure it is closer to the real situation.

## Financial support and sponsorship

Nil.

## Conflicts of interest

There are no conflicts of interest.



**Figure 3:** A series of the training session. (a) Peeling around the aneurysm. (b) Encountering the aneurysm rupture. (c) Performing the point suction. (d) Performing temporary clipping. (e) Identifying the full view of the aneurysm after achieving hemostasis. (f) Performing the neck clipping. (g) Adding another permanent clip to the aneurysm. (h) Checking the surroundings of the aneurysm

## References

1. Madhugiri VS, Ambekar S, Pandey P, Guthikonda B, Bollam P, Brown B, *et al.* The pterional and suprabrow approaches for aneurysm surgery: A systematic review of intraoperative rupture rates in 9488 aneurysms. *World Neurosurg* 2013;80:836-44.
2. Batjer H, Samson D. Intraoperative aneurysmal rupture: Incidence, outcome, and suggestions for surgical management. *Neurosurgery* 1986;18:701-7.
3. Elijevich L, Higashida RT, Lawton MT, Duckwiler G, Giannotta S, Johnston SC, *et al.* Predictors and outcomes of intraoperative rupture in patients treated for ruptured intracranial aneurysms: The CARAT study. *Stroke* 2008;39:1501-6.
4. Fridriksson S, Säveland H, Jakobsson KE, Edner G, Zygmunt S, Brandt L, *et al.* Intraoperative complications in aneurysm surgery: A prospective national study. *J Neurosurg* 2002;96:515-22.
5. Leipzig TJ, Morgan J, Horner TG, Payner T, Redelman K, Johnson CS, *et al.* Analysis of intraoperative rupture in the surgical treatment of 1694 saccular aneurysms. *Neurosurgery* 2005;56:455-68.
6. Sandalcioglu IE, Schoch B, Regel JP, Wanke I, Gasser T, Forsting M, *et al.* Does intraoperative aneurysm rupture influence outcome? Analysis of 169 patients. *Clin Neurol Neurosurg* 2004;106:88-92.
7. Schramm J, Cedzich C. Outcome and management of intraoperative aneurysm rupture. *Surg Neurol* 1993;40:26-30.
8. van Lindert EJ, Böcher-Schwarz HG, Perneckzy A. The influence of surgical experience on the rate of intraoperative aneurysm rupture and its impact on aneurysm treatment outcome. *Surg Neurol* 2001;56:151-6.
9. Hsu CE, Lin TK, Lee MH, Lee ST, Chang CN, Lin CL, *et al.* The impact of surgical experience on major intraoperative aneurysm rupture and their consequences on outcome: A multivariate analysis of 538 microsurgical clipping cases. *PLoS One* 2016;11:e0151805.
10. Wong JM, Ziewacz JE, Ho AL, Panchmatia JR, Kim AH, Bader AM, *et al.* Patterns in neurosurgical adverse events: Open cerebrovascular neurosurgery. *Neurosurg Focus* 2012;33:E15.
11. Kimura T, Morita A, Nishimura K, Aiyama H, Itoh H, Fukaya S, *et al.* Simulation of and training for cerebral aneurysm clipping with 3-dimensional models. *Neurosurgery* 2009;65:719-25.
12. D'Urso PS, Thompson RG, Atkinson RL, Weidmann MJ, Redmond MJ, Hall BI, *et al.* Cerebrovascular biomodelling: A technical note. *Surg Neurol* 1999;52:490-500.
13. Wurm G, Tomancok B, Pogady P, Holl K, Trenkler J. Cerebrovascular stereolithographic biomodelling for aneurysm surgery. Technical note. *J Neurosurg* 2004;100:139-45.
14. Mashiko T, Otani K, Kawano R, Konno T, Kaneko N, Ito Y, *et al.* Development of three-dimensional hollow elastic model for cerebral aneurysm clipping simulation enabling rapid and low cost prototyping. *World Neurosurg* 2015;83:351-61.
15. Benet A, Plata-Bello J, Abila AA, Acevedo-Bolton G, Saloner D, Lawton MT, *et al.* Implantation of 3D-printed patient-specific aneurysm models into cadaveric specimens: A new training paradigm to allow for improvements in cerebrovascular surgery and research. *Biomed Res Int* 2015;2015:939387.
16. Aboud E, Aboud G, Al-Mefty O, Aboud T, Rammos S, Abolfotoh M, *et al.* "Live cadavers" for training in the management of intraoperative aneurysmal rupture. *J Neurosurg* 2015;123:1339-46.
17. Kato Y, Sano H, Okuma I, Akashi K, Hayakawa M, Yoneda M, *et al.* Pitfalls in aneurysm surgery in acute stages. *Neurol Res* 1997;19:17-24.
18. Sano H, Kato Y, Abe M, Kasama A, Kanno T. Utility and problems of temporary clips and tentative clips. *Surg Cerebral Stroke* 1991;19:595-7.