

Spinal Intradural Extramedullary Bizarre Parosteal Osteochondromatous Proliferation of Bone (Nora's Lesion): First Case Report

Abstract

Bizarre parosteal proliferation of bone (Nora's lesion) is a known bony lesion that affects mainly hands and feet. In this article, we present the first case of spinal intradural extramedullary Nora's lesion along with the management. Radiologically, the tumor was initially diagnosed as a meningioma. However, histopathological analysis confirmed bizarre parosteal proliferation of bone. It was successfully managed by surgical resection followed by physical rehabilitation.

Keywords: Bizarre parosteal proliferation of bone, intradural tumors, Nora's lesion, spinal cord compression, spinal tumors

Introduction

Nora's lesion or bizarre parosteal osteochondromatous proliferation (BPOP) of bone is one of several described types of osteochondromas. It is an exophytic bony outgrowth consisting of bone, cartilage, and fibrous tissue that typically has continuation with the underlying periosteum.^[1,2] In addition to Nora's lesion, osteochondromas include solitary osteochondromas, postirradiation osteochondroma, multiple osteochondroma, epiphyseal osteochondroma, subungual exostosis, and para-articular osteochondroma.^[3] It was first described in small bones of hands and feet by Nora *et al.* in 1983 followed by several cases reports.^[2,4,5] There are more than 160 reported cases of BPOP mostly in the long bone and other parts of the bony skeleton.^[2,4] In this report, we present the first case of spinal intradural extramedullary Nora's lesion.

Case Report

A 61-year-old female, with an unremarkable past medical history, presented to our emergency department complaining of progressive right lower limb weakness started 15 days before presentation associated with back pain around the right mid-thoracic region. The back pain started 4 months before presentation. No lower limb pain was reported. There was a negative history of fever, trauma, corticoid

use, or malignancy. There was no urinary/fecal incontinence or retention.

On physical examination of the lower limbs, she was found to have a mild hypertonic muscular tone bilaterally. The power of the right and left lower limbs was 3/5 and 5/5, respectively. Patellar and Achilles tendon reflexes were brisk 3/4 bilaterally, Babinski sign was equivocal, and gait was unsteady. Sensory examination showed diminished light touch and pinprick sensations on and below the T4 level. Diminished proprioception marked mainly at the right side. Rectal examination showed preserved anal tone. The upper limbs' neurologic examination was normal.

Investigations

Laboratory analyses for complete blood count, electrolytes, erythrocyte sedimentation rate, and C-reactive protein were within normal range.

Gadolinium-enhanced magnetic resonance imaging (MRI) of the spine showed homogeneously enhanced oval intradural extramedullary lesion at the thoracic level measuring 12 mm × 14 mm located at the T4–T5 level. The lesion is exerting a significant local mass effect, causing marked cord compression. The lesion was hypointense on T2-weighted image [Figure 1]. On computed tomography scan, the lesion showed calcifications associated with osteosclerosis of the right lamina and pedicle [Figure 2].

**Alkhayri Abdu^{1,2},
Bugdadi
Abdulgadir^{3,4},
Alsalmi Sultan^{5,6},
Andre Arthur^{3,7}**

¹Department of Neurosurgery, Faculty of Medicine, Paris Descartes University,

³Department of Neurosurgery, Faculty of Medicine, Sorbonne University, ⁷Department of Neurosurgery, Pitié-Salpêtrière University Hospital, Paris,

⁵Department of Neurosurgery, Amiens University Medical Center, Amiens, France,

²Department of Neurosurgery, King Faisal Medical City, Abha, ⁴Department of

Surgery, Faculty of Medicine, Umm Al-Qura University, Makkah Al-Mukarramah,

⁶Department of Neurosurgery, Imam Abdulrahman Bin Faisal University, Dammam, Saudi Arabia

Address for correspondence:

Dr. Alkhayri Abdu,
Department of Neurosurgery,
Pitié-Salpêtrière University
Hospital, Babinski Building,
47-83, Hospital Boulevard,
Paris 75013, France.
E-mail: drabduma@hotmail.com

Access this article online

Website: www.asianjns.org

DOI: 10.4103/ajns.AJNS_163_18

Quick Response Code:



How to cite this article: Abdu A, Abdulgadir B, Sultan A, Arthur A. Spinal intradural extramedullary bizarre parosteal osteochondromatous proliferation of bone (Nora's Lesion): First case report. *Asian J Neurosurg* 2019;14:304-6.

This is an open access journal, and articles are distributed under the terms of the Creative Commons Attribution-NonCommercial-ShareAlike 4.0 License, which allows others to remix, tweak, and build upon the work non-commercially, as long as appropriate credit is given and the new creations are licensed under the identical terms.

For reprints contact: reprints@medknow.com

Differential diagnosis of the lesion included mainly a calcified meningioma followed by other primary or secondary spinal tumors. Less likely differentials were infectious or inflammatory processes.

Operative management

The patient was managed operatively through a laminectomy at the level of T4 and T5. The paraspinal muscles and spinal ligaments were intact. However, the spinous processes and the right T4 lamina were looking abnormal. The outer dural layer was attached to the lamina. However, the dura was easily detached from the lamina and found intact after the laminectomy was done. The dura was opened in a midline longitudinal fashion. Once opened, a white, nonhypervascular, hard tumor was seen. It had stony consistency with calcifications forming a hard shell-like structure. The tumor was attached to the dura and nerve root [Figure 3]. With careful dissection under the microscope, we were able to remove the tumor in a piecemeal fashion [Figure 4]. After complete removal of the tumor, dural, subcutaneous tissue, and skin closures were done in the routine fashion.

Histopathology

Histopathological analysis of the tumor showed a disorganized proliferation of fibrous, cartilaginous, and bony tissues. At some locations, the cartilaginous component showed irregular groups of enlarged binucleated and atypical chondrocytes. Immunodetections with anti-MDM and Ki67 antibodies showed no immunolabeling. The Ki67 was about 1%. The histopathological features of the tumor were consistent with a BPOP of bone (Nora's lesion).

Postoperative course, outcome, and follow-up

Corticosteroid was given. No central nervous system infection or cerebrospinal fluid leakage occurred. Rehabilitation started 2 weeks after the operation. The patient was allowed to do walking exercises. At the 6-month follow-up, her right lower limb showed a significant improvement in power, grade of about + 4/5. She was able to walk without any difficulty. No clinical or radiological signs of recurrence were noted. Follow-up MRI of the spine showed completely resected tumor without signs of recurrence [Figure 5].

Discussion

Nora's lesion is a formed by heterotopic ossification.^[1] It is an exophytic bony outgrowth consisting of bone, cartilage, and fibrous tissue that typically has continuation with the underlying periosteum.^[1,2] In our case, although the tumor was attached to the dura, which in turn was attached to the lamina, the tumor itself was completely intradural with no apparent attachment to the lamina.

In the literature, there is one reported case of spinal intradural extramedullary chondroma and around 20 cases

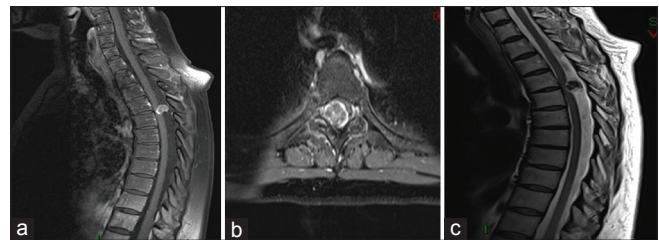


Figure 1: (a) Sagittal-contrasted enhanced T1-weighted magnetic resonance imaging showing strongly enhanced intradural extramedullary lesion at the T4–T5 level. (b) Axial view contrast-enhanced T1-weighted magnetic resonance image. (c) T2-weighted magnetic resonance image showing a hypointense mass with marked cord compression

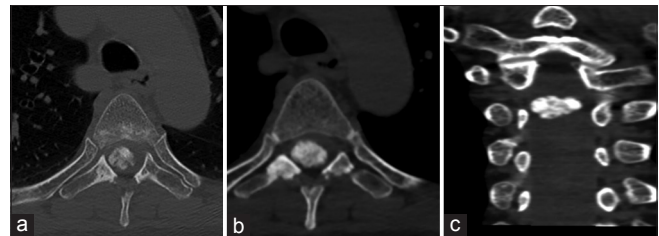


Figure 2: Computed tomography scan images. (a) Axial view of T4 vertebra showing a calcified lesion and osteosclerosis mainly of the right lamina and pedicle. (b) A lower cut of T4 vertebra showing increased hyperdensity. (c) Coronal view

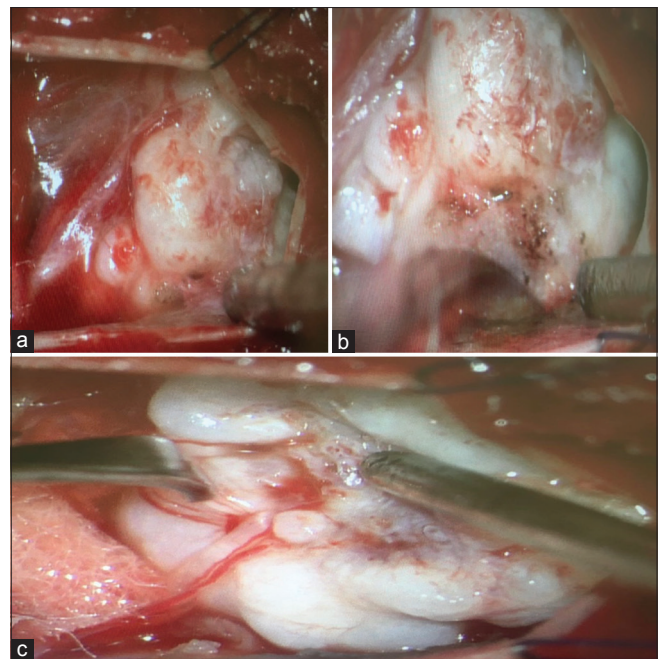


Figure 3: Operative images after opening of the dura. (a) Tumor adherent to the dura. (b) Detachment of the tumor from dura after dissection. (c) Tumor attachment to nerve root

of cranial intradural chondroma.^[6,7] Histopathologically, Nora's lesion – in contrast to osteochondroma – has less organized microscopic appearance and nuclear atypia with atypical chondrocytes.^[8] It may present hypercellularity and mitotic activity.^[8] To our knowledge, this is the first reported case of spinal intradural extramedullary BPOP of bone (Nora's lesion).

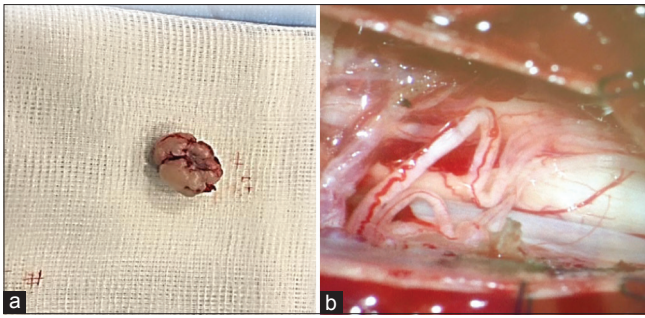


Figure 4: (a) Gross pathology image showing well-circumscribed and pedunculated mass. (b) Postoperative view after complete resection of the tumor

In bony lesions, Nora's disease has a tendency to recur locally with no metastases and almost no malignant transformation was reported.^[1,2,4] The initial recurrence rate is up to 51% after the first resection and 22% after the second one.^[5,9] Recurrence is usually within the first 2 years.^[5,9] We are managing the patient postoperatively as if the tumor has similar behavior. However, whether this hypothesis is true or not will be determined with long-term follow-up of the patient and will be reported in future communications.

Conclusion

This is a first case report of spinal intradural extramedullary bizarre parosteal proliferation of bone (Nora's lesion). The patient was successfully managed with surgical resection and physical rehabilitation. Close follow-up is being done for possible recurrence based on known tumor behavior in the bony skeleton.

Declaration of patient consent

The authors certify that they have obtained all appropriate patient consent forms. In the form the patient(s) has/have given his/her/their consent for his/her/their images and other clinical information to be reported in the journal. The patients understand that their names and initials will not be published and due efforts will be made to conceal their identity, but anonymity cannot be guaranteed.

Financial support and sponsorship

Nil.

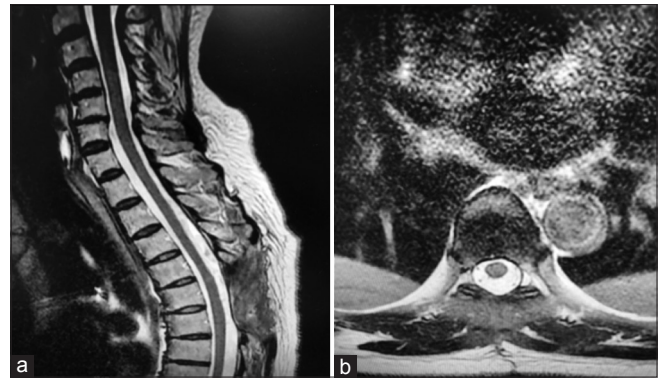


Figure 5: Six-month follow-up magnetic resonance image of the spine showing complete removal of the tumor without signs of recurrence. (a) Sagittal view. (b) Axial view at the T4-T5 level

Conflicts of interest

There are no conflicts of interest.

References

1. Al-Nafussi A. Tumor Diagnosis 2Ed: Practical approach and pattern analysis. London: CRC Press; 2005.
2. Gruber G, Giessauf C, Leithner A, Zacherl M, Clar H, Bodo K, et al. Bizarre parosteal osteochondromatous proliferation (Nora lesion): A report of 3 cases and a review of the literature. *Can J Surg* 2008;51:486-9.
3. Vigorita VJ. Orthopedic Pathology. 2nd ed. Philadelphia: Lippincott Williams and Wilkins; 2008.
4. Meneses MF, Unni KK, Swee RG. Bizarre parosteal osteochondromatous proliferation of bone (Nora's lesion). *Am J Surg Pathol* 1993;17:691-7.
5. Nora FE, Dahlin DC, Beabout JW. Bizarre parosteal osteochondromatous proliferations of the hands and feet. *Am J Surg Pathol* 1983;7:245-50.
6. Hori Y, Seki M, Tsujio T, Hoshino M, Mandai K, Nakamura H, et al. Intradural chondroma in the cervical spine: Case report. *J Neurosurg Spine* 2017;26:257-9.
7. Abeloos L, Maris C, Salmon I, Balériaux D, Sadeghi N, Lefranc F, et al. Chondroma of the dural convexity: A case report and literature review. *Neuropathology* 2012;32:306-10.
8. Bui MM, Dodd LG. Atlas of soft tissue and bone pathology: With histologic, cytologic, and radiologic correlations. New York: Demos Medical Publishing; 2014.
9. Mahajan S, Chandra R, Mohan Lal Y. "Nora lesion" – Bizarre parosteal osteochondromatous proliferation. *J Clin Orthop Trauma* 2012;3:119-21.