

# Endoscopic versus Microscopic Pituitary Adenoma Surgery: An Institutional Experience

## Abstract

**Aim:** The aim of this study was to compare the efficacy of endoscopic versus microscopic excision of pituitary adenoma, and to evaluate the merits and demerits of each approach. **Materials and Methods:** Prospective data were collected and patients were surgically treated for pituitary adenoma at SMS Hospital, Jaipur, Rajasthan, India. Patients consent was obtained. Age, sex, presenting symptoms, length of hospital stay, pre- and post-operative hormone status, extent of resections of tumors, and intra- and post-operative complication were noted. **Results:** A total of thirty patients with pituitary adenoma were operated transsphenoidally. Seventeen patients were operated by endonasal endoscopic transsphenoidal surgery and 13 patients were operated by microscopic transsphenoidal surgery. In an endoscopic group, complete tumor excision was achieved in 11 (64.71%) patients, and in microscopic group, it was achieved in 6 (46.15%) patients. In endoscopic group, mean operative time was  $111.29 \pm 21.95$  min (ranged 80–135 min), and in microscopic group, it was  $134.38 \pm 8.33$  min (ranged 120–145 min). In endoscopic group, mean blood loss was  $124.41 \pm 39.64$  ml (60–190 ml), and in microscopic group, it was  $174.62 \pm 37.99$  (100–220 ml). Postoperative sinusitis was present in 1 (5.88%) patient in endoscopic group and in 2 (15.38%) patients in microscopic group. **Conclusion:** Endoscopic approach provides a wide surgical field and broad lateral vision making easier distinction of tumor tissues. Thus, there is less blood loss, greater extent of tumor removal and it had less operative time, less postoperative complication, and early discharge from the hospital.

**Keywords:** Endoscopic, microscopic, pituitary adenoma, transsphenoidal surgery

## Introduction

Pituitary adenoma is the third most common intracranial tumor in surgical practice, accounting for approximately 10%–25% of all intracranial tumors.<sup>[1]</sup> Recent epidemiological data suggest that clinically apparent pituitary adenomas have a prevalence of 1/1000 in the general population.<sup>[2]</sup> Although only very rarely malignant, pituitary tumors may cause significant morbidity in affected patients. Sir Victor Horsley was the first surgeon to operate pituitary tumor,<sup>[3]</sup> followed by Schloffer's<sup>[4]</sup> transnasal transsphenoidal route and Cushing's<sup>[5]</sup> sublabial transseptal route. Hirsch<sup>[6]</sup> first introduced the operative microscope. Subsequently, Jankowski *et al.*<sup>[7]</sup> performed the first endoscopic pituitary surgery to start a new era. Since then there has been a transition from microscopic approach to endoscopic assisted microscopic approach to endoscopic approach.

This is an open access journal, and articles are distributed under the terms of the Creative Commons Attribution-NonCommercial-ShareAlike 4.0 License, which allows others to remix, tweak, and build upon the work non-commercially, as long as appropriate credit is given and the new creations are licensed under the identical terms.

For reprints contact: reprints@medknow.com

Previous studies are either retrospective or had compared endoscopic with endoscope-assisted microscopic approach.<sup>[8]</sup> Only few prospective studies are reported in the literature comparing endoscopic endonasal transsphenoidal approach with microscopic transsphenoidal pituitary adenoma surgery.

We have done prospective comparison study in our institution between endonasal endoscopic transsphenoidal surgery and microscopic transsphenoidal surgery.

## Materials and Methods

Our study included thirty cases of pituitary adenoma, operated in SMS Hospital, Jaipur, Rajasthan, India. Seventeen cases underwent endonasal endoscopic transsphenoidal surgery whereas remaining 13 cases were operated using the microscopic transsphenoidal surgery.

Inclusion criteria are:

- Sellar and suprasellar pituitary adenoma

**How to cite this article:** Prajapati HP, Jain SK, Sinha VD. Endoscopic versus microscopic pituitary adenoma surgery: An institutional experience. *Asian J Neurosurg* 2018;13:217-21.

**Hanuman Prasad Prajapati, Shashi Kant Jain, Virendra D. Sinha**

Department of Neurosurgery, SMS Medical College and Hospital, Jaipur, Rajasthan, India

**Address for correspondence:**  
Dr. Hanuman Prasad Prajapati,  
Department of Neurosurgery,  
SMS Medical College and  
Hospital, Jaipur, Rajasthan,  
India.  
E-mail: pushpa84.dhp@gmail.com

Access this article online

Website: www.asianjns.org

DOI: 10.4103/ajns.AJNS\_160\_16

Quick Response Code:



- Functioning and nonfunctioning pituitary adenoma
- Solid and cystic pituitary adenoma.

Exclusion criteria are:

- Sellar tumor with large parasellar or retrosellar extension.

Full neurological examination including motor, sensory, and cranial nerve examination was performed. Routine blood examination and basic hormonal profile were performed. Magnetic resonance imaging (MRI) brain and computed tomography (CT) of sella and paranasal sinus were performed for all cases. All patients were provided a uniform postoperative care.

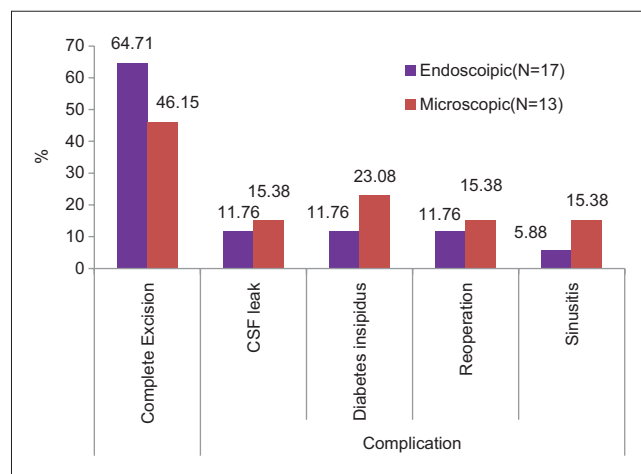


Figure 1: Postoperative complication comparison

Both surgeries were performed under general anesthesia with orotracheal intubation. We used 4 mm diameter sinonasal rigid endoscope, 0° and 30°. The nostrils were decongested. We approach through middle meatus and identified the sphenoid rostrum. Sphenoidectomy was done by using Kerrison Rongeurs. The anterior wall of the sella was identified and opened. The dura was opened with a cruciate incision. Under direct visualization, the tumor was removed first from posterior part and then from anterior part using curette. Sella was inspected for residual tumor with a 30° endoscope. After complete removal of tumor, there is fall of arachnoid in the sellar cavity. Hemostasis done. Sphenoid sinus is packed with fat and sealed with fibrin glue. The nasal packing was done with merocel at the level of middle meatus. The packing was removed after 48 h. Lumber drain was inserted in patients having arachnoid rupture intraoperatively and removed in 48–72 h after surgery.

Microscopic surgery was similar to endoscopic surgery, except that it requires Hardy’s speculum and was done under visualization with a microscope instead of endoscope.

The hormonal profile, visual function evaluation, MRI, and CT scanning were repeated immediately and after 1 month of surgery and were compared with preoperative findings.

### Statistical analysis

Statistical analysis was performed with the SPSS, trial version 20 for Windows statistical software package (SPSS Inc., Chicago, IL, USA). The categorical data were presented

Table 1: Pre operative and intra operative Characteristics of the study Population

	Endoscopic (N=17)	Microscopic (N=11)	Test value	P LS
<b>Preoperative</b>				
Age (mean±SD)	41.06±11.755 (24-60yrs)	41.91±13.232 (16-60)	-0.178*	0.86NS
Duration in months (mean±SD)	30.26±29.33 (15 days-8yrs)	21.3±25.03 (1m-5 yrs)	0.807*	0.42NS
<b>Intra operative</b>				
Complete Excision (no %)	11 (64.71)	6 (54.55)	0.020 with 1 df;**	0.887NS
Operative time in Hrs.(mean±SD)	1.85±0.37 (1.3-2.25hrs)	2.25±0.13 (2-2.4hrs)	-3.432*	0.002S
Blood loss ml (mean±SD)	124.41±39.64 (60-190ml)	177.27±40.023 (60-220ml)	-3.433*	0.002S

\*Unpaired t test, \*\* Chi square Test, LS – Level of significance; df – Degree of freedom; NS – Not significant; S – Significant; SD – standard deviation

Table 2: Postoperative complication among the groups

	Endoscopic (N=17)	Microscopic (N=11)	Test value	P LS
CSF leak (no %)	2 (11.76)	2 (18.18)	0.006 with 1 df	0.937NS*
Diabetes insipidus (no %)	2 (11.76)	3 (27.27)	0.293 with 1 df	0.58NS*
Reoperation (no %)	2 (11.76)	2 (18.18)	0.006 with 1 df	0.937NS*
Sinusitis (no %)	1 (5.88)	2 (18.18)	0.162 with 1 df	0.68NS*
Vision deterioration (no %)	0	0	NA	
Endocrinal deterioration (no %)	0	0	NA	
Hospital stay (days) mean±SD	9.12±2.619 (5-12 days)	10.09±2.166 (6-14 Days)	-1.02	0.32NS**

\*Chi square Test, \*\*Unpaired t test, LS – Level of significance; df – Degree of freedom; NS – Dot significant; S – Significant; SD – Standard deviation; CSF – Cerebrospinal fluid; NA – Not available

as numbers (percentage) and were compared [Table 2] among groups using Chi-square test. Groups were compared for demographic data were presented as mean and standard deviation and were compared using by Student's *t*-test applying to find out the most significant groups among all the groups.  $P < 0.05$  was considered statistically significant.

## Results

There were 19 male patients and 11 female patients. The mean age of the patients in endoscopic group was  $41.06 \pm 11.76$  years (ranged 24–60 years), and in microscopic group, it was  $43.92 \pm 13.20$  years (ranged 16–60 years). Seventeen (56.66%) patients had nonfunctioning pituitary adenoma and 13 (43.34%) patients had a functioning pituitary adenoma. Among functioning pituitary adenoma 7 (53.84%) patients had acromegaly and 5 (38.46%) patients had prolactinoma and 1 (7.70%) patient had Cushing syndrome. The most common presenting symptom was a headache and second most common symptom was loss of vision. The mean duration of symptoms in endoscopic group was  $30.26 \pm 29.23$  months (ranged from 15 days to 8 years), and in microscopic group, it was  $17.58 \pm 22.94$  months (ranged from 1 month to 5 years).

Complete tumor excision was achieved in 11 (64.71%) patients in endoscopic group and in 6 (46.15%) patients in microscopic group (Chi-square test,  $P = 0.64$ , statistically not significant).

In endoscopic group, mean operative time was  $111 \pm 0.37$  min (ranged 80–135 min). In microscopic group mean operative time was  $134.40 \pm 0.13$  min (ranged 120–145 min) (unpaired *t*-test,  $P = 0.001$ , statistically significant).

In endoscopic group, mean blood loss was  $124.41 \pm 39.64$  ml (ranged 60–190 ml), and in microscopic group, it was  $174.62 \pm 37.99$  ml (ranged 100–220 ml) (unpaired test,  $P = 0.002$ , statistically significant).

Postoperative complication was present in both endoscopic and microscopic groups. Slightly higher percentage of complication such as diabetes insipidus (23.08% vs. 11.76%), cerebrospinal fluid (CSF) leak and reoperation (15.38% vs. 11.76%), and sinusitis (15.38% vs. 5.88%) was observed in microscopic group as compared to endoscopic group. Reoperation was performed one for postoperative hematoma and one for CSF leak in both groups.

All the patients after surgery had improvement in a headache and vision in both groups. There was no deterioration of endocrinal function in both groups.

In endoscopic group, mean hospital stay was  $9.0 \pm 2.09$  (ranged 5–12 days), and in microscopic group, it was  $9.54 \pm 2.40$  (ranged 6–14 days) (unpaired *t*-test,  $P = 0.52$ , statistically not significant).

## Discussion

Pituitary tumors surgery still represent a significant challenge, despite the highly refined nature of the contemporary microsurgery.<sup>[9]</sup> The endoscope has been introduced to transsphenoidal surgery and had gained significant popularity. Over the past decade, the evolution of pituitary tumors surgery had been characterized by progressive trends toward less invasive approach. The endonasal endoscopic approach provides less invasive approach to the pituitary gland and surrounding area, in addition to providing better intraoperative imaging of the region [Table 1].<sup>[10,11]</sup>

Guiot<sup>[12]</sup> is recognized as first neurosurgeon to use the endoscope in transsphenoidal approach. In 1977, Apuzzo *et al.*<sup>[13]</sup> used endoscope as an adjunct in the microscopic resection of pituitary tumors with extra sellar extension [Table 1]. Fries and Perneczky<sup>[14]</sup> stated that endoscopy improves appreciation of microanatomy not apparent with the microscope and introduced the concept of minimally invasive surgery. In 1992, Jankowski *et al.* used a pure endoscopic transsphenoidal approach to the sella turcica.

The largest prospective endoscopic series (215 patients) is reported by Kawamata *et al.*,<sup>[15]</sup> but all these patients underwent endoscopic-assisted endonasal transsphenoidal microsurgery without comparison with any other approach. De Divitiis *et al.*<sup>[16]</sup> reported a prospective series of [Table 1] 170 patients with endoscopic approach, but did not include microsurgical group. Kim *et al.*<sup>[17]</sup> in a prospective study of 12 patients, compared endoscopic transsphenoidal surgery with the endoscope-assisted microsurgical approach. Koren *et al.*<sup>[18]</sup> retrospectively compared sublabial transseptal microscopic with endoscopic transseptal approach.

Ahmed Aly *et al.*<sup>[11]</sup> done a prospective study of forty patients on surgical outcomes of endoscopic versus microscopic transsphenoidal approach for pituitary adenoma and concluded that surgical outcomes in endoscopic [Table 1] transsphenoidal approach is better than microscopic approach regarding postoperative nasal complication.

Jain *et al.*<sup>[8]</sup> done a prospective study of twenty patients done a comparison between endonasal endoscopic transsphenoidal surgery and endonasal transsphenoidal microscopic surgery and concluded that in endoscopic surgery there were less postoperative complication less operative time as compared to endonasal transsphenoidal microscopic surgery but complete tumor excision was achieved in the same percentage of patients in both groups [Figure 1 and Table 2].

Endoscopic transsphenoidal pituitary surgery is a developing technique and comparison with microscopic surgery must be done to evaluate merits and demerits. Operating microscope does not visualize whole of the sphenoid sinus, pituitary fossa, and surrounding vital structures. The endoscopic approach had a widened operative field, does not require a nasal speculum as guide

(which creates a fixed tunnel) and is found to have the easier distinction of tumor tissue-gland interface.

Endoscopic surgery had minimal damage to nasal cavity and reduced postoperative morbidity and with angled endoscope all area of nose and paranasal sinus can be completely visualized. Optical properties of endoscope are superior to the operating microscope. Endoscope provides an exquisite view of optic bulge, carotid bulge, and opticocarotid recess which minimize the chances of catastrophic injury to the internal carotid artery.<sup>[19]</sup> There are several limitations of endoscopic approach as it requires a bloodless surgical field and had a steep learning curve.

Endonasal endoscopic surgery does not require sublabial or nasal incision and elevation of mucoperichondrial flap from septum. Hence, potential complication of septal and paranasal sinus areas are eliminated.

In the present study, complete tumor excision was achieved in greater percentage of patients, and there were less postoperative complication, less operative time early discharge from hospital in endoscopic group as compared to microscopic group. The previous prospective study done by Jain *et al.* concluded less postoperative complication, less operative time in endoscopic transsphenoidal group as compared to endonasal microscopic transsphenoidal group, but complete tumor excision was achieved in the same percentage of patients in both groups.

Various other study done by like Gao *et al.*; (endoscopic 81.7% and microscopic 62.2%),<sup>[20]</sup> Ahmed Aly *et al.*; (endoscopic 80% and microscopic 66.7%)<sup>[1]</sup> and Messerer *et al.*; (endoscopic 88% and microscopic 47.8%)<sup>[21]</sup> had showed greater percentage of gross total resection in endoscopic group in comparison to microscopic group which favor our study.

## Conclusion

In pituitary surgery, endoscopic surgery had started new fields not only by direct endonasal approach but also by providing a panoramic view inside the sphenoid cavity and sella turcica. Endonasal endoscopic transsphenoidal pituitary adenoma surgery is a safe and effective procedure. It had minimal invasiveness, and its wider and direct anatomical control of the operative fields allows a faster, greater, and safer potential of tumor excision with respect to the sphenoid, sellar, and parasellar structures.

In endoscopic surgery elimination of intraoral and trans-septal dissection, along with reductions in operative time, intraoperative blood loss, and postoperative complications, have ushered in the completely endonasal endoscopic approach to the pituitary gland as the most recent phase in the evolution of pituitary surgery.

## Financial support and sponsorship

Nil.

## Conflicts of interest

There are no conflicts of interest.

## References

1. Eltabl MA, Eladawy YM, Hanafy AM, Gaber Saleh EE, Elnoomany HA. Surgical outcome of endoscopic versus microscopic trans sphenoidal approach for pituitary adenoma. *Menoufia Med J* 2015;28:87-92.
2. Schwartz TH, Stieg PE, Anand VK. Endoscopic transsphenoidal pituitary surgery with intraoperative magnetic resonance imaging. *Neurosurgery* 2006;58 1 Suppl:ONS44-51.
3. Sachs E. Reminiscences of an American student. *Br Med J* 1957;1:910-16.
4. Schloffer H. Zur Frage der Operationen an der Hypophyse. *Beitr Klin Chir* 1906;50:767-817.
5. Cushing H. Partial hypophysectomy for acromegaly: With remarks on the function of the hypophysis. *Ann Surg* 1909;50:1002-17.
6. Hirsch O. Symptoms and treatment of pituitary tumors. *AMA Arch Otolaryngol* 1952;55:268-306.
7. Jankowski R, Auque J, Simon C, Marchal JC, Hepner H, Wayoff M. Endoscopic pituitary tumor surgery. *Laryngoscope* 1992;102:198-202.
8. Jain AK, Gupta AK, Pathak A, Bhansali A, Bapuraj JR. Excision of pituitary adenomas: Randomized comparison of surgical modalities. *Br J Neurosurg* 2007;21:328-31.
9. Eltabl MA, Eladawy YM, Hanafy AM, Gaber Saleh EE, Elnoomany HA. Surgical outcome of endoscopic versus microscopic trans-sphenoidal approach for pituitary adenoma. *Menoufia Med J* 2015;28:87-92. Available from: <http://www.mmj.eg.net/text.asp?2015/28/1/87/155950>. [Last cited on 2016 Feb 12].
10. Cappabianca P, Alfieri A, de Divitiis E. Endoscopic endonasal transsphenoidal approach to the sella: Towards functional endoscopic pituitary surgery (FEPS). *Minim Invasive Neurosurg* 1998;41:66-73.
11. Sethi DS, Stanley RE, Pillay PK. Endoscopic anatomy of the sphenoid sinus and sella turcica. *J Laryngol Otol* 1995;109:951-5.
12. Guiot G. Trans-sphenoidal approach in surgical treatment of pituitary adenomas: General principles and indications in non functioning adenomas. *Excerpta Med Int Congr Ser* 1973;303:159-78.
13. Apuzzo ML, Heigetz M, Wiess MH, Kurze T. Neurosurgical endoscopy using the side-viewing telescope. Technical note. *J Neurosurg* 1977;16:398-400.
14. Fries G, Pernecky A. Endoscope-assisted brain surgery: Part 2 – Analysis of 380 procedures. *Neurosurgery* 1998;42:226-31.
15. Kawamata T, Iseki H, Ishizaki R, Hori T. Minimally invasive endoscopic-assisted endonasal transsphenoidal microsurgery for pituitary tumors: Experience with 215 cases comparing with sublabial transsphenoidal approach. *Neurol Res* 2002;4:259-65.
16. De Divitiis E, Cappabianca P, Cavallo LM. Endoscopic transsphenoidal approach: Adaptability of the procedure to different sellar lesions. *Neurosurgery* 2002;51:699-705.
17. Kim EY, Park HS, Kim JJ, Han HS, Nam MS, Kim YS, *et al.* Endoscopic transsphenoidal approach through a widened nasal cavity for pituitary lesions. *J Clin Neurosci* 2001;8:437-41.
18. Koren I, Hadar T, Rappaport ZH, Yaniv E. Endoscopic transnasal transsphenoidal microsurgery versus the sublabial approach for the treatment of pituitary tumors: Endonasal complications. *Laryngoscope* 1999;109:1838-40.

19. Lin SZ, Wang GF. Some anatomical data related to the transnasal-sphenoidal resection of pituitary fossa tumors. *Chin Med J (Engl)* 1986;99:602-3.
20. Gao Y, Zheng H, Xu S, Zheng Y, Wang Y, Jiang J, *et al.* Endoscopic versus microscopic approach in pituitary surgery. *J Craniofac Surg* 2016;27:e157-9.
21. Messerer M, De Battista JC, Raverot G, Kassis S, Dubourg J, Lapras V, *et al.* Evidence of improved surgical outcome following endoscopy for nonfunctioning pituitary adenoma removal. *Neurosurg Focus* 2011;30:E11.