

## Predictive Factors for Seizures Accompanying Intracranial Meningiomas

### Abstract

**Objective:** Seizures represent a common manifestation of intracranial meningiomas. Their predictive factors before and after excision merit studying. **Materials and Methods:** Patients having intracranial meningioma were prospectively studied. There were two groups; Group “A” with seizures and Group “B” with no preoperative epilepsy. **Results:** This study included 40 patients. Their ages ranged from 40 to 60 years old, and female-to-male ratio was 2.3:1 in both groups. In Group A, partial seizures were the most common pattern (60%). Manifestations other than fits included headache in most patients (97.5%), symptoms of increased intracranial pressure were found in 50% in Group A and 20% in Group B patients, peritumoral edema was present in 14 (70%) patients of Group A, compared to 6 (25%) patients of Group “B.” There was a statistically significant relation between peritumoral edema and presentation with fits ( $P < 0.1$ ). Complication after surgery included nonsurgical hematoma in three patients and confusion in 7 patients. Following surgery for Group “A”, 8 (40%) patients had good seizure control. While, in Group “B” 3 (15%), patients developed new-onset seizures. Good seizure control in 7 (53%) patients with frontal, frontotemporal tumors than in other locations. In addition, better control was obtained in left sided, small tumors, and no peritumoral edema. Postoperative complication was significantly associated with new-onset epilepsy and poor seizure control ( $P < 0.05$ ). Neither tumor size nor location had a significant relation to either pre or postoperative epilepsy. **Conclusion:** Predictive factors for epilepsy accompanying intracranial meningioma included males, elderly patients and patients with small lesions, frontal and left-sided locations but were statistically insignificant predictors. Peritumoral edema and postoperative complications are the most significant predictors.

**Keywords:** *Epilepsy, excision, lesion, meningioma, peritumoral edema, seizure*

### Introduction

Intracranial meningioma has different presentations; seizures are one of the most common symptoms occurring in 13%–60% of patients. The outcome after meningioma resection can be affected by postoperative seizures.<sup>[1,2]</sup> The preoperative seizures disappear in 53%–90% of patients after tumor excision. Some patients without preoperative seizures may develop *de novo* early or late fits in about 5%–42%.<sup>[1,3]</sup> The mechanisms of tumor-induced seizures are poorly understood. The causative neoplasm may act as a generator to produce an epileptogenic focus in peritumoral brain. The mechanisms of epileptogenesis pre and postoperative are not sufficiently known. Distortion of the cortical structures may be the generator areas for focal epilepsies. In this study, we prospectively assessed 40 meningioma

patients to evaluate the correlation between different perioperative factors and seizure outcome after excision.<sup>[1–6]</sup>

### Materials and Methods

Prospective study was conducted on 40 patients having intracranial meningioma. They were divided into two groups: the epilepsy Group “A” included 20 patients with preoperative epilepsy, and the nonepilepsy Group “B” included 20 patients without preoperative epilepsy. Pediatric, recurrent and multiple meningioma patients were excluded from the study. All patients underwent preoperative and postoperative complete neurological examination, radiological assessment by computed tomography (CT) and magnetic resonance imaging (MRI) scan, and interictal 16 channel scalp electroencephalography (EEG). Assessment of surgical removal was classified according to the Simpson grading.<sup>[7]</sup> The amount of associated brain edema was classified according to the method used by Go *et al.*<sup>[8]</sup> as absent, marginal, evident

**Moamen Mohamed Morsy,  
Waleed Fawzy El-Saadany,  
Wael Mohamed Moussa,  
Ahmed Elsayed Sultan**

*Department of Neurosurgery,  
Faculty of Medicine, Alexandria  
University, Alexandria, Egypt*

**Address for correspondence:**  
Dr. Ahmed Elsayed Sultan,  
Department of Neurosurgery,  
Faculty of Medicine, Alexandria  
University, Alexandria, Egypt.  
E-mail: [ahmed.sultan@alexmed.edu.eg](mailto:ahmed.sultan@alexmed.edu.eg)

#### Access this article online

**Website:** [www.asianjns.org](http://www.asianjns.org)

**DOI:** 10.4103/ajns.AJNS\_152\_18

#### Quick Response Code:



**How to cite this article:** Morsy MM, El-Saadany WF, Moussa WM, Sultan AE. Predictive factors for seizures accompanying intracranial meningiomas. *Asian J Neurosurg* 2019;14:403-9.

This is an open access journal, and articles are distributed under the terms of the Creative Commons Attribution-NonCommercial-ShareAlike 4.0 License, which allows others to remix, tweak, and build upon the work non-commercially, as long as appropriate credit is given and the new creations are licensed under the identical terms.

**For reprints contact:** [reprints@medknow.com](mailto:reprints@medknow.com)

or severe depending on the extension of the peritumoral hypodense area in the brain CT scan and MRI scan. We classified tumor size into 3 categories small (<30 cc), medium (30–60 cc) and large (more than 60 cc) according to MRI finding [Table 1]. Statistical analysis was performed using Chi-square test, *t*-test, and Monte-Carlo test.  $P < 0.05$  was considered statistically significant. Comparison between the two groups in relation to age, sex, tumor site, tumor side, histopathology, and clinical presentation was performed to identify predictive factors for preoperative epilepsy [Table 1]. Postoperative seizure outcome was analyzed according to Engel's classification.<sup>[9]</sup> All patients signed a written informed consent before surgery. As regard seizure medication; before surgery, first-line drugs were used. We used intraoperative loading phenytoin to all patient that continue postoperative after measuring therapeutic level if the seizure was not controlled add-on therapy was used; mostly Levetiracetam.

## Results

### Demographic and clinical data

The patients' age ranged from 40 to 60 years old, the mean age for Group A was 50.65 years, and 47.15 years for Group B. The female-to-male ratio was 2.3:1 in both groups. There was no statistically significant relation between age or gender and preoperative epilepsy [Table 1]. Presentation with symptoms of increased intracranial pressure were seen in 10 (50%) patients and mental changes in 4 (20%) patients among Group A as compared to 4 (20%) patients and 1 (5%) patient in Group B, respectively. There was no statistically significant correlation between clinical presentations and preoperative epilepsy.

### Imaging finding

There was a higher incidence of frontal and frontotemporal locations in Group "A" (13 patients, 65%), compared to in Group "B" (10, 50% patients). There was no statistically

**Table 1: Demographic, radiological, and pathological relation to preoperative epilepsy**

	Group A (n=20) n (%)	Group B (n=20) n (%)	Total (n=40) n (%)	P
AGE (mean 40-60 years)	15 (75%)	14 (70%)		1.352 <sup>MC</sup>
Female Sex	12 (60)	16 (80)		$\chi^2 p=1.071$
Presentations				
Fits	20 (100)	0 (0%)		
Headache	20	19		
Focal deficits	6	8		
Increased ICP	10	4		
Mental changes	4	1		
Tumor Site				
Frontal	7 (35)	6 (30)	13 (32.5)	$\chi^2 p=0.723$
Frontotemporal	6 (30)	4 (20)	10 (25)	$\chi^2 p=0.435$
Temporal	1 (5)	1 (5)	2 (5)	<sup>FE</sup> $p=0.407$
Frontopareital	2 (10)	6 (30)	8 (20)	<sup>FE</sup> $p=1.000$
Pareitoccipital	1 (5)	3 (15)	4 (10)	<sup>FE</sup> $p=0.462$
Petroclival/tentorial	3 (15)	-	3 (7.5)	<sup>FE</sup> $p=0.487$
Tumor side				
Midline lesions	5 (25.0)	9 (45.0)	14 (35.5)	$\chi^2 p=0.327$
Right	10 (50.0)	6 (30.0)	16 (40.0)	$\chi^2 p=0.197$
Left	5 (25.0)	5 (25.0)	10 (25.5)	<sup>FE</sup> $p=1.000$
Tumor Size				
Small	8 (40)	8 (40)	16 (40)	$\chi^2 p=1.000$
Medium	10 (50)	7 (35)	17 (42.5)	$\chi^2 p=0.627$
Large	2 (10)	5 (25)	7 (17.5)	<sup>FE</sup> $p=0.407$
Peritumoral edema				
No edema	6 (30.0)	15 (75.0)	21 (52.5)	0.010*
Evident edema	14 (70.0)	5 (25.0)	19 (47.5)	
Tumor pathology				
Meningiothelial	2 (10)	3 (15.0)	5 (15.0)	<sup>FE</sup> $p=1.000$
Transitional	4 (20)	2 (10.0)	6 (12.5)	<sup>FE</sup> $p=1.000$
Atypical	1 (5.0)	0 (0.0)	1 (2.5)	<sup>FE</sup> $p=1.000$
Fibroplastic	1 (5.0)	2 (10.0)	3 (7.5)	<sup>FE</sup> $p=1.00$
Angioplasic	1 (5.0)	1 (5.0)	2 (5.0)	<sup>FE</sup> $p=1.000$
Chordoid	11 (55.0)	12 (60.0)	23 (57.5)	$\chi^2 p=0.749$

FE – Fisher exact test;  $\chi^2$  – Chi-square; ICP – Intracranial pressure; MC – Monte\_carlo test

significant relation between tumor location and preoperative epilepsy. Eighteen (90%) patients of Group “A” had tumor sizes <60 cc compared to 15 (75%) patients in Group “B”. There was no statistically significant relation between tumor size and occurrence of epilepsy. There was a higher incidence of peritumoral edema in Group “A” (14, 70% patients), compared to 6 (25%) patients in Group “B.” There was a statistically significant relation between peritumoral edema and preoperative epilepsy ( $P = 0.010$ ) [Figures 1, 2 and Table 1].

### Histopathology

Meningothelial meningioma was the most common histopathological type. There was no statistically significant relation between the different histopathological types and occurrence of epilepsy [Table 1].

### Postoperative findings

Following surgery for Group “A” 8 (40%) patients had good seizure control while, in Group “B” patients 3 (15%) patients developed new-onset seizures. Among Group “A”, there was a higher incidence of good seizure control in 7 (53%) patients with frontal, frontotemporal tumors than in patients with frontoparietal, temporal, parietooccipital, and petroclival/tentorial tumors. However, there was no statistically significant relation between tumor location and seizure control. Among Group “A”, there was a higher incidence of good seizure control in 5 (50%) patients with left side tumors than in patients with right sided and midline tumors. However, there was no statistically significant relation between tumor side and seizure control. However, there was no statistically significant relation between tumor size and seizure control. The rate of postoperative complications in both groups is shown in Table 2. Among Group “A”, there was a higher incidence of good seizure control in 6 (30%) patients who had no postoperative complications compared to 2 (10%) patients who had postoperative complication. There was a statistically significant relation between the occurrence of postoperative complication and poor seizure control in this group ( $P = 0.0194$ ). Among Group “B”, all 3 (15%) patients who had postoperative complications developed new-onset seizures. There was a statistically significant relation between postoperative complications and new-onset epilepsy in this group ( $P = 0.0307$ ). The agreement between tumor side and EEG lateralization was compared to postoperative seizure control in Group A. There was no statistically significant concordance between these variables (0.3246). The agreement between tumor site and EEG localization was compared to postoperative seizure control in Group A. There was no statistically significant concordance between these variables (0.242) [Tables 2-5].

### Discussion

Intracranial meningiomas are common intracranial tumors which may be presented with epilepsy as one of the most common symptoms, with an incidence of 20%–50% as

**Table 2: Distribution of postoperative complication in both groups**

Complication	Group A (n=20)	Group B (n=20)	Total (n=40)
Infarction	1	-	1
Edema	5	3	8
Contusion	4	3	7
Hematoma	2	1	3
Total	12	7	19

**Table 3: Seizure outcome in both group**

	n (%)
Seizure control	
Good control	8 (40)
Poor control	12 (60)
New seizure occurrence	
Yes	3 (15)
No	17 (85)

**Table 4: Concordance of postoperative complications and seizure outcome**

	Seizure outcome		Total	P
	Controlled	Uncontrolled		
Group A				
Complication	2	10	12	0.0194*
No complication	6	2	8	
	No seizure	New onset seizure	Total	P
Group B				
Complication	4	3	7	0.0307*
No complication	13	-	13	

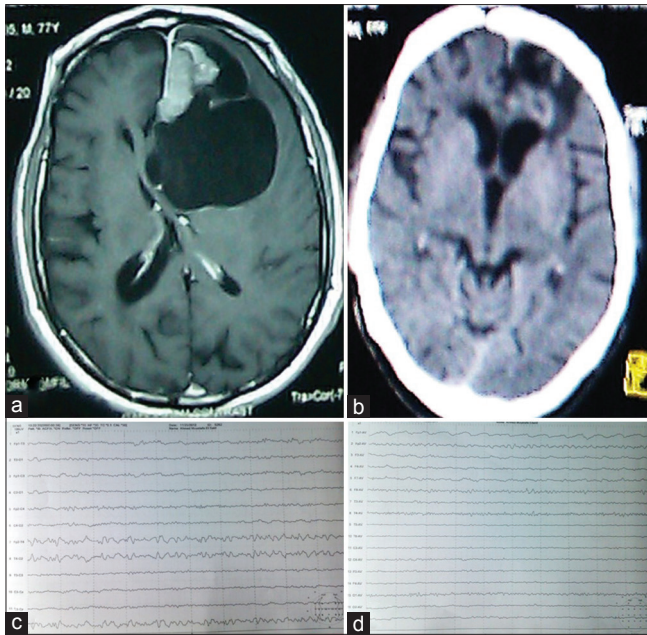
\*Statistically significant at  $P \leq 0.05$ .  $P - P$  value for comparing between postoperative complication status and seizure outcome in Group B

**Table 5: Predicting factor of seizure outcome**

	Seizure outcome		Total	P
	Controlled	Uncontrolled		
Tumor site				
Frontal	4	3	7	0.544 (FE)
Frontotemporal	3	3	6	1.000 (FE)
Frontoparietal	-	1	1	0.407 (FE)
Temporal	-	2	2	1.000 (FE)
Pareitoccipital	-	1	1	1.000 (FE)
Petroclival/tentorial	1	2	3	1.000 (FE)
Tumor side				
Right	1	4	5	0.327 (FE)
Left	5	5	10	1.000 ( $\chi^2$ )
Midline	2	3	5	1.000 (FE)
Tumor size				
Small	4	4	8	1.000 (FE)
Medium	3	7	10	0.627 (FE)
Large	1	1	2	1.000 (FE)

FE – Fisher’s exact test,  $\chi^2$  – Chi-square

the first symptom. Surgical removal of the tumor is the first choice of treatment. The predictors of preoperative



**Figure 1:** A male patient aged 77 years, presented with fits, mental changes, and headache. (a) axial T1 with contrast showing left frontal midline meningioma with large surrounding cyst. (b) late follow-up computed tomography showing complete tumor removal, cyst disappearance, and resolution of mass effect. The patient fits were controlled (c and d) preoperative (c) and postoperative electroencephalography showing disappearance of the temporal epileptiform activity

and postoperative epilepsy have been rarely reported in the literature. In this study, we prospectively analyzed 40 patients of whom (20 patients presented with epilepsy “Group A” and 20 patients presented with symptom other than epilepsy “Group B”). The incidence, prognosis, and influencing factors for preoperative and postoperative epilepsy were reviewed and analyzed.<sup>[1,6]</sup>

Age distribution in our study showed that the mean age in Group “A” was 50.65 years and in Group “B” was 47.15 years. There was no statistically significant relation between age and occurrence of epilepsy. Lieu and Howng<sup>[1]</sup> similarly observed that, the occurrence of epilepsy was not significantly different in age groups; however, it occurs more frequently in the fifth and sixth decades. However, Kawaguchi *et al.*<sup>[6]</sup> reported that the mean age in meningioma patients who presented with epilepsy was significantly less than those not presenting with epilepsy. In our study the mean age of Group A was more than in Group B, these findings may be related to the fact that some of our patients received treatment of epilepsy and did not undergo adequate neuroimaging to verify the presence of the tumor.

Gender distribution in our study showed that the overall female-to-male ratio was 2.3:1. There was a higher incidence of female patients among Group (B) 4:1 than in Group (A) 1.5:1; however, the relation was not statistically significant. Similar results were reported by Chow *et al.*<sup>[10]</sup> and Chozick *et al.*<sup>[11]</sup>

There was a higher incidence of presentation with manifestations of increased intracranial pressure and mental changes in the epileptic Group “A.” These findings may be attributed to large tumor size and predominating frontal location of meningiomas in our study. The relation between different presentation and occurrence of epilepsy was not statistically significant. Similar results were reported by Gilles *et al.*<sup>[12]</sup> Contrary to what reported by Riva,<sup>[13]</sup> (he studied epilepsy in intrinsic brain tumors) and found that patients with seizures showed a significantly lower incidence of neurological deficit, headache, and mental disturbances compared with nonepileptic patients. He also found no association between the occurrence of epileptic seizures and increased intracranial pressure.

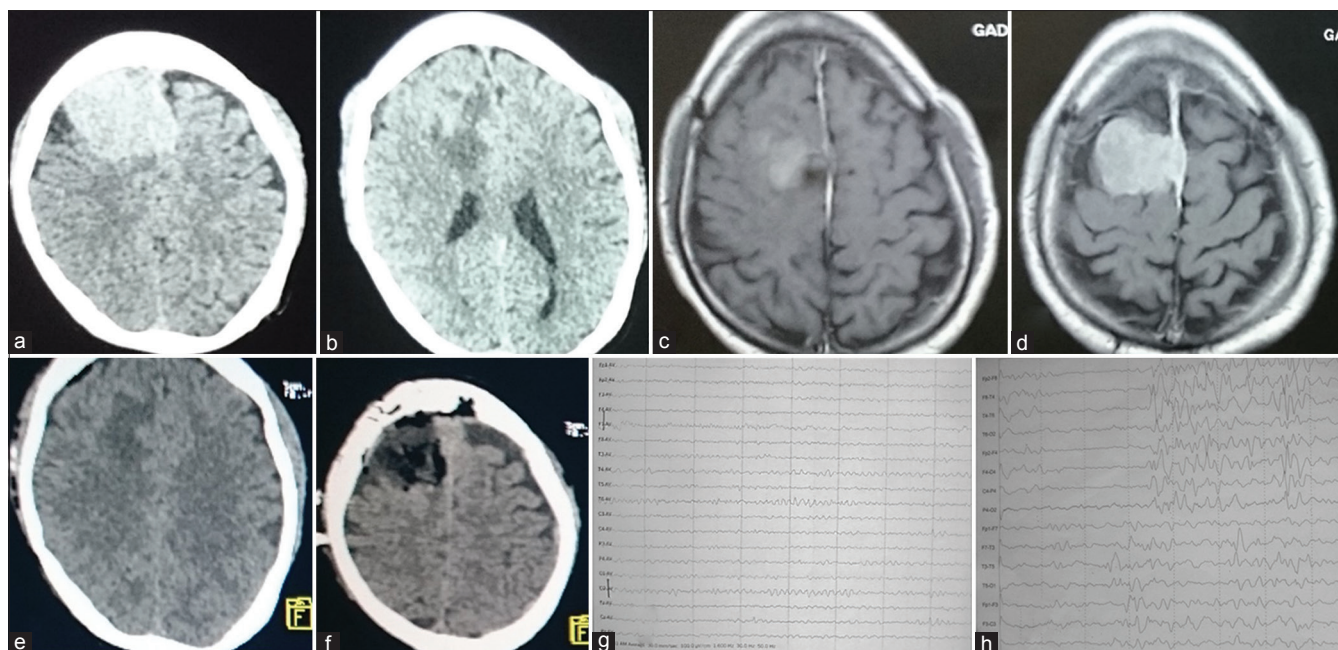
Distribution of seizure pattern in our study showed that among Group “A” patients, partial seizures with secondary generalization constituted the most common seizure pattern. Our results may be due to predominating frontal location of meningiomas. In contrary to what was reported by Lieu and Howng,<sup>[1]</sup> who found that generalized seizure occurred in 40 (67%) patients, partial seizure in 16 (27%) patients, partial seizure with secondary generalization in 2 (5%) patients, and complex partial seizure in 1 (2.5%) patients.

The epileptic Group “A” patients have their tumor location mostly in frontal and frontotemporal regions. There was no statistically significant relation between tumor location and occurrence of epilepsy. Liigant *et al.*<sup>[14]</sup> found that higher incidence of seizures was in tumors involving the frontoparietal (58%), frontotemporal (44%), and temporal (40%) regions but no significant association with tumor location. Riva<sup>[13]</sup> found no statistically significant relation between tumor site and occurrence of epilepsy. Kawaguchi *et al.*,<sup>[6]</sup> who studied convexity meningioma found that there was a significant relationship between the seizure occurrence and tumor location.

Distribution of tumor side in both groups showed that the left side was the most common tumor side in Group “A” patients whereas the right side was the most common tumor side in Group “B” patients. There was no statistically significant relation between tumor side and occurrence of epilepsy. Our results were similar to what was reported by, Lieu and Howng<sup>[1]</sup> different results were reported by Riva,<sup>[13]</sup> who stated that there was a statistically difference between tumor side and seizure occurrence.

Distribution of tumor size in both groups showed that there was no statistically significant relation between tumor size and occurrence of epilepsy. Similar results were reported by Kawaguchi *et al.*,<sup>[6]</sup> who found that there was no significant difference in tumor size and occurrence of epilepsy.

Distribution of peritumoral edema in both groups showed that there was a higher incidence of peritumoral edema in Group “A” patients than in Group “B” patients. There was a statistically significant relation between peritumoral



**Figure 2:** A male patient aged 48 years old presented with headache, left-sided weakness. (a and b) axial computed tomography scan with contrast showing parasagittal enhancing lesion with peritumoral edema. (c and d) preoperative axial T1 magnetic resonance imaging brain with contrast showing an enhancing lesion. (e and f) Axial computed tomography scan in the same postoperative day showing tumor removal and residual edema. The patient developed postoperative generalized fits. (g and h) preoperative (g) And postoperative (h) Electroencephalography showing appearance of generalized epileptiform activity

edema and occurrence of epilepsy. Lieu and Howng<sup>[1]</sup> and Kawaguchi *et al.*<sup>[6]</sup> reported similar results that most patients with evident or severe edema, had preoperative and postoperative epilepsy with a significant correlation.

Some authors noted that peritumoral edema fluid consists of excessive concentration of glutamate and aspartic acid which may be involved in denervation hypersensitivity and propagation of excitatory influences.<sup>[6,15,16]</sup>

Distribution of tumor histopathology in both groups showed that meningothelial meningioma was the most common histopathological types. There was no statistically significant relation between the different histopathological types and occurrence of epilepsy. Chow *et al.*<sup>[10]</sup> had similar results that the histologic types were not significantly correlated with preoperative epilepsy. Lieu and Howng<sup>[1]</sup> found that the rate of preoperative epilepsy in different histological types was as follows: meningotheliomatous (19.3%), transitional (37.9%), psammomatous (20%), fibroblastic (25%), ANGIOBLASTIC (50%), atypical (50%) and others (40%). angioblastic meningiomas have a high incidence of associated preoperative epilepsy; however, it does not demonstrate significant difference between histological type and preoperative epilepsy. In contrary to what was reported by Kawaguchi *et al.*,<sup>[6]</sup> who believed that fibroblastic meningiomas were significant correlated with preoperative epilepsy.

Concordance between EEG localization and tumor site showed that the relation between interictal EEG localization and tumor site was concordant in 3 (15%)

patients and nonconcordant in 17 (85%). There was no statistically significant concordance between the site of the interictal electrical activity and tumor site. These agree with Morrell,<sup>[17]</sup> who stated that for about a third of their patients, the epileptogenic focus does not correspond to tumor location. This result could be explained that the tumor induces secondary epileptogenesis which implies that an actively discharging epileptogenic focus induces similar paroxysmal activity in regions that are distant to the original site. This secondary focus is seen more frequently with temporal tumors.

Concordance between EEG lateralization and tumor side showed that the relation between interictal EEG lateralization and tumors side was concordant in 6 (30%) and nonconcordant in 14 (70%) patients. There was no statistically significant concordance between the side of the interictal electrical activity and tumor side. Similar results were reported by JiHoon Phi *et al.*<sup>[18]</sup> who found that, interictal EEG was lateralized to the affected temporal lobe in 29 (48%) patients, to the contralateral temporal lobe in 1 (2%) patient, to the bilateral temporal lobes in 3 (5%) patients, and to the affected temporal lobe and an extratemporal lobe in 4 (7%) patients. It was nonlocalizable in 23 (38%) patients. There was no statistically significant relation between tumor side and interictal EEG lateralization. According to Zaatreh *et al.*,<sup>[19]</sup> there was no concordance between tumor side and interictal EEG lateralization.

Regarding seizure control, among Group “A” patients 8 (40%) patients had good seizure control, and 12 (60%) had

poor seizure control while in Group “B” patients 3 (15%) patients developed *de novo* seizures. Some authors reported that surgical removal of a meningioma eliminates epilepsy in 19.2%–63.5% of patients with preoperative epilepsy whereas postoperative epilepsy develops in 5.1%–42.9% of patients with no history of preoperative epilepsy.<sup>[11,15,19,20]</sup> According to Lieu and Howng,<sup>[1]</sup> 37 (62.7%) patients had complete cessation of epilepsy after operation and the incidence of patients with new-onset epilepsy after surgery was 18.4%. According to JiHoon Phi *et al.*,<sup>[18]</sup> the following factors were found to be significantly associated with poor seizure control: duration of epilepsy >10 years, presence of a remote focus on surface EEG, and incomplete tumor removal.

Regarding the relation between seizure control and tumor side, among Group A patients, there was a higher incidence of good seizure control in 5 (50%) patients with left side tumors than in patients with right sided and midline tumors; however, there was no statistically significant relation between tumor side and seizure control. This similar reports of Lieu and Howng<sup>[1]</sup> and Zaatreh *et al.*<sup>[19]</sup> Scott<sup>[21]</sup> stated that patients with predominantly left-sided meningioma showed a statistically significant greater chance of developing seizures after operation while the occurrence of preoperative or postoperative epilepsy is not significantly different between right and left hemispheric lesions.

Regarding the relation between seizure control and peritumoral edema, among Group “A” patients, there was a higher incidence of good seizure control in 3 (50%) patients with no peritumoral edema than in patients with peritumoral edema; however, there was no statistically significant relation between peritumoral edema and seizure control. Contrary to what reported by Lieu and Howng,<sup>[1]</sup> who stated that intracranial meningiomas with evidence of or severe peritumoral edema were also a significant influencing factor for postoperative epilepsy. Tumors with evidence of or severe perifocal edema associated significantly with cerebral edema at the operative site and thus also have an influence, especially in the early onset of postoperative epilepsy, which is an observation previously made by others Tsuji *et al.*<sup>[22]</sup> and Chow *et al.*<sup>[10]</sup> Surgical manipulation and slow resolution of perifocal edema may be the cause of cerebral edema at operative site.

Regarding the relation between seizure control and postoperative complication, among Group “A” patients, there was a higher incidence of good seizure control in 8 (40%) patients who had no postoperative complications compared to 1 (5%) patients who had postoperative complication. There was a statistically significant relation between the postoperative complication and poor seizure control. While among Group “B”, 3 (15%) patients with complications developed new onset seizure. There was a statistically significance relation between postoperative

complications and new onset epilepsy. Some authors had the same findings that factors that have been associated with the development of postoperative epilepsy after intracranial meningioma operation include brain retraction, interruption of cortical veins, arterial damage, preoperative epilepsy history, extent of tumor removal, and postoperative hydrocephalus as well as parietal location.<sup>[10,11,15,20]</sup> Lieu and Howng<sup>[1]</sup> stated that history of preoperative epilepsy, evidence of peritumoral edema, and cerebral edema at operative site play significant roles in postoperative epilepsy. In addition, lieu and Howng<sup>[1]</sup> reported that 33% of his patients with early onset of postoperative epilepsy hematoma at operative site were found. According to Phi *et al.*,<sup>[18]</sup> Luyken *et al.*,<sup>[23]</sup> and Cataltepe *et al.*,<sup>[24]</sup> the presence of a remote focus on surface EEG and failure of total tumor removal were related to poor seizure control. According to Jeha *et al.*,<sup>[25]</sup> independent predictors for poor seizure outcome were generalized or nonlocalized ictal EEG patterns. According to Kawaguchi *et al.*,<sup>[6]</sup> we know that critical normal tissue is usually left behind or “*in situ*” in the so-called epileptogenic zone after the epileptogenic lesion (tumoral or nontumoral) has been removed, making “lesionectomy-only” responsible for lack of freedom from seizures.

## Conclusion

Preoperative epilepsy in meningioma can be predicted to be controlled in approximately 40% of the cases after lesion excision. New-onset postoperative seizures can develop in about 15%. There was a trend for occurrence of preoperative epilepsy among older patients, male patients, meningiomas in frontal and frontotemporal locations, left-sided meningiomas and meningiomas with small and medium size <60 cc; however, these predictors were statistically insignificant. Peritumoral edema was statistically significant predictor of preoperative epilepsy postoperative complications were statistically significant predictors for neo-onset postoperative epilepsy. Concordance between the lesion and the focus is important for the best results of epilepsy surgery. However, this concordance was seldom achieved among our patients.

## Financial support and sponsorship

Nil.

## Conflicts of interest

There are no conflicts of interest.

## References

- Lieu AS, Howng SL. Intracranial meningiomas and epilepsy: Incidence, prognosis and influencing factors. *Epilepsy Res* 2000;38:45-52.
- Zheng Z, Chen P, Fu W, Zhu J, Zhang H, Shi J, *et al.* Early and late postoperative seizure outcome in 97 patients with supratentorial meningioma and preoperative seizures: A retrospective study. *J Neurooncol* 2013;114:101-9.

3. Tomasello F. Meningiomas and postoperative epilepsy: It is time for a randomized controlled clinical trial. *World Neurosurg* 2013;79:431-2.
4. Fang S, Zhan Y, Xie YF, Shi Q, Dan W. Predictive value of electrocorticography for postoperative epilepsy in patients with supratentorial meningioma. *J Clin Neurosci* 2013;20:112-6.
5. Chaichana KL, Pendleton C, Zaidi H, Olivi A, Weingart JD, Gallia GL, *et al.* Seizure control for patients undergoing meningioma surgery. *World Neurosurg* 2013;79:515-24.
6. Kawaguchi T, Kameyama S, Tanaka R. Peritumoral edema and seizure in patients with cerebral convexity and parasagittal meningiomas. *Neurol Med Chir* 1995;35:568-74.
7. Simpson D. The recurrence of intracranial meningiomas after surgical treatment. *J Neurol Neurosurg Psychiatry* 1957;20:22-39.
8. Go KG, Wilmink JT, Molenaar WM. Peritumoral brain edema associated with meningiomas. *Neurosurgery* 1988;23:175-9.
9. Engel J Jr., Van Ness PC, Rasmussen TB. With respect to epileptic seizures. In: Engel J Jr., editor. *Surgical Treatment of the Epilepsies*. 2<sup>nd</sup> ed. New York: Raven Press Ltd.; 1993. p. 609-21.
10. Chow SY, Hsi MS, Tang LM, Fong VH. Epilepsy and intracranial meningiomas. *Zhonghua Yi Xue Za Zhi (Taipei)* 1995;55:151-5.
11. Chozick BS, Reinert SE, Greenblatt SH. Incidence of seizures after surgery for supratentorial meningiomas: A modern analysis. *J Neurosurg* 1996;84:382-6.
12. Gilles FH, Sobel E, Leviton A, Hedley-Whyte ET, Taware CJ, Adelman LS, *et al.* Epidemiology of seizures in children with brain tumors. The childhood brain tumor consortium. *J Neurooncol* 1992;12:53-68.
13. Riva M. Brain tumoral epilepsy: A review. *Neurol Sci* 2005;26 Suppl 1:S40-2.
14. Liigant A, Haldre S, Oun A, Linnamägi U, Saar A, Asser T, *et al.* Seizure disorders in patients with brain tumors. *Eur Neurol* 2001;45:46-51.
15. Chan RC, Thompson GB. Morbidity, mortality, and quality of life following surgery for intracranial meningiomas. A retrospective study in 257 cases. *J Neurosurg* 1984;60:52-60.
16. Fishman RA, Chan PH. Metabolic basis of brain edema. In: Cervo's-Navarro J, Ferszt R, editors. *Brain Edema*. Vol. 22. New York: Raven Press; 1980. p. 207-16.
17. Morrell F. Varieties of human secondary epileptogenesis. *J Clin Neurophysiol* 1989;6:227-75.
18. Phi JH, Kim SK, Cho BK, Lee SY, Park SY, Park SJ, *et al.* Long-term surgical outcomes of temporal lobe epilepsy associated with low-grade brain tumors. *Cancer* 2009;115:5771-9.
19. Zaatreh MM, Spencer DD, Thompson JL, Blumenfeld H, Novotny EJ, Mattson RH, *et al.* Frontal lobe tumoral epilepsy: Clinical, neurophysiologic features and predictors of surgical outcome. *Epilepsia* 2002;43:727-33.
20. Ramamurthi B, Ravi B, Ramachandran V. Convulsions with meningiomas: Incidence and significance. *Surg Neurol* 1980;14:415-6.
21. Scott DF. Left and right cerebral hemisphere differences in the occurrence of epilepsy. *Br J Med Psychol* 1985;58(Pt 2):189-92.
22. Tsuji M, Shinomiya S, Inoue R, Sato K. Prospective study of postoperative seizure in intracranial meningioma. *Jpn J Psychiatry Neurol* 1993;47:331-4.
23. Luyken C, Blümcke I, Fimmers R, Urbach H, Elger CE, Wiestler OD, *et al.* The spectrum of long-term epilepsy-associated tumors: Long-term seizure and tumor outcome and neurosurgical aspects. *Epilepsia* 2003;44:822-30.
24. Cataltepe O, Turanlı G, Yalnizoglu D, Topçu M, Akalan N. Surgical management of temporal lobe tumor-related epilepsy in children. *J Neurosurg* 2005;102:280-7.
25. Jeha LE, Najm I, Bingaman W, Dinner D, Widdess-Walsh P, Lüders H, *et al.* Surgical outcome and prognostic factors of frontal lobe epilepsy surgery. *Brain* 2007;130:574-84.