

## Dorsal Spinal Epidural Cavernous Angioma; A Case Report

### Abstract

Spinal cavernous angiomas are lesions formed by vessels lined by closely clustered endothelial cells. They are common in the vertebral body and less common in an intradural location. However, these are very rare in the extra-osseous and epidural region. Less than 100 cases have been reported. Here, we report a case of dorsal spinal extradural cavernous angioma in a 52-year-old man who presented with back pain and difficulty in walking. Magnetic resonance imaging brain showed D7–D8 (thoracic) extradural spinal lesion, enhancing homogeneously on contrast administration. He underwent D7–D8 hemilaminectomy and tumor decompression. The tumor was extradural, tightly adherent to the dura, and highly vascular. He recovered completely after surgical removal with no recurrence 2 years after removal. He was not administered adjuvant radiotherapy. In this article, we review the literature regarding clinical features, imaging findings, and outcome of spinal epidural cavernous angioma.

**Keywords:** *Cavernous angioma of the spine, epidural spine tumor, magnetic resonance imaging spine, spinal tumor, spine tumor surgery, vascular spine lesion*

### Introduction

Cavernous angiomas are common lesions of the central nervous system characterized by abnormally dilated blood vessels lined by a thin endothelium. In the spine, a common location is the vertebral bodies. Intradural extramedullary and intramedullary cavernous hemangiomas are less frequent lesions, while purely epidural locations are uncommon.<sup>[1]</sup> Epidural cavernous angiomas represent 12% of spinal axis cavernous malformations.<sup>[2]</sup>

The earliest case was reported in 1978 by Decker *et al.*<sup>[3]</sup> They are indistinguishable from that of a schwannoma, which is a much more common lesion. Here, we report a case of thoracic epidural cavernous angioma who presented with chronic backache.

### Case Report

A 52-year-old man presented with back pain since a month. He had imbalance while walking on an irregular surface. It was not associated with paraparesis or urinary retention. Magnetic resonance imaging (MRI) of the spine showed a

lobulated, homogeneously contrast-enhancing lesion at the thoracic D7–D8 epidural region. It was hyperintense on T2-weighted image and isointense on T1-weighted image. Indentation on the dorsal spinal cord was seen. Displacement of the cord is seen anterior and to the left side. No obvious cord signal changes were seen. The lesion shows no extension to neural foramen [Figure 1].

He underwent D7–D9 hemilaminectomy and decompression of extradural lesion. The tumor was extradural, highly vascular, and tightly adherent to the dura mater. There was no extension outside the spinal canal. The tumor was partially removed as it was highly vascular, and hemostasis was achieved with activated thrombin and Surgicel Fibrillar. Postoperatively, he had weakness in right quadriceps muscles which gradually improved over 2 weeks. He was not treated with adjuvant radiotherapy. Histopathology examination of section showed variably sized vessels lined by endothelial cells [Figure 2]. The vessels ramified between lobules of adipose tissue. Vascular endothelial cells are highlighted with CD34 [Figure 3]. A few of the vessels showed fibrin thrombi in the tumor. No mitosis or necrosis was seen. It

**Girish Krishna Joshi,  
K. N. Krishna,  
Dilip Gopal Krishna,  
Ganesh K. Murthy,  
Ajay Herur,  
Sundeep V. Karnam**

*Department of Neurosurgery,  
Apollo Specialty Hospital,  
Bengaluru, Karnataka, India*

#### Address for correspondence:

*Dr. Girish Joshi,  
Department of Neurosurgery,  
Apollo Specialty Hospital,  
Jayanagar 3<sup>rd</sup> Block,  
Near Madhavan Park,  
Bengaluru - 560 011,  
Karnataka, India.  
E-mail: doctorgirishjoshi@gmail.com*

#### Access this article online

**Website:** [www.asianjns.org](http://www.asianjns.org)

**DOI:** 10.4103/ajns.AJNS\_150\_20

#### Quick Response Code:



**How to cite this article:** Joshi GK, Krishna KN, Krishna DG, Murthy GK, Herur A, Karnam SV. Dorsal spinal epidural cavernous angioma; A case report. *Asian J Neurosurg* 2021;16:144-9.

**Submitted:** 09-Apr-2020

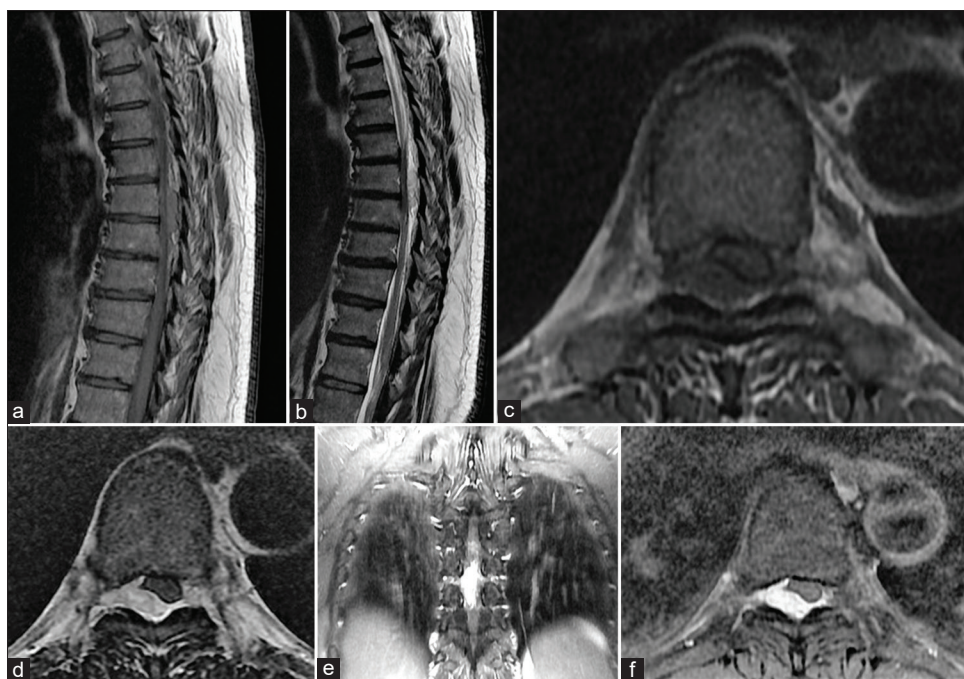
**Revised:** 23-May-2020

**Accepted:** 18-Jul-2020

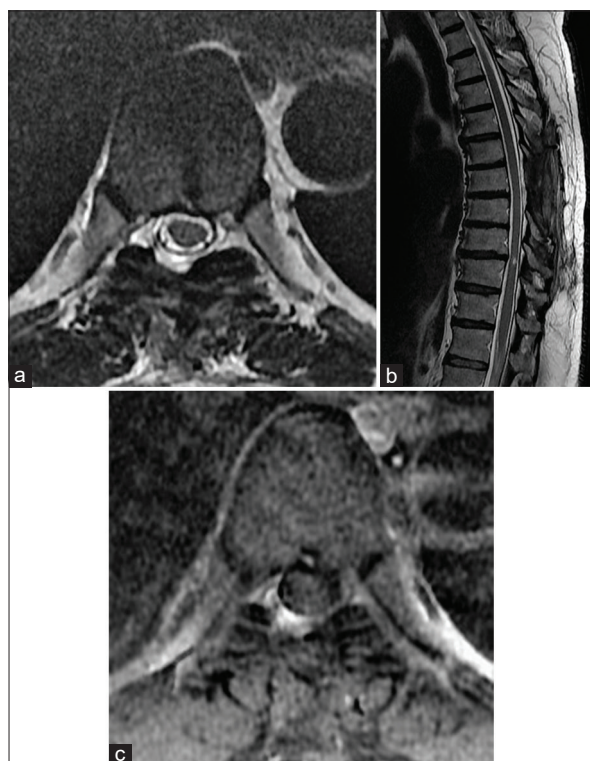
**Published:** 20-Mar-2021

This is an open access journal, and articles are distributed under the terms of the Creative Commons Attribution-NonCommercial-ShareAlike 4.0 License, which allows others to remix, tweak, and build upon the work non-commercially, as long as appropriate credit is given and the new creations are licensed under the identical terms.

**For reprints contact:** [reprints@medknow.com](mailto:reprints@medknow.com)



**Figure 1:** (a) Preoperative magnetic resonance images T1 sagittal showed isointense epidural mass at D7–8 level isointensity on T1-weight sequence. (b) Preoperative magnetic resonance imaging spine T2-weighted image. (c) Preoperative magnetic resonance imaging spine T1-weighted axial image at D7 dorsal spine level. (d) Preoperative magnetic resonance imaging spine T2-weighted axial image. (e) Preoperative magnetic resonance imaging spine T2-weighted image coronal view. (f) Preoperative magnetic resonance imaging with contrast T1-weighted axial view showing homogeneous contrast-enhancing epidural solution at dorsal D7 level pushing cord to left side



**Figure 2:** (a) Postoperative magnetic resonance imaging spine T1-weighted image axial view. (b) Postoperative magnetic resonance imaging T2-weighted image sagittal view showing no recurrence. (c) Postoperative magnetic resonance imaging spine axial view after contrast administration - no recurrence seen

was reported as hemangioma of the extradural space at the D7–D8 dorsal spine. Postoperative MRI spine performed after a year showed no recurrence of the lesion [Figure 4]. He has not received any postoperative radiotherapy. The patient is asymptomatic 2 years after the operation.

### Discussion

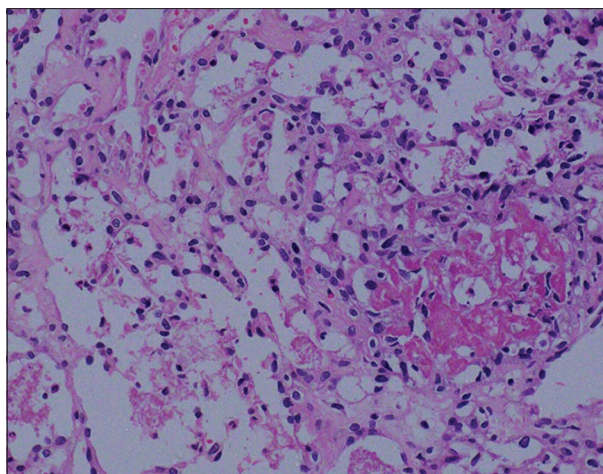
Cavernous angiomas of the spine are benign and are vascular hamartomas representing a dysplasia of the vessel-forming mesoderm. Harrison *et al.* postulated that primordial vessels may lose their capacity to differentiate, resulting in a cavernous malformation.<sup>[4]</sup>

Microscopically, cavernous malformations are composed of closely opposed sinusoidal vascular spaces. The walls consist of an innermost single layer of endothelial cells surrounded by adipose tissue; elastic fibers or smooth muscle cells are absent.<sup>[5]</sup>

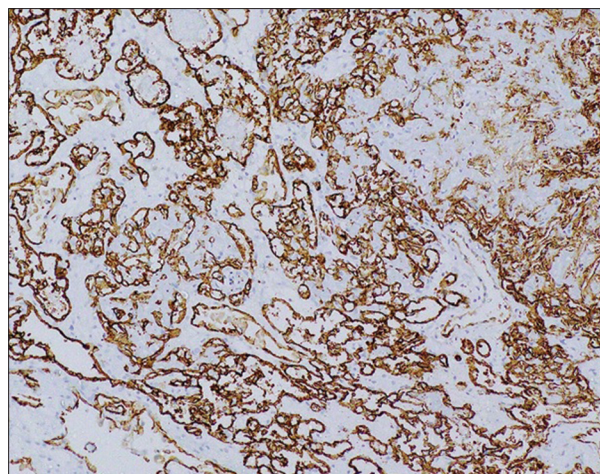
We reviewed the literature of 46 case reports (including our case). The first case we found was reported by Decker *et al.* in 1978 [Table 1].

The average age of patients was 50 years. The youngest was 13 years old and eldest was 79 years old. There were 27 males and 19 females with slight male dominance.

Clinical symptoms were suggestive of the spinal cord or nerve root compression. Pain was the most common



**Figure 3:** Microphotograph showing closely placed small capillary sized vascular channels along with a few dilated ones  $\times 200$ . Note the prominent endothelial cells and fibrin thrombus (\*)



**Figure 4:** CD31 immunohistochemistry highlighting the endothelial cell line capillary channels ( $\times 200$ )

symptom. Cases presented as neck pain, interscapular pain, or back pain depending on the location of the lesion. They were also associated with numbness and radicular pain along the dermatomes of involved roots. Twenty cases presented with spastic paraparesis and urinary frequency or retention.

Thoracic spinal cord was the most common location. In 27 cases, thoracic spinal cord was involved. In our case, dorsal D7 and 8 epidural space was involved. The cervical spine was involved in 6 cases. The lumbar spine was involved in 11 cases. The sacral epidural space was involved in 1 case.

### Radiological features

MRI finding showed an epidural lesion of varying sizes. It is hyperintense on T2-weighted image and isointense on T1-weighted image. Homogeneous contrast enhancement was seen with gadolinium administration. The lesion was completely extradural but tightly adherent to the dura mater. Hemorrhage was seen only in one case reported by Khalatbar *et al.*<sup>[21]</sup>

Dumbbell-shaped, extraforaminal extension was seen in more than 10 cases. These features resemble MRI findings of schwannoma.<sup>[23]</sup> Therefore, it is difficult to diagnose on radiological imaging alone.

### Surgery

All patients underwent surgery either laminotomy or laminectomy. The tumor was extradural, purple or mulberry like, soft, and highly vascular. All surgeries were planned except few. An emergency surgery was performed for hemorrhage into the lesion in one case reported by Khalatbar *et al.* Li *et al.* reported four cases where surgery was done on an emergency basis for sudden onset of paraparesis and urinary retention. The pathology for sudden neurological deterioration was explained by Lee *et al.*

Cavernous angiomas do not grow by mitotic activity but have the propensity to enlarge by thrombosis and bleeding, causing a spectrum of neurological syndromes ranging from radiculopathy to sudden spinal cord dysfunction.<sup>[24]</sup>

From the surgical point of view, it is very important to understand that the extra-axial cavernous angiomas behave like tumors and not like vascular malformations.<sup>[19]</sup>

Surgical decompression is the mainstay of treatment. Radiotherapy was not given as a primary mode of treatment. Only in two cases, adjuvant radiotherapy was given few months after surgery as symptoms persisted or worsened (reported by Sohn *et al.* and Padovani *et al.*).

Fukushima *et al.* reported recurrence of the lesion in his case. He operated thrice over a period of two decades.

### Outcome

Spinal epidural angioma has a favorable outcome with total or subtotal removal. Complete recovery was noted in 19 patients. Partial recovery was seen in 8 patients. Our case had right knee extensor weakness in the postoperative period. He recovered within 2 weeks with no neurological deficits.

### Conclusion

This observation and a review of the literature highlights that spinal epidural cavernous angioma presents as compressive spinal cord pathology with symptoms of backache, weakness in legs, difficulty in walking, or retention of urine. MRI spine with contrast helps in preoperative diagnosis of angioma. It may present with sudden neurological deficits due to hemorrhage which warrants emergency decompression. Surgical decompression is the mainstay of treatment. There is no role of adjuvant radiotherapy. As the tumor is highly

**Table 1: Review of literature**

Author	Age (years)	Sex	Symptom	Location	Size	Surgery	Recovery
Minh <i>et al.</i> , 2005 <sup>[6]</sup>	18	Male	Neck pain, paresthesia	Cervical C6-T1	1.5×4.5	C5-T2 laminoplasty	CR
Yunoki <i>et al.</i> , 2015 <sup>[7]</sup>	77	Male	Back pain	Lumbar L2-L3	Dumbbell shaped across L2 foramen	L2-L3 extra- and intracanalicular approach	CR
Uchida <i>et al.</i> , 2010 <sup>[8]</sup>	75	Male	Both leg pain and numbness 3 years	T11-T12 thoracic	Extending to left foramen	T11-T12 partial laminectomy and medial foraminotomy	CR
Talacchi <i>et al.</i> , 1998 <sup>[9]</sup>	66	Male	Spastic paraparesis, leg pain, and numbness ×3 years	T5-T7 thoracic	Purple color	Laminectomy at T5-T6	CR
	69	Male	Back pain, right leg pain, numbness, weakness since 3 weeks	T6-T8 thoracic	Mulberry, extending to right foramen	Laminectomy T6-T8	CR
	61	Male	Back pain, spastic paraparesis	T8-T10	Pushing spinal cord to right side	T8-T10 laminotomy	PR
	72	Female	Spastic paraparesis, urinary retention, paresthesia	Thoracic T4-T6	Extending to left T5 foramen and pushing spinal cord to right	T4-T6 laminotomy	PR
	44	Female	Spastic paraparesis, neck, right arm thoracic pain	Thoracic T5-T8	Oval extending to right paravertebral space through T6-T7 foramen	T5-T8 laminotomy 2 <sup>nd</sup> surgery (thoracotomy) for right paravertebral lesion	PR
Rovira <i>et al.</i> , 1999 <sup>[10]</sup>	51	Female	Back pain and right sciatica 3 months	Lumbar L3-L4	Extending to left L3-L4 foramen	L3-L4 laminotomy	PR
	16	Male	Left sciatica 1 year	Lumbar L5-S1	Associated with L5-S1 Grade 1 spondylolisthesis	L5-S1 laminotomy	PR
	19	Female	Left leg pain, pollakiuria	Lumbar L3-L4	Left L4 lateral recess extension	L3-L4 Laminotomy	CR
Padovani <i>et al.</i> 1982 <sup>[11]</sup>	75	Male	Spastic paraparesis	Thoracic T3-T6	Extending to left T5 foramen	T3-T6 laminotomy, received radiotherapy	CR
Morioka <i>et al.</i> , 1986 <sup>[12]</sup>	50	Male	Paresthesia in legs and abdomen below T6	Thoracic T2-T3	Extending to left paravertebral space through left L5 foramen	T2-T4 laminectomy and left thoracotomy	CR
Decher <i>et al.</i> , 1978 <sup>[13]</sup>	65	Female	Right abdomen and leg pain	Lumbar L1-L2	Extending to right L1 foramen	L1-L2 right hemilaminectomy and foraminotomy	CR
Lanotte <i>et al.</i> , 1994 <sup>[1]</sup>	65	Male	Neck pain since 6 months	Thoracic T1-T2	Extending across left T1 foramen to paravertebral space	Thoracic left T1-T2 laminotomy	NA
Franz <i>et al.</i> , 1987 <sup>[14]</sup>	23	Male	Spastic paraplegia			NA	NA
Li <i>et al.</i> , 2015 <sup>[15]</sup>	79	Male	None	T6-T7	NA	T6-T7 laminotomy	NA
	56	Male	Spastic paraplegia, urine retention	T2-T4	NA	T2-T4 laminotomy	NA
	42	Male	None	T7-T8	NA	T7-T8 laminotomy	NA
	15	Male	Spastic paraplegia, urine retention	C6-T2	NA	Emergency C6-T2 laminotomy	NA
	35	Male	Spastic paraplegia, urine retention	T2-T4	NA	Emergency T2-T4 laminotomy	NA
	68	Female		L2-L3	NA	L2-L3 laminotomy	NA
	66	Male	Spastic paraplegia, urine retention	T2-T4	NA	T2-T4 laminotomy	NA
	67	Male	Spastic paraplegia, urine retention	T3-T4	NA	T3-T4 laminotomy	NA
	24	Male	Spastic paraplegia, hyperesthesia	C6-C7	NA	Emergency C6-C7 laminectomy	NA

Contd...

**Table 1: Contd...**

Author	Age (years)	Sex	Symptom	Location	Size	Surgery	Recovery
Li <i>et al.</i> , 2015 <sup>[15]</sup>	35	Female	None	C4-C5	NA		NA
	67	Male	Spastic paraplegia, urine retention	T2-T3	NA	T2-T3 laminotomy	NA
	54	Female	None	C7-T1	NA	C7-T1 laminotomy	NA
	65	Female	Spastic paraplegia, urine retention	T12-L2	NA	T12-L2 laminotomy	NA
	50	Female	Spastic paraplegia, urine retention	T4-T5	NA	Emergency T4-T5 laminectomy	NA
Shukla <i>et al.</i> <sup>[16]</sup>	52	Female	Left leg pain	L3-L4 lumbar	Left foraminal extension	L2-L4 hemilaminectomy	NA
Haimes and Krol, 1991 <sup>[17]</sup>	46	Male	Left leg pain	Thoracic T2-T5	Left T3-T4 foramen extension	T2-T5 laminotomy	NA
Fukushima <i>et al.</i> , 1987 <sup>[18]</sup>	54	Male	Spastic paraparesis, urinary retention, paresthesia	Thoracic T6-T8	3×1.5×0.5	T6-T8 laminotomy Operated thrice	PR
Saringer <i>et al.</i> , 2001 <sup>[19]</sup>	56	Female	Paresthesia along right D3 dermatome	Thoracic T3-T4	Extraforaminal extension through right T3-T4	T3-T4 laminectomy and facetectomy	CR
Khalatbari <i>et al.</i> , 2012 <sup>[20]</sup>	74	Female	Pain, spastic paraparesis	T5-T9	A hematoma compressing spinal cord	T5-T9 laminectomy	PR
	26	Male	Pain, spastic paraparesis	T8	NA	T7-T8 laminectomy	CR
	53	Female	Right L3 radiculopathy	L2	NA	L2-L3 laminotomy	CR
	45	Male	Left leg pain	L2	NA	L2 laminotomy	CR
	52	Male	Spastic paraparesis	T7-T8	NA	T7-T8 laminectomy	CR
	13	Female	Spastic paraparesis	T6-T8	NA	T6-T8 laminotomy	CR
	41	Female	Paraparesis, back pain	L1-L2	NA	L1-L2 laminotomy	CR
	59	Female	Back pain, right L5 radiculopathy	L4-L5	Left L4-L5 foraminal extension	Left L4-L5 laminectomy	CR
	40	Female	Back pain, right S1 radiculopathy	S1-S2	NA	NA	CR
Jeong <i>et al.</i> <sup>[21]</sup>	62	Male	Interscapular pain	Thoracic T2-T3	Left paravertebral extension through T2-T3 foramen	T2-T3 laminectomy and thoracoscopic removal of paravertebral lesion	CR
Sohn <i>et al.</i> , 2009 <sup>[22]</sup>	27	Female	Right shoulder pain, gait disturbance	Thoracic T1-T3	Extending through right T2-T3 foramen	T1-T3 laminectomy Postoperative radiotherapy for recurrent symptoms	PR
Present case	52	Male	Back pain, gait disturbance	T7-T8. Thoracic	No	D7-D8 laminectomy	CR

PR – Partial recovery; CR – Complete recovery; L – Lumbar; C – Cervical; D – Dorsal; T – Thoracic; S – Sacral; NA – Not available

vascular, hemostatic agents are required during surgery. The tumor may extend into paravertebral space through the intervertebral canal. This may require additional thoracotomy for tumor removal. Clinical recovery is complete after surgery in most of the cases.

**Declaration of patient consent**

The authors certify that they have obtained all appropriate patient consent forms. In the form the patient(s) has/have given his/her/their consent for his/her/their images and other clinical information to be reported in the journal. The patients understand that their names and initials will not be published and due efforts will be made to conceal their identity, but anonymity cannot be guaranteed.

**Financial support and sponsorship**

Nil.

**Conflicts of interest**

There are no conflicts of interest.

**References**

1. Lanotte M, Massaro F, Faccani G, Fomi M, Valentini MC. Dumbbell-shaped spinal epidural cavernous angioma. Case report. *Ital J Neurol Sci* 1994;15:429-32.
2. Singh RV, Suys S, Campbell DA, Broome JC. Spinal extradural cavernous angioma. *Br J Neurosurg* 1993;7:79-82.
3. Decker RE, San Augustin W, Epstein JA. Spinal epidural venous angioma causing foraminal enlargement and erosion of vertebral body. Case report. *J Neurosurg* 1978;49:605-6.

4. Harrison MJ, Eisenberg MB, Ullman JS, Oppenheim JS, Camins MB, Post KD. Symptomatic cavernous malformations affecting the spine and spinal cord. *Neurosurgery* 1995;37:195-204.
5. McCormick WF. The pathology of vascular (“arteriovenous”) malformations. *J Neurosurg* 1966;24:807-16.
6. Minh NH. Cervicothoracic spinal epidural cavernous hemangioma: Case report and review of the literature. *Surgical Neurol* 2005;64:83-5.
7. Yunoki M, Suzuki K, Uneda A, Yoshino K. A case of dumbbell-shaped epidural cavernous angioma in the lumbar spine. *Surg Neurol Int* 2015;6:S309-12.
8. Uchida K, Yayama T, Nakajima H, Hirai T, Kobayashi S, Chen K, *et al.* Microsurgical resection of cavernous haemangioma around the thoracic neuroforamen: A case report. *J Orthop Surg (Hong Kong)* 2010;18:370-3.
9. Talacchi A, Spinnato S, Alessandrini F, Iuzzolino P, Bricolo A. Radiologic and surgical aspects of pure spinal epidural cavernous angiomas. Report on 5 cases and review of the literature. *Surg Neurol* 1999;52:198-203.
10. Rovira A, Rovira A, Capellades J, Zauner M, Bella R, Rovira M. Lumbar extradural hemangiomas: Report of three cases. *AJNR Am J Neuroradiol* 1999;20:27-31.
11. Padovani R, Tognetti F, Proietti D, Pozzati E, Servadei F. Extrathecal cavernous hemangioma. *Surg Neurol* 1982;18:463-5.
12. Morioka T, Nakagaki H, Matsushima T, Hasuo K. Dumbbell-shaped spinal epidural cavernous angioma. *Surg Neurol* 1986;25:142-4.
13. Decker Re, San Augustin W, Epstein Ja. Spinal epidural venous angioma causing foraminal enlargement and erosion of vertebral body. Case Report. *J Neurosurg* 1978;49:605–606.
14. Franz K, Lesoin F, Leys D, Krivosic I, Jomin M. Spinal epidural dumbbell-shaped cavernous angioma. *Rev Neurol (Paris)* 1987;143:298-300.
15. Li TY, Xu YL, Yang J, Wang J, Wang GH. Primary spinal epidural cavernous hemangioma: Clinical features and surgical outcome in 14 cases. *J Neurosurg Spine* 2015;22:39-46.
16. Shukla D, Rao VS, Rajesh A, Uppin MS, Purohit AK. Lumbar extradural dumbbell cavernous hemangioma: A rare lesion. *J Neurosci Rural Pract* 2013;4:207-9.
17. Haimes AB, Krol G. Dumbbell-shaped spinal cavernous hemangioma: A case report. *AJNR Am J Neuroradiol* 1991;12:1021-2.
18. Fukushima M, Nabeshima Y, Shimazaki K, Hirohata K. Dumbbell-shaped spinal extradural hemangioma. *Arch Orthop Trauma Surg* 1987;106:394-6.
19. Saringer W, Nöbauer I, Haberler C, Ungersböck K. Extraforaminal, thoracic, epidural cavernous haemangioma: Case report with analysis of magnetic resonance imaging characteristics and review of the literature. *Acta Neurochir (Wien)* 2001;143:1293-7.
20. Khalatbari MR, Abbassioun K, Amirjmschidi A. Solitary spinal epidural cavernous angioma: Report of nine surgically treated cases and review of the literature. *Eur Spine J* 2013;22:542-7.
21. Jeong WJ, Choi I, Seong HY, Roh SW. Thoracic extradural cavernous hemangioma Mimicking a Dumbbell-Shaped Tumor. *J Korean Neurosurg Soc* 2015;58:72-5.
22. Sohn MJ, Lee DJ, Jeon SR, Khang SK. Spinal radiosurgical treatment for thoracic epidural cavernous hemangioma presenting as radiculomyelopathy: Technical case report. *Neurosurgery* 2009;64:E1202-3.
23. Lee JP, Wang AD, Wai YY, Ho YS. Spinal extradural cavernous hemangioma. *Surg Neurol* 1990;34:345-51.
24. Isoda H, Takahashi M, Mochizuki T, Ramsey RG, Masui T, Takehara Y, *et al.* MRI of dumbbell-shaped spinal tumors. *J Comput Assist Tomogr* 1996;20:573-82.