

## An Anterior Dislocation after Mobi-C Cervical Disc Arthroplasty

### Abstract

The objective is to report a case of an early dislocation of Mobi-C prosthesis used for the replacement of C4–C5 disc. A 57-year-old man who was operated 17 years before for C6–C7 fusion complained of cervicalgia associated with bilateral but predominantly right-sided brachialgia. Magnetic resonance imaging demonstrated central and foraminal stenosis in the C5–C6 segment and soft medial disc herniation in the C4–C5 segment. The patient was indicated for the placement of a cervical disc prosthesis C4–C5 and a C5–C6 arthrodesis. After 1 month of clinical improvement, the patient saw his pain reappearing as well as the presence of dysphagia not objectified before. The patient did not describe a traumatic context. The radiographic assessment showed an anterior dislocation of the prosthesis. The patient was reoperated, the prosthesis was removed, and cervical arthrodesis with iliac graft was performed. Although rare, this complication must be well known by surgeons performing cervical arthroplasty.

**Keywords:** Cervical disc arthroplasty, complication, dislocation, surgery revision

### Introduction

Since this technique is used, cervical arthroplasty has become increasingly important in the treatment of degenerative cervical disease. Now, the benefits of using cervical disc prostheses are well known. The main ones are the preservation of mobility in the treated segment as well as the reduction of risk of early degeneration of the adjacent segment. However, using such devices is not without risk of complications. Among these are heterotopic ossifications, decreased movement at the treated level, complications related to the implant.<sup>[1]</sup> Multiple implants are allowed on the market with different designs.<sup>[2]</sup>

We think favorable to report the case of one of our patients involving an early dislocation of Mobi-C prosthesis used for the replacement of C4–C5 disc.

### Case Report

We report a case of a 57-year-old patient who smokes and has other cardiovascular risk factors (diabetes, overweight, and dyslipidemia). The patient was operated 17 years before for C6–C7 fusion by tricortical iliac graft and plate for right brachialgia and neck pain due to a right C6–C7 disc herniation.

This is an open access journal, and articles are distributed under the terms of the Creative Commons Attribution-NonCommercial-ShareAlike 4.0 License, which allows others to remix, tweak, and build upon the work non-commercially, as long as appropriate credit is given and the new creations are licensed under the identical terms.

For reprints contact: WKHLRPMedknow\_reprints@wolterskluwer.com

The patient came for consultation in March 2018 for cervicalgia associated with bilateral but predominantly right-sided brachialgia resistant to well-managed medical treatment.

Magnetic resonance imaging demonstrated central and foraminal stenosis in the C5–C6 segment and soft medial disc herniation in the C4–C5 segment [Figure 1].

The patient was then indicated for the placement of a cervical disc prosthesis C4–C5 (Mobi C17/13 [Zimmer USA] height 5) and a C5–C6 arthrodesis in September 2018 by right cervicotomy to preserve a little mobility at the upper level. Satisfactory mobility was observed preoperatively at the C4–C5 level.

There was no problem during the procedure, and the patient was able to go out 1 day after surgery [Figure 2].

Initially, the patient described an improvement of his pain in the arms and was satisfied with the surgery. However, about a month after the operation, the patient saw his pain reappearing as well as the presence of dysphagia not objectified before. The patient did not describe a traumatic context. The radiographic assessment showed an anterior dislocation

**How to cite this article:** Pelletier Y, Gille O, Vital JM. An anterior dislocation after Mobi-C cervical disc arthroplasty. *Asian J Neurosurg* 2020;15:719-21.

**Submitted:** 08-Apr-2020 **Accepted:** 21-May-2020  
**Published:** 28-Aug-2020

**Yann Pelletier,  
Olivier Gille,  
Jean-Marc Vital**

*Department of Orthopaedic,  
Spine Unit, Pellegrin Hospital,  
CHU Bordeaux, Bordeaux,  
France*

#### Address for correspondence:

Dr. Yann Pelletier,  
Department of Orthopaedic,  
Spine Unit, Pellegrin Hospital,  
CHU Bordeaux, 33000  
Bordeaux, France. E-mail: yann.  
pelletier@hotmail.fr

#### Access this article online

**Website:** www.asianjns.org

**DOI:** 10.4103/ajns.AJNS\_147\_20

#### Quick Response Code:



of the prosthesis; the upper and lower plates had migrated forward [Figure 3].

Surgical revision was decided and performed 3 months after the previous operation. By right cervicotomy, the prosthesis was removed. We observed during the surgery that the prosthesis was completely dislocated into the soft parts and unsealed from the bone. After removal of the prosthesis, it

appeared that the upper plate of C5 was damaged. Then, we performed a C4–C5 arthrodesis using an iliac graft and a C4–C6 plate. The patient had completely recovered postoperatively from his symptoms with dysphagia and regressive brachialgia.

At the control consultation at 2 months of the operation, the clinical evolution is satisfying without reappearance of any symptom. Control anteroposterior and lateral X-rays [Figure 4] showed arthrodesis material in place.

### Discussion

Few cases are described in the literature concerning migrations of cervical disc prostheses. Most cases are described with another type of nonconstrained prosthesis, of traumatic origin<sup>[3]</sup> or not.<sup>[4,5]</sup> A case of anterior migration with a Mobi-C prosthesis has already been described by Tsermoulas and Bhattathiri,<sup>[6]</sup> and it is the only case that we have found. This describes an earlier expulsion of the lower plateau of the prosthesis without affecting the upper plateau.

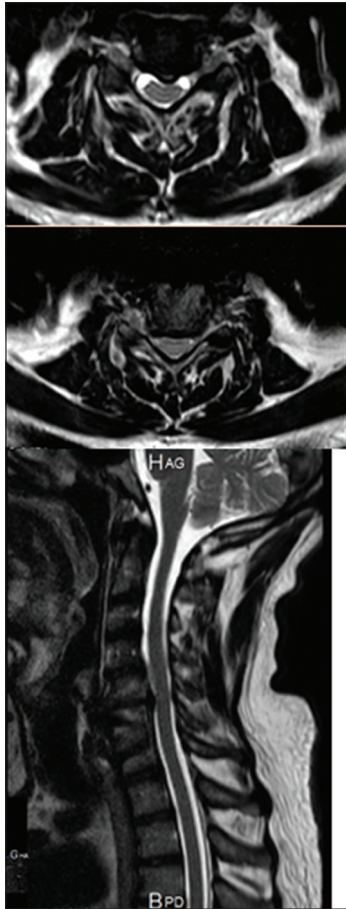


Figure 1: Magnetic resonance imaging T2 in sagittal and axial sections showing median C4–C5 hernia and bilateral C5–C6 foraminal stenosis

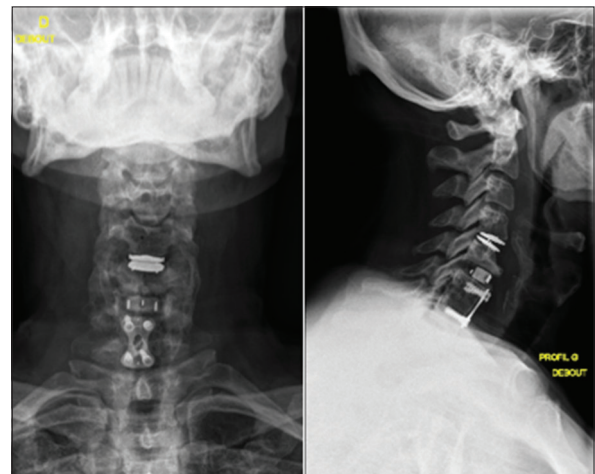


Figure 2: Anteroposterior and lateral X-rays after C5–C6 arthrodesis and C4–C5 arthroplasty

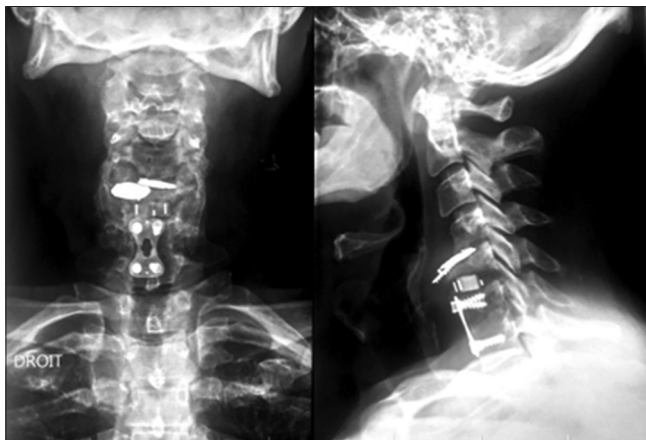


Figure 3: Anteroposterior and lateral X-rays at 3 months of prosthesis placement showing anterior dislocation of perilunate dislocation of the carp C4–C5

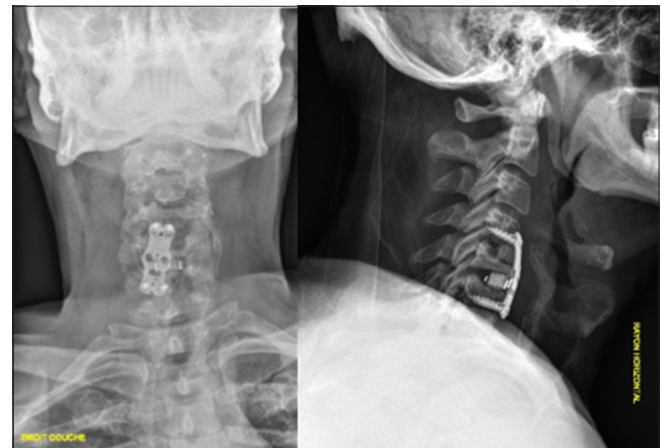

Figure 4: Anteroposterior and lateral X-rays after ablation of the prosthesis and arthrodesis by placing an iliac crest and an anterior plate

The Mobi-C prosthesis is a semi-constrained prosthesis consisting of a mobile polyethylene core and two chrome-cobalt plates.<sup>[7]</sup>

In our case, we have an early migration of the two plates of the prosthesis: upper and lower.

Analyzing more closely the complete file of the patient, we note that the upper plate of the C5 vertebra had a small anteroposterior diameter. This phenomenon had to participate in the early loosening of the prosthesis and the previous migration of the lower plate of the prosthesis. Immediate postoperative X-rays' control seems to be correct [Figure 3].

We have been overly optimistic about the indication of this double operative time and probably that an indication of setting up another arthrodesis at this level would have been more reasonable.

It should be noted that in our case, the symptoms not being as aggressive as those presented by the patient described by Tsermoulas and Bhattathiri,<sup>[6]</sup> revision surgery could be postponed and not performed in the context of the emergency.

The use of cervical disc prostheses is well codified, and soft cervical disc herniation is one of the main ones. The case of our patient corresponded well except that this case was more complex than a simple first surgery because of the multilevel disease.

#### **Declaration of patient consent**

The authors certify that they have obtained all appropriate patient consent forms. In the form the patient(s) has/have

given his/her/their consent for his/her/their images and other clinical information to be reported in the journal. The patients understand that their names and initials will not be published and due efforts will be made to conceal their identity, but anonymity cannot be guaranteed.

#### **Financial support and sponsorship**

Nil.

#### **Conflicts of interest**

There are no conflicts of interest.

#### **References**

1. Anderson PA, Nassr A, Currier BL, Sebastian AS, Arnold PM, Fehlings MG, *et al.* Evaluation of adverse events in total disc replacement: A meta-analysis of FDA summary of safety and effectiveness data. *Global Spine J* 2017;7:76S-83.
2. Staudt MD, Das K, Duggal N. Does design matter? Cervical disc replacements under review. *Neurosurg Rev* 2018;41:399-407.
3. Wagner SC, Kang DG, Helgeson MD. Traumatic migration of the Bryan cervical disc arthroplasty. *Global Spine J* 2016;6:e15-20.
4. Wagner SC, Kang DG, Helgeson MD. Implant migration after Bryan cervical disc arthroplasty. *Spine J* 2014;14:2513-4.
5. Zhai JL, Chang X, Hu JH, Weng XS. A case of implant migration following Bi-level cervical disc arthroplasty. *Chin Med J (Engl)* 2017;130:497-8.
6. Tsermoulas G, Bhattathiri PS. Anterior migration of prosthesis following cervical arthroplasty. *Br J Neurosurg* 2013;27:132-3.
7. Vital JM, Guerin P, Gille O, Pointillart V, Aurouer N, Obeid I. The Mobi-C®cervical disc prosthesis: Indications, technique and results. *Interact Surg* 2008;3:181-6.