

A Second Traumatic Cervical Spine Injury: Lighting Can Strike Twice

Sir,

A 53-year-old male had undergone C4–C5 discectomy, interbody grafting and C4–C5 fixation with anterior cervical plate and screws 4 years ago for a posttraumatic C4–C5 dislocation [Figure 1] following fall from a running train. At the time of presentation, he had neck pain, and only motor deficits were the weakness of right biceps and deltoid muscles. Postoperatively, he had a complete recovery.

Most patients would be careful after recovery from spinal injury. However, our patient was clearly a case of “once bitten, still not shy” and 4 years later (at the age of 57 years) he presented with a history of fall while trying to climb a moving bus and lost power in both lower limbs,

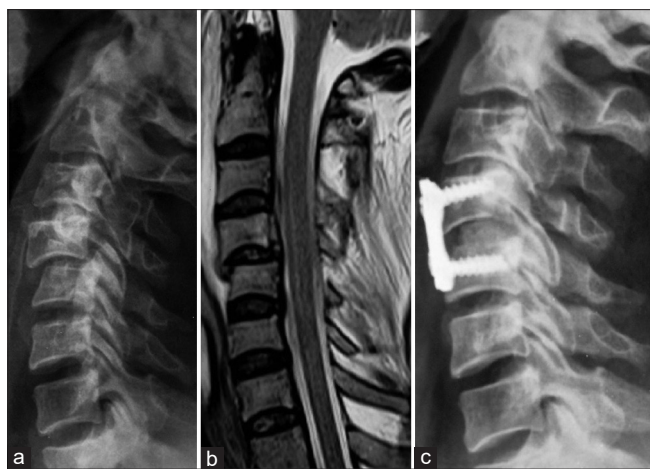

Figure 1: Images after the initial injury (a) X-ray cervical spine (lateral) showing a C4 on C5 subluxation; (b) T2 sagittal image showing dislocation with no cord signal change and (c) postoperative X-ray showing reduction with C4–C5 fixation with anterior cervical plate and screws with an interbody graft

bilateral wrists, and fingers and had decreased sensation below D4 dermatome. He also developed retention of urine and had to be catheterized. His plantars were bilaterally extensor. A magnetic resonance imaging of the cervical spine showed C5–C6 disc prolapse and extrusion with superior migration and tear of the posterior longitudinal ligament, causing cord compression with signal changes from C5 to C7 levels [Figure 2]. He underwent C5–C6 anterior cervical discectomy and grafting. It was planned to remove the previously inserted plates and revise with a longer construct. However, as the previously inserted plate could not be removed, we proceeded to do a posterior C5–C6 lateral mass fixation with C4–C6 laminectomy and decompression of thecal sac. He had slow neurological improvement and 1 year postoperatively he was off catheter, independently ambulant with a spastic gait and had regained some ability grip objects.

While cervical spine injuries are common in previously occurring in previously fused spines – whether congenital or following ankylosing spondylitis and have been described following surgery for nontraumatic conditions,^[1,2] a second traumatic cervical spinal injury is very rarely described in literature.^[3,4] In these reports,^[3,5] injuries occurred in patients who had previously been subjected to instrumented spinal fusion – for a C7–D1 dislocation in one case^[5] and for a D2 compression fracture in another.^[3] Both authors state that one of the causes of the second injury in their patients was the lack of mobility in the fused segments which caused excessive stress at the instant of trauma in adjacent mobile levels causing in one case a C5 burst fracture^[5] and in another a C5–C6 dislocation.^[3] Our patient too had undergone instrumented fusion at C4–C5 level, and the second injury occurred at the immediate lower level.

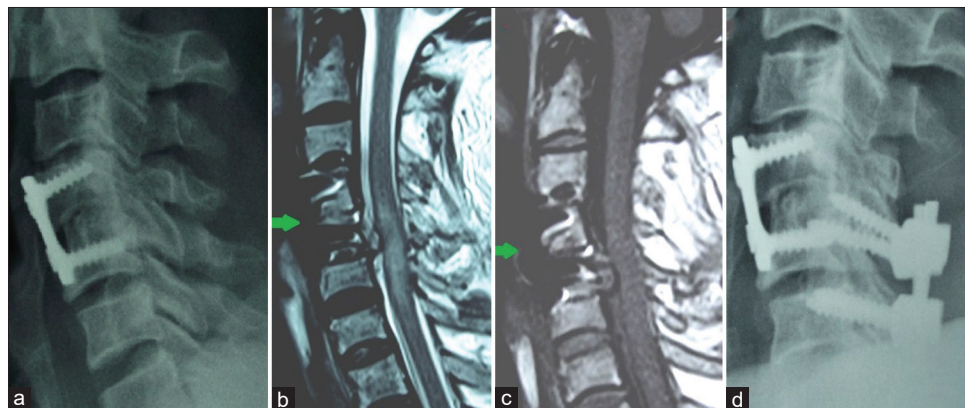


Figure 2: Images after the second injury (a) X-ray cervical spine (lateral) showing solid bony fusion between C4 and C5 with previous intact construct; (b) T2 sagittal and (c) images showing construct (green arrows), posterior longitudinal ligament injury and extensive cord signal changes with torn posterior longitudinal ligament and extruded disc fragment at C5–C6 level; (d) postoperative X-ray showing C4–C6 laminectomy with C5–C6 lateral mass screws *in situ* in addition to previously placed plates and screws

Adjacent segment degeneration (ASegD) after cervical fusion is a well-known entity^[2,4] and radiological ASegD is found in up to 47% of patients undergoing anterior cervical discectomy and fusion. Although speculative, it is probable our patient had developed an element of disc degeneration at C5–C6 level that led to its extrusion and cord compression following injury. Finally, despite having sustained a previous injury, our patient did not cease his unsafe travel practices. Alcohol consumption^[3] and thrill-seeking behaviour^[3] have previously been identified as predisposing factors for a second traumatic injury, and surgeons must be aware of these multiple factors and counsel at-risk patients accordingly.

Declaration of patient consent

The authors certify that they have obtained all appropriate patient consent forms. In the form the patient(s) has/have given his/her/their consent for his/her/their images and other clinical information to be reported in the journal. The patients understand that their names and initials will not be published and due efforts will be made to conceal their identity, but anonymity cannot be guaranteed.

Financial support and sponsorship

Nil.

Conflicts of interest

There are no conflicts of interest.

Prasad Krishnan

Department of Neurosurgery, National Neurosciences Centre, Kolkata, West Bengal, India

Address for correspondence:

*Dr. Prasad Krishnan,
Department of Neurosurgery, National Neurosciences Centre, Peerless Hospital Campus, 2nd Floor, 360 Panchasayar, Kolkata - 700 094, West Bengal, India.*

E-mail: prasad.krishnan@rediffmail.com

References

1. Raizman NM, Yu WD, Jenkins MV, Wallace MT, O'Brien JR. Traumatic C4-C5 unilateral facet dislocation with posterior disc herniation above a prior anterior fusion. *Am J Orthop (Belle Mead NJ)* 2012;41:E85-8.
2. Yokoyama K, Kawanishi M, Yamada M, Tanaka H, Ito Y, Kuroiwa T. Cervical facet dislocation adjacent to the fused motion segment. *J Neurosci Rural Pract* 2016;7:133-6.
3. Sliwa JA, Lim AC, Roth EJ. A second traumatic spinal cord injury: Associated risk factors. Case report and review. *Paraplegia* 1992;30:288-91.
4. Chung JY, Park JB, Seo HY, Kim SK. Adjacent segment pathology after anterior cervical fusion. *Asian Spine J* 2016;10:582-92.
5. Kafadar A, Gençosmanoğlu BE, Hancı M. A great misfortune: Second traumatic spinal cord injury. *Spinal Cord* 2002;40:37-9.

This is an open access journal, and articles are distributed under the terms of the Creative Commons Attribution-NonCommercial-ShareAlike 4.0 License, which allows others to remix, tweak, and build upon the work non-commercially, as long as appropriate credit is given and the new creations are licensed under the identical terms.

Access this article online	
Quick Response Code: 	Website: www.asianjns.org
	DOI: 10.4103/ajns.AJNS_134_20

How to cite this article: Krishnan P. A second traumatic cervical spine injury: Lighting can strike twice. <i>Asian J Neurosurg</i> 2020;15:462-3.	
Submitted: 03-Apr-2020	Accepted: 29-Apr-2020
Published: 29-May-2020	
© 2020 Asian Journal of Neurosurgery Published by Wolters Kluwer - Medknow	