

## Cervical Spinal Fracture in a Patient with Diffuse Idiopathic Skeletal Hyperostosis Having a History of Cervical Laminoplasty

### Abstract

An 87-year-old male having a history of C3–7 open-door cervical laminoplasty 20 years ago fell and sustained neck pain and paralysis with complete motor and sensory deficits below C6 (Frankel A). Computed tomography (CT) revealed ankylosis from C2 to C7 due to diffuse idiopathic skeletal hyperostosis (DISH) and a C5/6 fracture with C5 posterior displacement. We performed surgery the day after injury using a posterior approach for stabilization of the spinal column from C3 to T1. Translaminar screws (LS) were placed to the right (hinge side) of C3–7, lateral mass screws (LMS) to the left (open side) of C3–6, and pedicle screws to the left of C7 and bilaterally in T1. Bony fusion was achieved as seen on CT images 6 months after surgery. We conclude that long posterior stabilization using LMS and LS is an effective treatment for cervical fracture in patients with DISH having a history of cervical laminoplasty.

**Keywords:** Cervical fracture, cervical laminoplasty, diffuse idiopathic skeletal hyperostosis, posterior stabilization, screw insertion

### Introduction

Spinal fractures in diffuse idiopathic skeletal hyperostosis (DISH) usually arise secondary to minor trauma and occur most commonly in the cervical spine.<sup>[1]</sup> DISH is now recognized with increasing frequency in the elderly population. Similarly, cervical spondylotic myelopathy (CSM) is also frequently encountered in neurosurgical practice in the elderly population. Currently, laminoplasty for CSM is becoming a popular procedure.<sup>[2]</sup> However, a cervical fracture in patients with DISH having a history of cervical laminoplasty does not appear to have been reported.

This article describes a patient with DISH having a history of cervical laminoplasty who sustained a cervical vertebral fracture.

### Case Report

An 87-year-old male having a history of C3–7 open-door cervical laminoplasty<sup>[3]</sup> 20 years ago fell from the second floor and sustained neck pain and paralysis with complete motor and sensory deficits below C6 (Frankel A). Computed tomography (CT) revealed ankylosis from C2 to C7 due to DISH, slight ossification

of the posterior longitudinal ligament at C2–5, and a C5/6 fracture with C5 posterior displacement [Figure 1a]. The previously operated laminae were ankylosed and thickened on CT [Figure 1b and c]. CT revealed a three-column fracture from the vertebral body to the ankylosed laminae [Figure 1a and b]. The contrast-enhanced CT revealed a thick vein dorsal to the right laminae [Figure 1d]. Magnetic resonance imaging could not be obtained because a brain clip had been implanted.

We performed surgery the day after injury using a posterior approach for stabilization of the spinal column from C3 to T1. First, we stripped only the left side muscles from C3 to C5 and muscles bilaterally from C6 to T1 through a midline incision because a thick vein existed dorsal to the right laminae from C3 to C5. Translaminar screws (LS) were placed to the right (hinge side) of C3–7, lateral mass screws (LMS) to the left (open side) of C3–6, and pedicle screws (PS) to the left of C7 and bilaterally in T1. Titanium rods were assembled from C3 to T1 bilaterally [Figure 2a-d]. Bony fusion was achieved as seen on CT images 6 months after surgery [Figure 3]. However,

### Takeshi Sasagawa

Department of Orthopedics  
Surgery, Toyama Prefectural  
Central Hospital, Toyama,  
Japan

#### Address for correspondence:

Dr. Takeshi Sasagawa,  
Toyama Prefectural Central  
Hospital, Toyama, Japan.  
E-mail: sasagawawagasasa@  
yahoo.co.jp

#### Access this article online

Website: [www.asianjns.org](http://www.asianjns.org)

DOI: 10.4103/ajns.AJNS\_125\_20

#### Quick Response Code:



**How to cite this article:** Sasagawa T. Cervical spinal fracture in a patient with diffuse idiopathic skeletal hyperostosis having a history of cervical laminoplasty. *Asian J Neurosurg* 2020;15:703-5.

Submitted: 31-Mar-2020      Revised: 19-Apr-2020  
Accepted: 25-Apr-2020      Published: 28-Aug-2020

This is an open access journal, and articles are distributed under the terms of the Creative Commons Attribution-NonCommercial-ShareAlike 4.0 License, which allows others to remix, tweak, and build upon the work non-commercially, as long as appropriate credit is given and the new creations are licensed under the identical terms.

For reprints contact: [WKHLRPMedknow\\_reprints@wolterskluwer.com](mailto:WKHLRPMedknow_reprints@wolterskluwer.com)

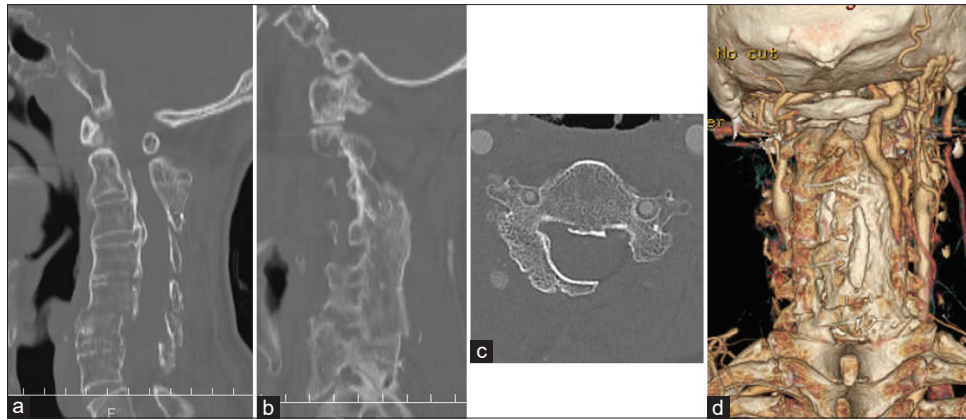


Figure 1: Initial computed tomography image. (a) Midline sagittal image. (b) Parasagittal image. (c) Axial view. (d) Three-dimensional computed tomography

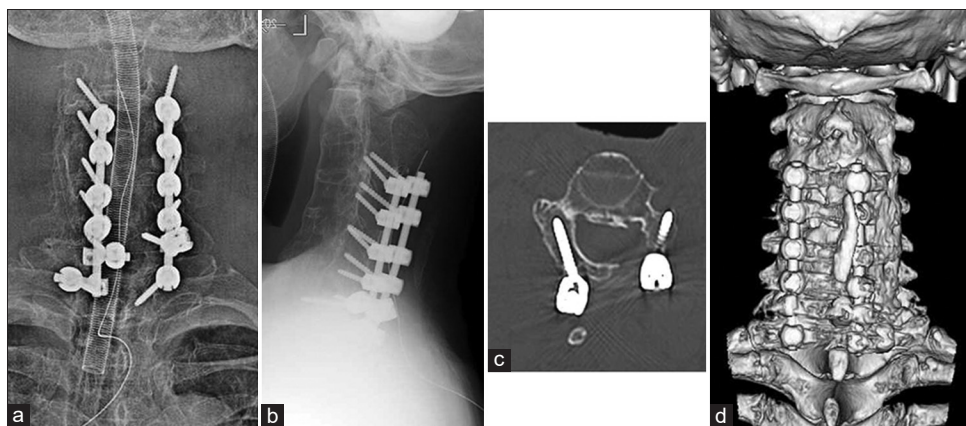


Figure 2: Postoperative X-ray image. (a) Frontal view. (b) Lateral view. (c) Computed tomography axial view. (d) Three-dimensional computed tomography

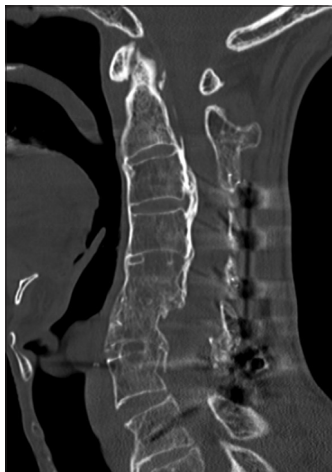

Figure 3: Computed tomography image 6 months postoperatively: Midline sagittal image

no neurological improvement was observed up to 3 years postoperatively.

### Discussion

In general, hyperostosis at the cervical level is symmetrically distributed anterior to the vertebral bodies without a flowing pattern.<sup>[4]</sup> The patient in our report

had a history of laminoplasty before the hyperostosis. Hyperostosis and ankylosis occurred not only in the vertebral bodies but also in the previously operated laminae. Spinal fractures related to DISH are almost always an anterior to posterior transverse injury.<sup>[1]</sup> The patient in our report also sustained a three-column fracture from the vertebral body to ankylosed laminae.

Most DISH fractures are unstable because of long lever arms and an anterior to posterior transverse injury. Therefore, posterior instrumentation is regarded as the standard treatment for fracture in a patient with DISH.<sup>[5]</sup> In general, it has been reported that fusion of three segments above and below the fracture is reliable for the range of fusion for fractures with DISH.<sup>[1]</sup> Therefore, many screw insertions are needed for long posterior stabilization. There are several kinds of screws for posterior cervical instrumentation, such as LMS, PS, and LS.<sup>[6]</sup> However, in patients having a history of cervical spine surgery, the exact insertion of a cervical screw is technically demanding, especially when normal anatomic landmarks have been obscured and are difficult to identify.<sup>[7]</sup> In this case, we chose LMS at the open side and LS at the hinge side because PS or LMS insertion at the hinge side was considered difficult

due to the abnormal anatomic shape of the lamina and the existence of a thick vein on the right side. On the other hand, insertion of LS on the hinge side was not difficult because the laminae were hyperostotic. Good clinical results for cervical stabilization using LMS<sup>[8]</sup> and subaxial LS<sup>[9,10]</sup> have been reported. Although osteoporosis is frequently associated with DISH,<sup>[2]</sup> bony fusion was achieved in this case. This supports that long posterior stabilization using a combination of LMS and subaxial LS is sufficient fixation for cervical fractures in patients with DISH. We conclude that long posterior stabilization using LMS and LS is an effective treatment for cervical fracture in patients with DISH having a history of cervical laminoplasty.

In this case, although the spinal canal had been enlarged by cervical laminoplasty, spinal cord injury due to cervical fracture occurred. As reported previously in DISH fracture with neurological deficits, there are only a few cases in which neurological deficits improved after surgical treatment.<sup>[11,12]</sup> No neurological improvement was observed up to 3 years postoperatively in this case. Cervical fractures in patients with DISH remain a threat for spinal cord injury even in cases in which the spinal canal had been enlarged by cervical laminoplasty.

Informed consent was obtained from the patient and his family.

#### Declaration of patient consent

The authors certify that they have obtained all appropriate patient consent forms. In the form, the patient has given his consent for his images and other clinical information to be reported in the journal. The patient understands that name and initials will not be published and due efforts will be made to conceal identity, but anonymity cannot be guaranteed.

#### Financial support and sponsorship

Nil.

#### Conflicts of interest

There are no conflicts of interest.

## References

1. Caron T, Bransford R, Nguyen Q, Agel J, Chapman J, Bellabarba C. Spine fractures in patients with ankylosing spinal disorders. *Spine (Phila Pa 1976)* 2010;35:E458-64.
2. Veeravagu A, Azad TD, Zhang M, Li A, Pendharkar AV, Ratliff JK, *et al.* Outcomes of cervical laminoplasty—Population-level analysis of a national longitudinal database. *J Clin Neurosci* 2018;48:66-70.
3. Kurokawa R, Kim P. Cervical laminoplasty: The history and the future. *Neurol Med Chir (Tokyo)* 2015;55:529-39.
4. Bakker JT, Kuperus JS, Kuijff HJ, Oner FC, de Jong PA, Verlaan JJ. Morphological characteristics of diffuse idiopathic skeletal hyperostosis in the cervical spine. *PLoS One* 2017;12:e0188414.
5. Robinson Y, Robinson AL, Olerud C. Complications and survival after long posterior instrumentation of cervical and cervicothoracic fractures related to ankylosing spondylitis or diffuse idiopathic skeletal hyperostosis. *Spine (Phila Pa 1976)* 2015;40:E227-33.
6. Pelton MA, Schwartz J, Singh K. Subaxial cervical and cervicothoracic fixation techniques—indications, techniques, and outcomes. *Orthop Clin North Am* 2012;43:19-28, vii.
7. Seichi A, Takeshita K, Nakajima S, Akune T, Kawaguchi H, Nakamura K. Revision cervical spine surgery using transarticular or pedicle screws under a computer-assisted image-guidance system. *J Orthop Sci* 2005;10:385-90.
8. Coe JD, Vaccaro AR, Dailey AT, Skolasky RL Jr, Sasso RC, Ludwig SC, *et al.* Lateral mass screw fixation in the cervical spine: A systematic literature review. *J Bone Joint Surg Am* 2013;95:2136-43.
9. Shi L, Shen K, Chu L, Yu KX, Yu QS, Deng R, *et al.* Biomechanical study of novel unilateral fixation combining unilateral pedicle and contralateral translaminar screws in the subaxial cervical spine. *World Neurosurg* 2019;121:e684-90.
10. Alvin MD, Abdullah KG, Steinmetz MP, Lubelski D, Nowacki AS, Benzel EC, *et al.* Translaminar screw fixation in the subaxial cervical spine: Quantitative laminar analysis and feasibility of unilateral and bilateral translaminar virtual screw placement. *Spine (Phila Pa 1976)* 2012;37:E745-51.
11. Westerveld LA, Verlaan JJ, Oner FC. Spinal fractures in patients with ankylosing spinal disorders: A systematic review of the literature on treatment, neurological status and complications. *Eur Spine J* 2009;18:145-56.
12. Balling H, Weckbach A. Hyperextension injuries of the thoracolumbar spine in diffuse idiopathic skeletal hyperostosis. *Spine (Phila Pa 1976)* 2015;40:E61-7.