

## A Case Study on Aneurysmal Bone Cyst of T2 Vertebral Body in a 7-Year-Old Girl: Anterior and Posterior Surgical Approach for Tumor Resection and Spinal Reconstruction

### Abstract

Aneurysmal bone cyst (ABC) is defined as a benign lesion of bone containing blood-filled channels divided by soft-tissue septa and mostly diagnosed in children and adolescents. In the present study, the case of a 7-year-old girl with spastic paraparesis and left foot drop was investigated. Spinal imaging revealed a large lytic mass in the posterior elements of the T2 vertebral body, which resulted in the partial collapse of the T2 vertebral body, a T1 to T3 dislocation, and a spinal sagittal imbalance. The patient underwent a two-stage surgical procedure including an anterior T2 corpectomy, T1/T2 and T2/T3 discectomy, anterior instrumentation, posterior total tumor resection, and posterior fixation with laminar hooks. Postoperative imaging demonstrated cord decompression and good spinal alignment. Although a spinal ABC is a rare entity, it can occur in any segment of the spinal column and cause cord compression and spinal instability. Thus, proper treatment planning is crucial for total tumor resection to avoid tumor recurrence and correct spinal imbalance.

**Keywords:** *Aneurysmal bone cyst, anterior surgical approach, posterior surgical approach, spinal imbalance*

### Introduction

Aneurysmal bone cyst (ABC) is benign expansile tumor-like bone lesions of uncertain etiology, composed of numerous blood-filled channels divided by soft-tissue septa.<sup>[1]</sup> ABC is a relatively rare entity that is found in 1.4% of all primary bone tumors.<sup>[2]</sup> Long bones are the most common site of this tumor, but the spinal column is involved in 14% of cases.<sup>[3]</sup> This tumor is more often found in females than in males and presents in almost all cases in the second decade of life.<sup>[3]</sup> ABC seldom occurs in the cervicothoracic region (C7 to T2). Only 19 cases of ABC have been reported through 2013.<sup>[2]</sup> Here, we report a child with T2 involvement and spinal sagittal imbalance and the associated surgical approach. This study was approved by the institutional review board. Informed consent from the patient's parents was taken before writing and publishing this report and all of the data.

### Case Report

In the present study, the case of a 7-year-old girl with left leg weakness

and gait disturbance was investigated. A physical examination demonstrated muscle force values of 4/5, 4/5, and 0/5 for the right leg, the proximal, and distal left leg, respectively. These muscle force values are associated with spastic paraparesis and kyphotic deformity in the cervicothoracic region. Spinal imaging revealed a large lytic mass in the posterior elements of the T2 vertebral body associated with both pedicle and vertebral body involvement, resulting in partial collapse of the T2 vertebral body, T1 to T3 dislocation, and spinal sagittal imbalance [Figure 1]. Magnetic resonance imaging revealed a cerebrospinal fluid block and significant cord compression at the level of T2 [Figure 1]. The patient was a candidate for the three-stage posterior, anterior, and posterior surgical approach. The first surgery was performed with the patient in a prone position and a midline incision was made over the cervicothoracic area, and a purple, hemorrhagic, and destructive mass was observed on the posterior elements of T2. After conducting T2 laminectomy, the accessible sections of the tumor were completely resected. Spinal fusion was postponed after anterior

**Mansour Parvaresh,  
Morteza Taheri,  
Alireza Azimi, Sadra  
Rohani<sup>1</sup>**

*Department of Neurosurgery,  
Iran University of Medical  
Sciences, Tehran, <sup>1</sup>Department  
of Neurosurgery, Birjand  
University of Medical Sciences,  
Iran*

### Address for correspondence:

*Dr. Morteza Taheri,  
Neurosurgeon, Department of  
Neurosurgery, Iran University of  
Medical Sciences, Tehran, Iran.  
E-mail: drtaheri38@yahoo.com*

### Access this article online

**Website:** [www.asianjns.org](http://www.asianjns.org)

**DOI:** 10.4103/ajns.AJNS\_120\_17

### Quick Response Code:



**How to cite this article:** Parvaresh M, Taheri M, Azimi A, Rohani S. A case study on aneurysmal bone cyst of T2 vertebral body in a 7-year-old girl: Anterior and posterior surgical approach for tumor resection and spinal reconstruction. *Asian J Neurosurg* 2019;14:985-8.

This is an open access journal, and articles are distributed under the terms of the Creative Commons Attribution-NonCommercial-ShareAlike 4.0 License, which allows others to remix, tweak, and build upon the work non-commercially, as long as appropriate credit is given and the new creations are licensed under the identical terms.

**For reprints contact:** [reprints@medknow.com](mailto:reprints@medknow.com)

approach. Five days later, in the second session, a right side anterolateral and suprasternal approach was performed with the patient in a supine position. After skin incision, blunt dissection was carried out in the plane between sternocleidomastoid, laterally and tracheoesophageal fascia, medially. After dissection of the internal carotid, vertebral artery and aortic arch and access to the anterior part of the spinal column, complete corpectomy of T2 associated with T1/T2 and T2/T3 discectomy were performed [Figure 2]. Anterior fusion through an expandable corpectomy cage was done. In the same session, with the patient in a prone position, a previous midline incision was reopened, and soft tissue dissection was performed. Posterior segmental fixation through insertion of a laminar hook into C7, T1, T3, T4, and T5 was conducted. The sagittal imbalance was corrected using a hook and rods and anterior fusion was reinforced with posterior fixation. The postoperative CT scan revealed correction of the spinal deformity [Figure 3]. The histopathological findings were consistent with ABC. The patient's neurological status gradually improved postoperatively. After 11-month follow-up, the lower limb weakness completely improved, and no recurrence occurred during 24-month follow-up.

## Discussion

ABCs consist of blood-filled spaces that are separated by connective tissue containing fibroblasts, osteoblast-type giant cells, and reactive woven bone.<sup>[1]</sup> Long bones are the most common site of this tumor, but the spinal column is involved in 14% of cases.<sup>[3]</sup> The most common site of involvement in the spine is the dorsal and lumbosacral regions and cervicothoracic region (from C7 to T2) involvement is rare.<sup>[2,4]</sup>

The literature review revealed that only 22 cases of ABC in the cervicothoracic junction have been reported to date. The research showed that ABC in the cervicothoracic, most commonly involved C7 (12 cases), T1 (10 cases), and T2 (8 cases).

The mean age of patients was 16.8 years with a range of 2–36 years. Among 22 cases, 5 patients were <10 years old, 12 patients were from 10 to 20 years old, and 5 patients were >20 years old. Besides, 8 and 14 patients were male and female, respectively. Only in five patients, the spinal deformity was observed including three cases with kyphosis and two cases with scoliosis. In three patients, a three-stage approach involving posterior resection, anterior resection, and fusion followed by posterior fusion was performed. Tables 1 and 2 summarize some features of previous case reports and present case.

In our case, the patient was only 7 years old with lower limb paresis and spinal kyphosis. To achieve total resection, spinal reconstruction, and fusion, a three-stage surgical approach was performed including posterior resection, anterior resection/fusion, and posterior fusion. Regarding

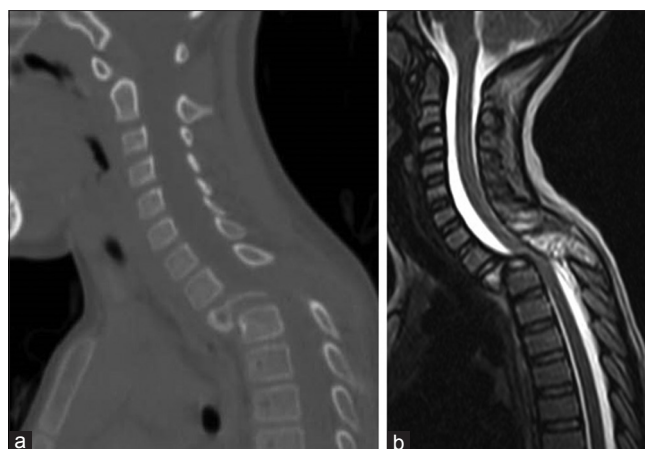


Figure 1: (a) The computed tomography scan with sagittal reconstruction of spinal column and (b) sagittal T2 images sequences before surgery

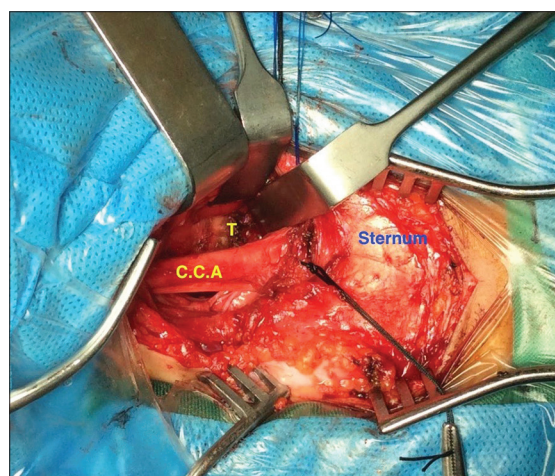


Figure 2: An intraoperative photograph showing anterior approach for T2 corpectomy. CCA: Common carotid artery, T: Tumor of T2 vertebrae

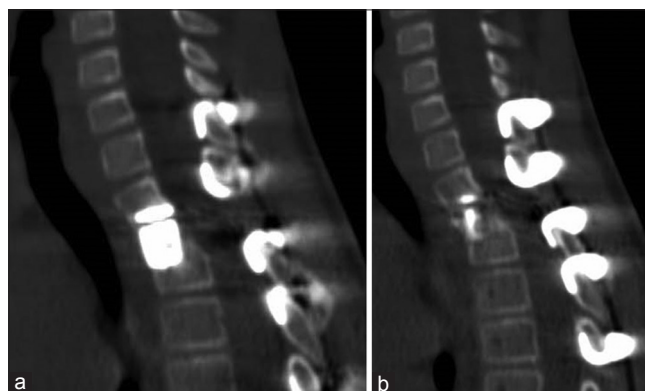


Figure 3: (a and b) Sagittal reconstruction of the spinal column after surgery

spinal deformities, the present study is similar to the cases reported by Stillwell and Fielding,<sup>[8]</sup> Boriani *et al.*,<sup>[17]</sup> and Rahimizadeh *et al.*<sup>[2]</sup> In the view of the surgical approach, our case is similar to the studies published by Disch *et al.*,<sup>[11]</sup> McDonald *et al.*,<sup>[13]</sup> and Garneti *et al.*<sup>[18]</sup> Regarding age, our case is similar to the studies published by Dick *et al.*,<sup>[7]</sup> Disch *et al.*,<sup>[11]</sup> and Zileli *et al.*<sup>[20]</sup> Stillwell

**Table 1: Comparison of the level of involvement, age, and sex in our case and previous studies**

Study number	Study	Level of involvement				Age groups				Sex	
		Cervicothoracic	C7	T1	T2	Age	<10	11-20	>20	Male	Female
1	Verbiest 1965 <sup>[5]</sup>	T1/T2		*	*	15		*		*	
2	Hay et al., 1978 <sup>[6]</sup>	C7		*		10	*				*
	Hay et al., 1978	C6/C7		*		24			*		*
	Hay et al., 1978	T2/T3			*	36			*	*	
3	Dick et al., 1979 <sup>[7]</sup>	C7		*		7	*				*
4	Stillwell and Fielding 1984 <sup>[8]</sup>	C7/T1/T2		*	*	23			*		*
5	Ameli et al., 1985 <sup>[9]</sup>	C6/C7		*		35			*		*
	Ameli et al., 1985	C7/T1		*	*	20		*		*	
	Ameli et al., 1985	T1		*		13		*			*
6	Capanna et al., 1985 <sup>[10]</sup>	T1/T2		*	*	14		*			*
7	Disch et al., 1986 <sup>[11]</sup>	T1		*		8	*				*
8	Ohry et al., 1988 <sup>[12]</sup>	C7		*		18		*		*	
9	McDonald et al., 1992 <sup>[13]</sup>	T1		*		14		*			*
10	Gupta et al., 1994 <sup>[14]</sup>	T1/2		*	*	19		*		*	
11	De Kleuver et al., 1998 <sup>[15]</sup>	T2			*	14		*			*
12	Ozaki et al., 1999 <sup>[16]</sup>	T2			*	36			*	*	
13	Boriani et al., 2001 <sup>[17]</sup>	T1		*		14		*			*
	Boriani et al., 2001	C7		*		17		*		*	
14	Garneti et al., 2003 <sup>[18]</sup>	C7		*		11		*			*
15	Deo et al., 2005 <sup>[19]</sup>	C7		*		2	*				*
16	Zileli et al., 2007 <sup>[20]</sup>	C7/T1/T2		*	*	7	*			*	
17	Rahimizadeh et al., 2013 <sup>[2]</sup>	C7		*		14		*			*
18	Our study	T2			*	7	*				*
23	Total	C7 to T2	12	10	9	2-36	6	12	5	8	15

**Table 2: Comparison of the surgical approach in our case and previous studies**

Treatment modality					Important clinical features		
Only ant (one stage)	Ant and post (two stages)	Post, ant, and post (three stages)	Only radiotherapy	Post and radiotherapy	Kyphosis	Scoliosis	Horner syndrome
Verbiest et al.	Dick et al.	Disch et al.	Ameli et al.	Ameli et al.	Stillwell et al.	Verbiest et al.	Disch et al.
Hay et al.	Stillwell et al.	McDonald et al.		Capana et al.	Boriani et al.	Boriani et al.	Ohry et al.
Hay et al.	Deo et al.	Garneti et al.		Boriani et al.	Rahimizadeh et al.		
Hay et al.	Zileli et al.	Our study		Boriani et al.	Our study		
Ameli et al.	Rahimizadeh et al.						
Ohry et al.							
Gupta et al.							
Kleuver et al.							
Ozaki et al.							

and Fielding reported a 23-year-old female with ABC at the C7/T1/T2 level. The patient with spinal kyphosis was treated with a two-stage anterior and posterior surgical approach; no tumor recurrence was observed after 8 years of follow-up.<sup>[8]</sup> In 2001, Boriani et al. reported a 17-year-old male with an ABC at the C7 level and with spinal kyphosis who was treated by posterior curettage and radiotherapy.<sup>[17]</sup> Rahimizadeh et al. reported a case of ABC at the C7 level. The patient was subjected to a two-stage anterior and posterior surgical approach and no recurrence after 1-year follow-up was exhibited.<sup>[2]</sup> Disch et al. and McDonald et al. reported 8- and 14-year-old females with an ABC at T1 who were treated using a three-stage (posterior, anterior,

and posterior) surgical approach.<sup>[11,13]</sup> In Garneti's study, an 11-year-old female with an ABC at C7 was treated with a three-stage (posterior, anterior, and posterior) approach.<sup>[18]</sup>

One of the most common factors for tumor recurrence is the extent of tumor resection. The recurrence rate is approximately 34% following curettage treatment alone. Zenonos et al. reported that in 2 of 14 patients recurrence was observed due to the lack of total resection.<sup>[1]</sup> Knoeller reported a case of an ABC patient who underwent subtotal resection and exhibited recurrence after 3 months.<sup>[21]</sup> However, some authors could achieve total tumor resection and demonstrated no tumor recurrence after 1- to 17-year follow-up.<sup>[2,5,8,18,19]</sup>

## Conclusion

Although a spinal ABC is a rare entity, it can occur in any segment of the spinal column and cause cord compression and spinal instability. Thus, proper treatment planning is crucial for total tumor resection to avoid tumor recurrence and correct spinal imbalance.

## Declaration of patient consent

The authors certify that they have obtained all appropriate patient consent forms. In the form the patient(s) has/have given his/her/their consent for his/her/their images and other clinical information to be reported in the journal. The patients understand that their names and initials will not be published and due efforts will be made to conceal their identity, but anonymity cannot be guaranteed.

## Financial support and sponsorship

Nil.

## Conflicts of interest

There are no conflicts of interest.

## References

- Zenonos G, Jamil O, Governale LS, Jernigan S, Hedequist D, Proctor MR, *et al.* Surgical treatment for primary spinal aneurysmal bone cysts: Experience from children's hospital Boston. *J Neurosurg Pediatr* 2012;9:305-15.
- Rahimizadeh A, Taghinedjadi O, Rahimizadeh A. One stage management of aggressive cervicothoracic aneurysmal bone cyst in a 14-year old girl: Report of a case and review of the literature. *World Spinal Column J* 2013;4:109-19.
- Pennekamp W, Peters S, Schinkel C, Kuhnen C, Nicolas V, Muhr G, *et al.* Aneurysmal bone cyst of the cervical spine (2008:7b). *Eur Radiol* 2008;18:2356-60.
- Khalil IM, Alaraj AM, Otrrock ZK, Chamoun RB, Sabbagh AS, Skaf GS, *et al.* Aneurysmal bone cyst of the cervical spine in a child: Case report and review of the surgical role. *Surg Neurol* 2006;65:298-303.
- Verbiest H. Giant-cell tumours and aneurysmal bone cysts of the spine. With special reference to the problems related to the removal of a vertebral body. *J Bone Joint Surg Br* 1965;47:699-713.
- Hay MC, Paterson D, Taylor TK. Aneurysmal bone cysts of the spine. *J Bone Joint Surg Br* 1978;60-B: 406-11.
- Dick HM, Bigliani LU, Michelsen WJ, Johnston AD, Stinchfield FE. Adjuvant arterial embolization in the treatment of benign primary bone tumors in children. *Clin Orthop Relat Res* 1979;139:133-41.
- Stillwell WT, Fielding JW. Aneurysmal bone cyst of the cervicodorsal spine. *Clin Orthop Relat Res* 1984;187:144-6.
- Ameli NO, Abbassioun K, Saleh H, Eslamdoost A. Aneurysmal bone cysts of the spine. Report of 17 cases. *J Neurosurg* 1985;63:685-90.
- Capanna R, Albisinni U, Picci P, Calderoni P, Campanacci M, Springfield DS, *et al.* Aneurysmal bone cyst of the spine. *J Bone Joint Surg Am* 1985;67:527-31.
- Disch SP, Grubb RL Jr., Gado MH, Strecker WB, Marbarger JP. Aneurysmal bone cyst of the cervicothoracic spine: Computed tomographic evaluation of the value of preoperative embolization. Case report. *Neurosurgery* 1986;19:290-3.
- Ohry A, Lipschitz M, Shemesh Y, Lipschitz L, Tadmor R. Disappearance of quadriplegia due to a huge cervicothoracic aneurysmal bone cyst. *Surg Neurol* 1988;29:307-10.
- McDonald P, Letts M, Sutherland G, Unruh H. Aneurysmal bone cyst of the upper thoracic spine. An operative approach through a manubrial sternotomy. *Clin Orthop Relat Res* 1992;279:127-32.
- Gupta VK, Gupta SK, Khosla VK, Vashisth RK, Kak VK. Aneurysmal bone cysts of the spine. *Surg Neurol* 1994;42:428-32.
- de Kleuver M, van der Heul RO, Veraart BE. Aneurysmal bone cyst of the spine: 31 cases and the importance of the surgical approach. *J Pediatr Orthop B* 1998;7:286-92.
- Ozaki T, Halm H, Hillmann A, Blasius S, Winkelmann W. Aneurysmal bone cysts of the spine. *Arch Orthop Trauma Surg* 1999;119:159-62.
- Boriani S, De Iure F, Campanacci L, Gasbarrini A, Bandiera S, Biagini R, *et al.* Aneurysmal bone cyst of the mobile spine: Report on 41 cases. *Spine (Phila Pa 1976)* 2001;26:27-35.
- Garneti N, Dunn D, El Gamal E, Williams DA, Nelson IW, Sandemon DR, *et al.* Cervical spondyloptosis caused by an aneurysmal bone cyst: A case report. *Spine (Phila Pa 1976)* 2003;28:E68-70.
- Deo SD, Fairbank JC, Wilson-Macdonald J, Richards P, Pike M, Athanasou N, *et al.* Aneurysmal bone cyst as a rare cause of spinal cord compression in a young child. *Spine (Phila Pa 1976)* 2005;30:E80-2.
- Zileli M, Kiliçer C, Ersahin Y, Cagli S. Primary tumors of the cervical spine: A retrospective review of 35 surgically managed cases. *Spine J* 2007;7:165-73.
- Knoeller SM, Uhl M, Adler CP. Aneurysmal bone cyst in a lumbar pedicle of a child. *SICOT Online Rep* 2003;E037:5.