

# Acute Calcific Discitis or Symptomatic Calcified Schmorl's Node of the Upper Thoracic Spine in an Adult: A Case Report and Literature Review

## Abstract

We describe a patient with acute calcific discitis following symptomatic Schmorl's node (SN) of upper thoracic spine. A 28-year-old female suffered from sudden severe pain in mid-thoracic, left scapular area, radiating to her chest. Plain radiography of the thoracic spine showed calcification in T3–4 intervertebral disc space. Computed tomography (CT) scan and magnetic resonance imaging (MRI) of the spine demonstrated calcification of the T3–T4 nucleus pulposus, migrating into the inferior of T3 vertebral body with reactive bone marrow edema. By conservative treatment with multidrug therapy, the pain subsided and disappeared in 3 months. Follow-up CT scan and MRI of the thoracic spine confirmed complete resolution of calcified SN and reactive bone marrow edema.

**Keywords:** *Acute calcific discitis, adult, spontaneous regression, symptomatic Schmorl's node, upper thoracic spine*

**Prasert  
Iampreechakul,  
Punjama  
Lertbutsayanukul<sup>1</sup>,  
Narupat  
Suanprasert<sup>2</sup>**

*Departments of Neurosurgery,  
<sup>1</sup>Neuroradiology and <sup>2</sup>Neurology,  
Prasat Neurological Institute,  
Bangkok, Thailand*

## Introduction

Schmorl's nodes (SNs) are protrusions of nucleus pulposus or intervertebral disc tissue through gap or weakening of the cartilaginous endplate and subchondral bone into the adjacent vertebral body. Most SNs affect the inferior endplate adjacent to the nucleus pulposus. Common locations of SNs were lower thoracic and upper lumbar spine.<sup>[1]</sup> Calcific discitis with intervertebral migration is one kind of findings of the several faces of SN.<sup>[2,3]</sup>

Calcific discitis was characteristic by central calcification confined within the nucleus pulposus distinguish from the more common degenerative intervertebral disc calcification, involving primarily the annulus fibrosus with low regression rate of hard herniated disc.<sup>[4,5]</sup> Adult calcific discitis is much less frequently reported than pediatric calcific discitis. Most previously studies reported this adult condition located at middle or lower thoracic spine.<sup>[4,6-9]</sup> We describe a young female with spontaneous regression of the calcification of nucleus pulposus following acute symptomatic regression of the calcification of nucleus pulposus following acute symptomatic calcified SN. To the best of our knowledge, our patient is the first report of acute calcific discitis in the upper thoracic spine. We also review the literature of calcification

of nucleus pulposus and/or calcific discitis in adult patients.

## Case Report

A 28-year-old female, during her neurology residency training program, had experienced and suffered from several episodes of heavy pain at both shoulder blades, left more than the right side. The pain was usually worse during her activities and relieved by lying down. The initial diagnosis was myofascial pain syndrome, treated by physiotherapy. Three months later, the patient was admitted to Prasat Neurological Institute following sudden severe pain in mid-thoracic, left scapular area, radiating to her chest in 1 day morning. The patient felt like her upper back splitting and tightness around her back and chest above nipple line. She was unable to get up from her bed secondary to pain with pain score of 10/10. The pain was increased by coughing or deep breathing. She had no underlying disease, and any trauma or obvious precipitating event prior to the onset of these symptoms. No muscle weakness or bowel/bladder dysfunction was complained. On neurological examination, there was no any neurological deficit. Sensory was intact. The results of laboratory findings were within normal limits. On the same day of acute severe pain, plain radiography, magnetic resonance imaging (MRI), and

**Address for correspondence:**  
Dr. Prasert Iampreechakul,  
Department of Neurosurgery,  
Prasat Neurological Institute,  
312 Rachawithi Road,  
Khwaeng Thung Phaya Thai,  
Bangkok 10400, Thailand.  
E-mail: bangruad@hotmail.com

### Access this article online

**Website:** [www.asianjns.org](http://www.asianjns.org)

**DOI:** 10.4103/ajns.AJNS\_119\_19

### Quick Response Code:



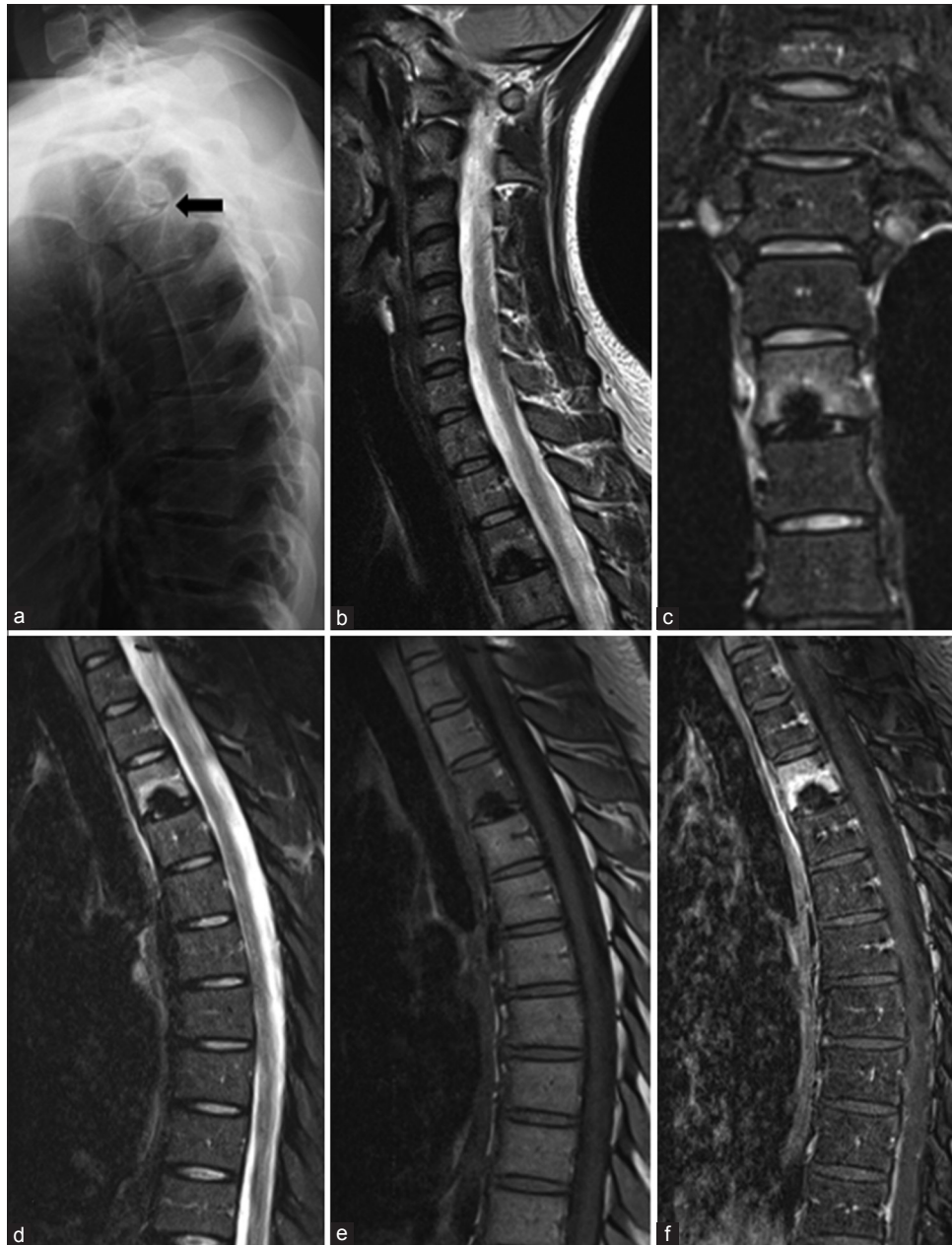**How to cite this article:** Iampreechakul P, Lertbutsayanukul P, Suanprasert N. Acute calcific discitis or symptomatic calcified Schmorl's node of the upper thoracic spine in an adult: A case report and literature review. *Asian J Neurosurg* 2019;14:1021-9.

This is an open access journal, and articles are distributed under the terms of the Creative Commons Attribution-NonCommercial-ShareAlike 4.0 License, which allows others to remix, tweak, and build upon the work non-commercially, as long as appropriate credit is given and the new creations are licensed under the identical terms.

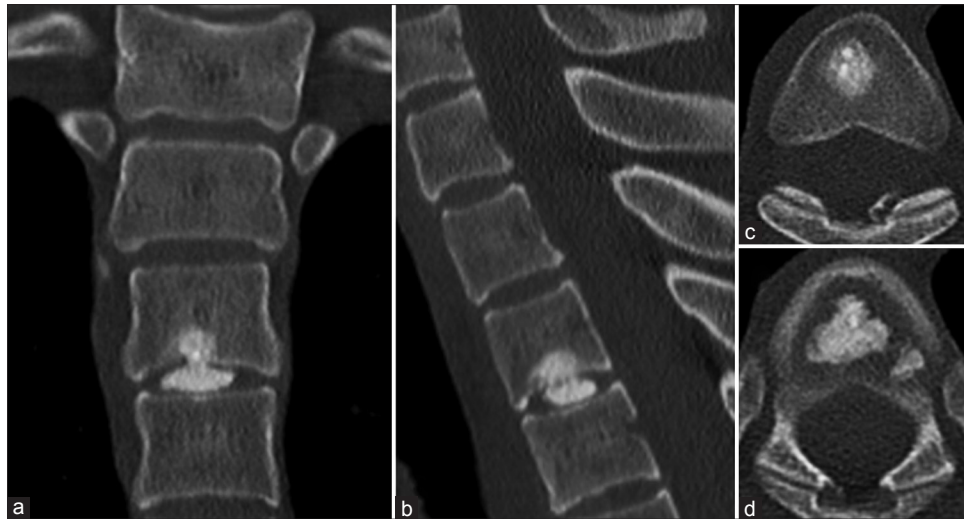
**For reprints contact:** [reprints@medknow.com](mailto:reprints@medknow.com)

computed tomography (CT) scan of the thoracic spine were performed, respectively. Plain radiography of the thoracic spine showed calcification in T3–4 intervertebral disc space [Figure 1a]. MRI of the thoracic spine demonstrated marked hypointensity on T1- and T2-weighted images without enhancement of a well-defined lesion in T3–4 intervertebral disc space, indicating calcification of nucleus pulposus, protruding into T3 vertebral body. There was diffuse hypointensity on T1-weighted image

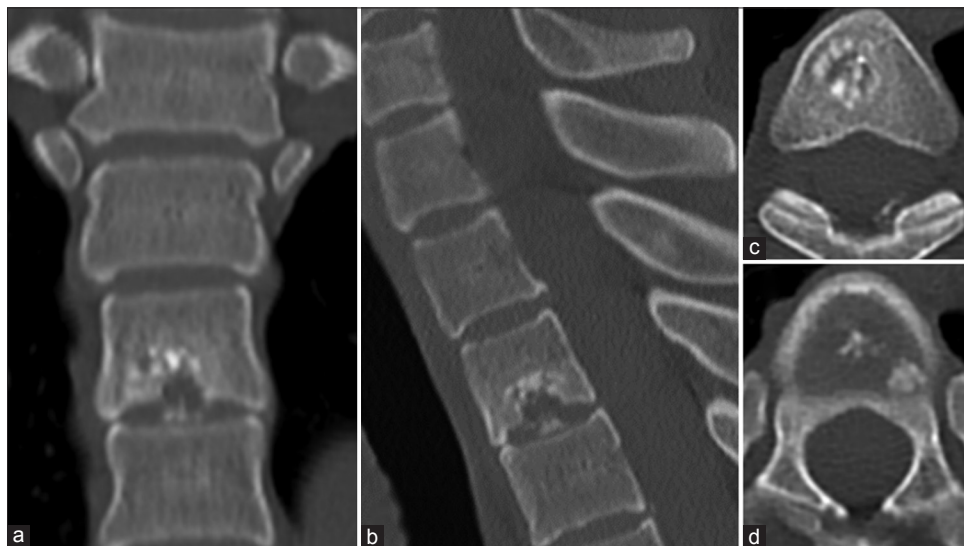
and hyperintensity on T2-weighted image of whole T3 vertebral body with vivid enhancement, representing with bone marrow edema. No abnormal paravertebral soft-tissue involvement was found [Figure 1b-f]. Subsequent CT scan of the thoracic spine also disclosed calcification of the T3–4 nucleus pulposus, migrating through the inferior endplate of T3 vertebral body [Figure 2]. Her severe pain was controlled with intravenous parecoxib sodium 40 mg twice a day for 3 days. The pain was also treated with multidrug therapy, including etoricoxib 90 mg once a day, pregabalin



**Figure 1:** Lateral view of plain radiography of the thoracic spine (a) shows calcification of the nucleus pulposus in the T3-4 intervertebral disc space (arrow). Sagittal T2-weighted image of the cervical and upper thoracic spine (b) reveals marked hypointense lesions at the T3-4 intervertebral disc and T3 inferior endplate. Coronal (c) and sagittal (d) T2-weighted image with fat suppression of the thoracic spine nicely demonstrate a well-defined hypointense lesion at the nucleus pulposus of T3-4 intervertebral disc protruding into the T3 inferior endplate, and diffuse hyperintensity of marrow edema within the T3 vertebral body, particularly around the inferior endplate. Sagittal T1-weighted image of the thoracic spine (e) also shows marked hypointensity of the T3-4 intradiscal lesion. There are intense and moderate enhancement of the T3 body on the post-contrast sagittal T1-weighted image with fat suppression (f). No enhancement of the T3-4 intradiscal lesion is noted



**Figure 2:** Reformatted coronal (a), sagittal (b), and axial at the level of T3 vertebral body (c), and T3–4 intervertebral disc (d) computed tomographic images of the upper thoracic spine demonstrate calcification of the T3–4 nucleus pulposus, migrating into adjacent T3 vertebral body through bony defect of T3 inferior endplate. Bony defect and mild sclerotic change of the affected T3 inferior endplate are noted



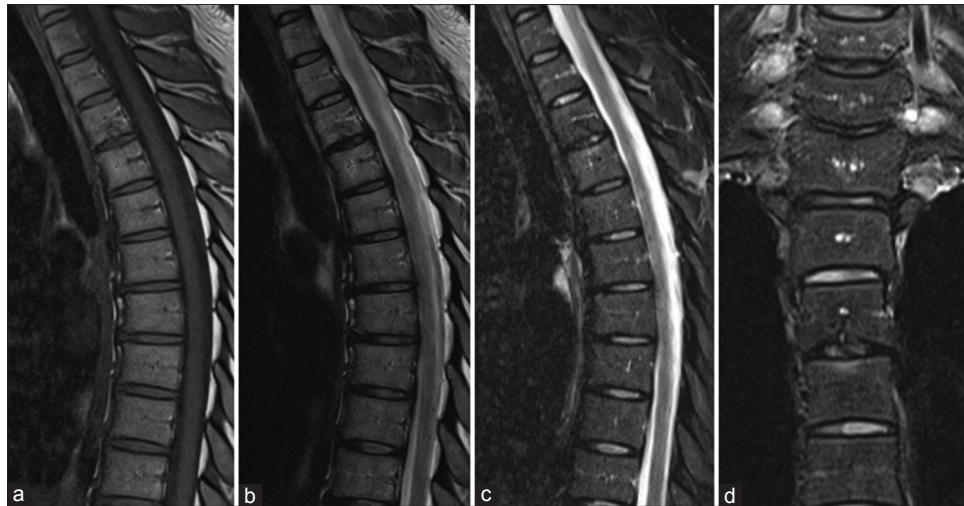**Figure 3:** Follow-up computed tomography scans of the upper thoracic spine obtained 3 months after the onset of severe pain, reformatted coronal (a), sagittal (b), and axial at the level of T3 vertebral body (c) and T3–4 intervertebral disc (d) images reveal significant resolution of intraosseous and intradiscal calcification

75 mg twice a day, and tramadol 50 mg twice a day. She was admitted for observation and discharged home 3 days later with a pain score of 4–5/10. Subsequently, pregabalin 75 mg twice a day and tramadol 50 mg every 6 h as need for pain had been maintained for controlling her residual pain. Her recovery was uneventful, and the patient remained pain free in 3 months later. Follow-up CT scan of thoracic spine, obtained 3 months after the onset of severe pain, revealed significant regression of calcification in T3 vertebral body and T3–4 intervertebral disc space [Figure 3]. One year after the onset of severe pain, follow-up MRI confirmed resolution of calcified SN and disappearance of bone marrow edema of T3 vertebral body [Figure 4]. Two years of follow-up, the patient still had no recurrent pain.

## Discussion

Logue<sup>[10]</sup> studied the plain radiography of the thoracic spine of 100 cases and reported a 4% incidence of calcification of the nucleus pulposus. Another study by Ryan *et al.*,<sup>[11]</sup> among 270 CT scans of the thoracic spine, only 4 asymptomatic patients (1.5%) were diagnosed incidental herniation of calcified nucleus pulposus. It most often affected in the lower thoracic spine and middle-aged woman. Even though large calcified herniated disc fragments produced severe spinal stenosis, few patients had no neurologic symptoms.

We reviewed the published studies of calcification of nucleus pulposus and/or calcific discitis in adults [Table 1].<sup>[1-10,12-26]</sup> The collected data in this literature review included



**Figure 4:** Follow-up magnetic resonance imaging obtained 1 year after the onset of severe pain, sagittal T1-weighted (a), T2-weighted (b), sagittal (c), and coronal (d) T2-weighted with fat suppression images confirm resolution of calcified Schmorl's node and disappearance of bone marrow edema in T3 vertebral body

demographic data (i.e., gender and age of the patient), level of involving spine, symptoms of patient, location or extension of calcified disc, probably precipitating event, the presence of bone marrow edema on MRI, the occurrence and follow-up time of spontaneous regression, treatment, and outcome of patient.

From the literature review, there were 38 cases, including our one case, with 48 levels of calcified nucleus pulposus. 25 (65.8%) females and 13 (34.2%) males with mean age 46.5, range 21–68 years, were included in this review. Thirty patients were involved in single level and eight patients were involved in multiple level. One patient was associated with thalassemia. Of 38 patients, the calcified nucleus pulposus was located at upper spine (our case) in 1 case, middle or lower thoracic spine between T6 and T12 in 32, cervical spine in 1, thoracolumbar spine in 2, and lumbar spine in 2. Most symptoms of patients were acute or nonacute pain and/or myelopathy. Two patients with calcifications were found incidentally. Symptomatic calcified discs can extrude into spinal canal in 20 cases, intervertebral foramen in 3, and intraosseous vertebral body (SN) in 11. Four calcified nucleus pulposus was located within intervertebral disc space. Extension anteriorly behind anterior longitudinal ligament with intravertebral migration was reported in one case. Eight patients had probably precipitating event before symptoms. MRI of the spine demonstrated bone marrow edema in 9 symptomatic SNs. With follow-up time ranged from 20 days to 5 years, spontaneous regression of calcified nucleus pulposus occurred in 20 cases. Open or percutaneous biopsy was performed in three cases. Eleven cases were treated with decompressive laminectomy with removal of the calcified disc. Despite initial severe symptoms, most patients had good outcomes.

The etiology of acute calcific discitis remains unknown. Acute calcific discitis or calcified nucleus pulposus in

children, unclear exact etiology but well-known clinical syndrome, is relatively rare. It typically occurred at the level of the cervical spine in the aged range between 5 and 10 years old with an apparent male predominance. Multilevel disc calcifications are frequently found up to 30%–40%. The presentation includes neck pain, torticollis, fever, and/or elevated levels of serum inflammatory markers. Remission of symptoms following rapid resolution of herniated calcified nucleus pulposus is common within a few days or weeks. The prognosis is excellent. Most pediatric patients can be treated conservatively with favorable outcome. Proved surgically, the calcified nucleus pulposus has pliability or soft toothpaste-like consistency.<sup>[2,7,16,20]</sup>

In our case, we demonstrate an adult patient with acute symptomatic calcified SN of T3–4 level associated with reactive bone marrow edema of T3 vertebral body. With conservative treatment, this calcification spontaneously regressed in 3 months. Similarly, Nogueira-Barbosa *et al.*<sup>[6]</sup> reported a 40-year-old man with symptomatic calcified SN at the level of T9–10, and demonstrated the adjacent reactive bone marrow edema in the T9 vertebral body. The pain subsided and entirely disappeared in 20 days, and spontaneous calcification resorption was confirmed by plain radiography.

Bone marrow edema of adjacent vertebral body, seen as low-signal intensity on T1-weighted images and high-signal intensity on T2-weighted images with marked enhancement after gadolinium administration may be misinterpreted as infectious, neoplastic, or other inflammatory disease, leading to unnecessary biopsy.<sup>[1]</sup> Interestingly, our literature review revealed that all patients with calcified nucleus pulposus having bone marrow edema, including our case, occurred in lesions extruded into adjacent vertebral body, i.e., SN.<sup>[1,7,15,17,24]</sup> Therefore, we agree with

**Table 1: Literature review of calcification of nucleus pulposus and/or calcific discitis in adults**

Authors	Gender/ age	Level	Symptoms	Location or extension of calcified disc	Probably precipitating event	MRI/marrow edema	Spontaneous regression/ follow-up time	Surgery	Outcome
Logue, 1952 <sup>[10]</sup>	Male/48	T9-10	Intermittent back pain/ myelopathy	Spinal canal	Heavy lifting	No/-	No	Yes	GR
	Male/44	T8-9	Myelopathy	Spinal canal	None	No/-	No	Yes	PR
	Male/38	T8-9**	Persistent back pain/ myelopathy	Spinal canal	Vigorous gardening	No/-	No	Yes	GR
		T9-10	-	-	-	-	-	-	-
	Male/52	T6-7	Progressive myelopathy	Spinal canal	None	No/-	No	Yes	PR
	Female/44	T8-9	Progressive myelopathy	Spinal canal	None	No/-	No	Yes	PR
	Male/44	T8-9**	Progressive myelopathy	Spinal canal	None	No/-	No	Yes	IR
		T9-10	-	-	-	-	-	-	-
		T10-11	-	-	-	-	-	-	-
		T11-12	-	-	-	-	-	-	-
	Male/45	T9-10	Intermittent back pain/ myelopathy	Spinal canal	None	No/-	No	Yes	GR
Williams, 1954 <sup>[12]</sup>	Female/47	T10-11	Severe pain at lower costal margin	Spinal canal	None	No/-	No/6 months	No	GR
Taylor and Little, 1964 <sup>[13]</sup>	Female/43	T7-8	-	-	-	-	-	-	-
		T8-9**	Progressive myelopathy	Spinal canal	None	No/-	No	Yes	GR
Smith, 1976 <sup>[3]</sup>	Female/56	T10-11	Acute back pain	Intravertebral migration	None	No/-	N/A	Yes***	GR
Lipson and O'Connell, 1991 <sup>[14]</sup>	Female/47	T11-12	Acute back pain	Intravertebral migration	Heavy lifting	Yes/N/A	N/A	Yes***	GR
Seymour et al., 1998 <sup>[15]</sup>	Female/47	T10-11	Acute back pain	Intravertebral migration	None	Yes/yes	Yes/N/A	No	GR
	Female/51	T10-11	Acute back pain	Intravertebral migration	None	Yes/yes	Yes/N/A	No	GR
	Female/51	T10-11	Acute back pain	Intravertebral migration	Accident	Yes/yes	Yes/N/A	No	GR
	Female/68	T11-12	Acute back pain	Intravertebral migration	None	Yes/yes	Yes/N/A	Yes***	GR
Bazzi et al., 2002 <sup>[9]</sup>	Female/32	T7-8	Acute back pain	Intravertebral disc	None	No/-	No/2 years	No	GR
	Female/59	T10-11	Acute back pain	Intravertebral disc	None	Yes/no	N/A	No	GR
Jevtić, 2004 <sup>[16]</sup>	Female/45	T11-12	Chronic back pain	Intravertebral disc	None	Yes/no	N/A	No	GR
Rodacki et al., 2005 <sup>[17]</sup>	Female/51	T8-9	-	Spinal canal	None	Yes/no	No/2 months	No	IR
		T9-10**	Persistent high back pain	Intravertebral migration	-	-	-	-	-
Piccirilli et al., 2012 <sup>[18]</sup>	Female/36	T7-8	Persistent subscapular pain	Intravertebral foramen	None	Yes/yes	Yes/4 months	No	GR
Eap et al., 2012 <sup>[19]</sup>	Male/48	T8-9**	Intercostal pain	Intravertebral foramen	None	Yes/no	Yes/11 months	No	GR
		T9-10	-	Intravertebral foramen	None	Yes/no	Yes/8 months	No	GR
		T12-L1	Incidental finding	Spinal canal	None	Yes/no	-	-	-
Nogueira-Barbosa et al., 2013 <sup>[6]</sup>	Male/40	T9-10	Acute back pain	Intravertebral migration	None	Yes/yes	Yes/1 year	No	-
Azizaddini et al., 2013 <sup>[20]</sup>	Female/22	C2-3	Acute neck pain	Intravertebral disc	None	Yes/no	Yes/20 days	No	GR
Shah et al., 2015 <sup>[7]</sup>	Female/52	T11-12	Acute back pain	Intravertebral migration	None	Yes/yes	Yes/6 months	No	GR
Nogueira-Barbosa et al., 2015 <sup>[2]</sup>	Female/48	T7-8	Back pain	Intravertebral migration	N/A	Yes/N/A	Yes/1 year	No	GR
							Yes/5 years	No	N/A

Contd...

Table 1: Contd...

Authors	Gender/ age	Level	Symptoms	Location or extension of calcified disc	Probably precipitating event	MRI/marrow edema	Spontaneous regression/ follow-up time	Surgery	Outcome
Ahmad et al., 2016 <sup>[21]</sup>	Female*/38	T6-7** T7-8**	Acute back pain Acute back pain	Spinal canal Spinal canal	None Slip and fall	Yes/no Yes/no	Yes/2 years No/2 months	No No	GR N/A
Xu et al., 2016 <sup>[4]</sup>	Female/31	T6-7 T8-9	- -	- -	- -	- -	- -	- -	- -
	Female/55	T9-10** T8-9	Acute back pain/myelopathy Progressive back pain/ myelopathy	Spinal canal Spinal canal	None Walking up	Yes/no Yes/no	Yes/6 months Yes/6 months	No No	GR GR
Yue et al., 2016 <sup>[22]</sup>	Male/57	T11-12	Acute paraplegia	Spinal canal	None	Yes/no	No	Yes	GR
	Male/53	T10-11	Acute paraplegia	Spinal canal	None	Yes/no	No	Yes	GR
Sari et al., 2016 <sup>[5]</sup>	Female/38	T7-8**	Subscapular and lower chest wall pain	Intervertebral foramen	None	Yes/no	Yes/5 months	No	GR
	Male/63	T8-9 L1-2	- Incidental finding	- Intervertebral disc	- -	- Yes/no	No No	No No	- -
Umit et al., 2017 <sup>[23]</sup>	Male/63	L1-2	Acute low back pain/ unilateral sciatica	Anterior migration/ intravertebral migration	Picking up a child	Yes/yes	Yes/6 months	No	N/A
Sadek et al., 2017 <sup>[24]</sup>	Female/65	L4-5							
Hu et al., 2017 <sup>[8]</sup>	Male/52	T12-L1	Pain, rapidly progressive myelopathy	Spinal canal	Leaning over	Yes/no	No	Yes	IR
Harshavardhana et al., 2017 <sup>[25]</sup>	Male/46	T7-8	Axial back and radicular pain	Spinal canal	None	Yes/no	Yes/4½ months	No	GR
Oligane et al., 2018 <sup>[26]</sup>	Female/40	T10-11	Abdominal and pelvis pain	Spinal canal	None	Yes/no	Yes/8 months	No	GR
Present study, 2019	Female/28	T3-4	Acute upper back pain	Intravertebral migration	None	Yes/yes	Yes/3 months	No	GR

\* Associated with thalassaemia; \*\* Symptomatic disc; \*\*\* Open or percutaneous biopsy. C – Cervical; T – Thoracic; L – Lumbar; GR – Good recovery; IR – Incomplete recovery; PR – Poor result; N/A – Data not available; MRI – Magnetic resonance imaging

previously studies that the diffuse bone marrow edema of vertebral body caused by intraosseous fracture from the calcified SN following by the healing process that inflammation and edema decreased progressively.<sup>[1,7]</sup> The recognition of a defect or disruption of the endplate defect on plain radiography or CT scan is the key for the correct diagnosis.<sup>[1,3,7,15,17]</sup> In addition, the lack of paravertebral soft-tissue swelling and the sparing of the disc are also imperative finding for the diagnosis. The sclerotic changes of the adjacent endplates result from an osteoblastic reaction in marrow.<sup>[7]</sup> Radionuclide bone scanning frequently demonstrates focal increased uptake of radionuclide in the affected vertebral body due to osteoblastic activity.<sup>[1,6,7,14,15]</sup>

Lipson and O'Connell<sup>[14]</sup> reported a 47-year-old woman with acute back following heavy lifting. Three months after acute initial symptoms, plain radiography, CT scan, and incomplete study of MRI of the thoracic demonstrated calcification of the nucleus pulposus at the level of T11–12, ill-defined sclerotic response surrounding a round lytic lesion in the body of T11, and low-signal intensity on T1-weighted images in the lower left half of the T11 vertebral body. In addition, a radionuclide bone scan also revealed a focal area of increased activity involving the T11 body. Open biopsy of the T11 vertebral body was performed, and pathological examination with polarized light showed morphologically typical of calcium hydroxyapatite. Previously mentioned, this patient should be diagnosed as symptomatic SN. They postulated that the crystals are actively resorbed by the inflammatory cells and stimulate osteoclast activity, producing the large lytic defect on CT scan. Atypical findings of images, sclerotic changes surrounding a lytic lesion, may represent spontaneous regression of herniated calcific fragment corresponding to CT scan obtained 3 months after acute pain in our case.

Previously studies demonstrated symptomatic calcified herniated disc following preexisting nucleus calcification. Smith<sup>[3]</sup> reported a middle-age woman with acute symptomatic calcified SN following 10 years previously identification of the calcification of the nucleus pulposus at the lower thoracic spine. Ahmad *et al.*<sup>[21]</sup> also reported a new herniation of the previously identified nonherniated calcified disc at the level of T7–8 after a slip and fall, while the previously seen a large calcified herniation at the level of T6–7 spontaneously regressed in 2 years. Compare to subsidence of cervical autologous cage in a biomechanical cadaveric study, Sadek *et al.*<sup>[24]</sup> proposed that intravertebral migration may result from repeated axial cyclical loading on an affected calcification of the nucleus pulposus, leading to weakness of the endplate.

Spontaneous resorption of the herniated disc may relate with neovascularization. In addition, inflammatory cytokines, angiogenesis inducing factor, and matrix-degrading enzymes play a crucial role during this process.<sup>[27]</sup> Piccirilli *et al.*<sup>[18]</sup> reported a young female with spontaneous

regression of a thoracic calcified disc herniation that the MRI showed an enhancement of its noncalcified cranial part mimicking a calcified meningioma, representing recruited local blood vessels. A prolapsed calcified intervertebral disc can be completely resorbed when there is the local vascular response or restored blood flow accessing to the lesion.<sup>[3,28]</sup> The origin of small blood vessels seen in the extruded disc is unclear. It may result from newly formed blood vessels following disc extrusion or preexisting blood vessels extruded with intervertebral disc tissue.<sup>[29]</sup> On the other hand, some studies found that symptomatic calcified herniated disc totally regressed, while asymptomatic calcified disc or intradiscal calcification was not absorbed and still remained in place.<sup>[4,5,19]</sup>

Since 1964, with X-ray diffraction and electron microscope, Taylor and Little<sup>[13]</sup> demonstrated hydroxyapatite crystal deposits from surgical tissue of calcified nucleus pulposus having a soft consistency. Due to the soft consistency of the calcified disc material, even complete posterior extrusion of a calcified disc with severe spinal cord compression, some patients with calcific discitis can manifest with asymptomatic, chronic symptoms, or gradually progressive myelopathy.<sup>[11,26]</sup> Xu *et al.*<sup>[4]</sup> reported successful conservative treatment in two adult patients, even with the presence of early myelopathy from giant calcified discs. Complete spontaneous resorption of giant herniated discs occurred within 6 months after the initial presentation. Another study by Harshavardhana *et al.*<sup>[25]</sup> demonstrated spontaneous regression of a large symptomatic calcified extruded thoracic disc over 2½ months. Recently, Oligane *et al.*<sup>[26]</sup> also disclosed spontaneous regression of a large calcified thoracic disc extrusion with spinal cord edema and signal changes on MRI in 8 months. In opposition, giant calcified degenerative discs have hard consistency and produce myelopathy, mostly treated with surgery. Calcification process or deposition of thoracic discs may originate from posterior longitudinal ligament, extending into disc space and spinal canal.<sup>[30]</sup>

However, there was few cases of calcific discitis underwent emergency surgery. Yue *et al.*<sup>[22]</sup> reported acute paraplegia from severe lower thoracic spinal cord compression caused by herniated calcification of the nucleus pulposus treated by discectomy and spinal fusion in two adult patients. They found that the calcified portion of the disc was like a semisolid toothpaste and easily removed in both cases. Hu *et al.*<sup>[8]</sup> also reported an adult patient with acute calcific discitis, extending into spinal canal, producing severe pain, and rapidly progressive myelopathy. Emergency decompressive laminectomy and calcified disc removal were performed, but this patient had incomplete recovery.

Similarly, acute calcific tendinitis in the rotator cuff tendon of the shoulder, calcium hydroxyapatite crystal deposition disease, spontaneously reabsorbed in the majority of cases and can be treated first with conservative management. The

average age of manifestation was between 30 and 50 years, and woman commonly affected than man. MRI of the shoulder also revealed edema around calcium deposits in the resorptive phase. In acutely painful patients, the calcium deposits tend to have semiliquid toothpaste-like consistency.<sup>[31,32]</sup>

## Conclusion

Acute calcific discitis in an adult is extremely rare. Similar to pediatric calcific discitis, spontaneous regression of the calcified herniated nucleus pulposus in adult can occur in the majority of cases. In cases of symptomatic SN with adjacent marrow edema, the defect or disruption of the endplate is the key for correct diagnosis, leading to avoid the unnecessary invasive procedure. Conservative treatment is the first line of the management, resulting in favorable outcome.

## Consent

The patient has given consent to be enrolled and has her data published.

## Declaration of patient consent

The authors certify that they have obtained all appropriate patient consent forms. In the form, the patient has given her consent for her images and other clinical information to be reported in the journal. The patient understands that name and initials will not be published, and due efforts will be made to conceal identity, but anonymity cannot be guaranteed.

## Financial support and sponsorship

Nil.

## Conflicts of interest

There are no conflicts of interest.

## References

- Grivé E, Rovira A, Capellades J, Rivas A, Pedraza S. Radiologic findings in two cases of acute Schmorl's nodes. *AJNR Am J Neuroradiol* 1999;20:1717-21.
- Nogueira-Barbosa MH, Crema MD, da Silva Herrero CF, Pasqualini W, Defino HL. The several faces of Schmorl's node: Pictorial essay. *Coluna/Columna* 2015;14:320-3.
- Smith DM. Acute back pain associated with a calcified Schmorl's node: A case report. *Clin Orthop Relat Res* 1976;117:193-6.
- Xu N, Wei F, Liu X, Jiang L, Liu Z. Calcific discitis with giant thoracic disc herniations in adults. *Eur Spine J* 2016;25 Suppl 1:204-8.
- Sari H, Misirlioglu TO, Palamar D. Regression of a symptomatic thoracic disc herniation with a calcified intervertebral disc component. *Acta Orthop Traumatol Turc* 2016;50:698-701.
- Nogueira-Barbosa MH, da Silva Herrero CF, Pasqualini W, Defino HL. Calcific discitis in an adult patient with intravertebral migration and spontaneous remission. *Skeletal Radiol* 2013;42:1161-4.
- Shah A, Botchu R, Grainger MF, Davies AM, James SL. Acute symptomatic calcific discitis in adults: A case report and review of literature. *Skeletal Radiol* 2015;44:1819-24.
- Hu SB, Niu LS, Zheng WB, Sun T, Sun MY. Paralysis resulting from calcific discitis with acute herniation. *Chin Med J (Engl)* 2017;130:2643-4.
- Bazzi J, Dimar JR, Glassman SD. Acute calcific discitis in adults. *Am J Orthop (Belle Mead NJ)* 2002;31:141-5.
- Logue V. Thoracic intervertebral disc prolapse with spinal cord compression. *J Neurol Neurosurg Psychiatry* 1952;15:227-41.
- Ryan RW, Lally JF, Kozic Z. Asymptomatic calcified herniated thoracic disks: CT recognition. *AJNR Am J Neuroradiol* 1988;9:363-6.
- Williams R. Complete protrusion of a calcified nucleus pulposus in the thoracic spine; report of a case. *J Bone Joint Surg Br* 1954;36-B:597-600.
- Taylor TK, Little K. Prolapsed calcified thoracic intervertebral disc. *J Pathol Bacteriol* 1964;88:153-7.
- Lipson SJ, O'Connell JX. Case records of the Massachusetts general hospital weekly clinicopathological exercises case 37-1991: A 47-year-old woman with back pain and a lesion in a vertebral body. *N Engl J Med* 1991;325:794-9.
- Seymour R, Williams LA, Rees JI, Lyons K, Lloyd DC. Magnetic resonance imaging of acute intraosseous disc herniation. *Clin Radiol* 1998;53:363-8.
- Jevtić V. A calcified cervical intervertebral disc in a child and a thoracic disc calcification in an adult with posterior herniation-radiographic, computed tomography and magnetic resonance imaging findings. *Radiol Oncol* 2004;38:339-47.
- Rodacki MA, Castro CE, Castro DS. Diffuse vertebral body edema due to calcified intraspongious disk herniation. *Neuroradiology* 2005;47:316-21.
- Piccirilli M, Lapadula G, Caporlingua F, Martini S, Santoro A. Spontaneous regression of a thoracic calcified disc herniation in a young female: A case report and literature review. *Clin Neurol Neurosurg* 2012;114:779-81.
- Eap C, Bennis S, Blauwblomme T, Compaore P, Chamsedine A, Mireau E, et al. Spontaneous resorption of thoracic calcified disc herniation: Report of two cases and review of the literature. *Neurochirurgie* 2012;58:353-7.
- Azizaddini S, Arefanian S, Redjal N, Walcott BP, Mollahoseini R. Adult acute calcific discitis confined to the nucleus pulposus in the cervical spine: Case report. *J Neurosurg Spine* 2013;19:170-3.
- Ahmad FU, Schallert E, Bregy A, Post JD, Vanni S. Disappearing large calcified thoracic disc herniation in a patient with thalassaemia. *BMJ Case Rep* 2016;2016. pii: bcr2015213166.
- Yue B, Chen B, Zou YW, Xi YM, Ren XF, Xiang HF, et al. Thoracic intervertebral disc calcification and herniation in adults: A report of two cases. *Eur Spine J* 2016;25 Suppl 1:118-23.
- Umit E, Fatih Y, Hasan CU. Lumbar intervertebral disc calcification: A case report. *Nov Approaches Drug Des Dev* 2017;1:1-3.
- Sadek AR, Dare C, McGillion S, Nader-Sepahi A, Skiadas V. Lumbar intravertebral disc herniation secondary to idiopathic calcific discitis. *Br J Neurosurg* 2017;31:1-5.
- Harshavardhana NS, Panvica TP, Pinto MR. Spontaneous regression of a large symptomatic calcified central thoracic disc herniation: A case report with a review of the literature. *J Head Neck Spine Surg* 2017;1:1-4.
- Oligane H, Rongo J, Agarwal V, Branstetter BF 4<sup>th</sup>. Spontaneous regression of a large calcified thoracic disk extrusion. *Skeletal Radiol* 2018;47:1177-82.
- Kato T, Haro H, Komori H, Shinomiya K. Sequential dynamics



- of inflammatory cytokine, angiogenesis inducing factor and matrix degrading enzymes during spontaneous resorption of the herniated disc. *J Orthop Res* 2004;22:895-900.
28. Peck FC Jr. A calcified thoracic intervertebral disk with herniation and spinal cord compression in a child; case report. *J Neurosurg* 1957;14:105-9.
  29. Yasuma T, Arai K, Yamauchi Y. The histology of lumbar intervertebral disc herniation. The significance of small blood vessels in the extruded tissue. *Spine (Phila Pa 1976)* 1993;18:1761-5.
  30. Al-Mahfoudh R, Mitchell PS, Wilby M, Crooks D, Barrett C, Pillay R, *et al.* Management of giant calcified thoracic disks and description of the trench vertebrectomy technique. *Global Spine J* 2016;6:584-91.
  31. Merolla G, Singh S, Paladini P, Porcellini G. Calcific tendinitis of the rotator cuff: State of the art in diagnosis and treatment. *J Orthop Traumatol* 2016;17:7-14.
  32. Wainner RS, Hasz M. Management of acute calcific tendinitis of the shoulder. *J Orthop Sports Phys Ther* 1998;27:231-7.