

Dural Ectasia and Cauda Equina Syndrome: A Rare Complication of Long-standing Fusion

Abstract

The clinicoradiological combination of cauda equina syndrome (CES) and dural ectasia is rare and has been described in a few of patients with ankylosing spondylitis (AS). Simultaneous occurrence of these entities in the absence of AS and in patients with long-standing spinal fusion is extremely rare. We present a case of dural ectasia and CES occurring as a long-term complication of instrumented spinal fusion and discuss the pathogenesis, imaging findings, and management options of this elusive disease process.

Keywords: *Cauda equina syndrome, dural ectasia, magnetic resonance imaging, spinal fusion*

Introduction

Dural ectasia is a rare complication of long standing spinal fusion. While majority of the patients with dural ectasia are asymptomatic, a few may present with cauda equina syndrome complex. In the following vignette, we describe one such patient who developed insidious and progressive lower extremity weakness and bowel bladder incontinence secondary to dural ectasia associated with lumbar instrumented fusion.

Case Report

A 62-year-old man presented to our hospital with left lower extremity weakness, worsening progressively over 6 months, and recent onset of bowel and bladder incontinence. Clinical examination revealed flaccid paralysis of the left lower extremity with absent reflexes and loss of touch, proprioception, pinprick, and vibration. The rectal tone was decreased. An electromyography revealed muscle denervation in the left lower extremity suggesting polyradiculopathy. His medical history was significant for gunshot wound to the back for which he underwent several back surgeries over a protracted duration of 20 years between 1986 and 2006. No history of connective tissue disorder or ankylosing spondylitis (AS) was obtained.

Cauda equina syndrome (CES) was suspected, and a magnetic resonance

imaging (MRI) of the lumbar spine was ordered for further evaluation of the spinal canal and the cauda equina roots. Multilevel thoracolumbar spinal fusion and laminectomy were noted on MRI with no spinal stenosis at any level. The thecal sac was patulous and multiple dural sacculations were seen at L4 and L5 levels with scalloping of the posterior vertebral elements [arrows in Figure 1a-c] and peripheral displacement of the nerve roots [arrowhead in Figure 1a]. Sacroiliac joints were unremarkable [arrowheads in Figure 1c]. Based on the clinical and imaging findings, a diagnosis of CES and dural ectasia in the setting of long-standing spinal fusion was rendered.

Lumboperitoneal shunting was offered, but the patient denied. He continues to be on physical therapy with little to no improvement.

Discussion

Dural ectasia is typically seen in patients with AS^[1] and connective tissue disorders such as Marfan's syndrome,^[2] Ehlers–Danlos syndrome,^[3] and neurofibromatosis.^[4] The exact etiology of dural ectasia remains unknown; however, it is believed that chronic peridural inflammation in conditions such as AS leads to weakening of the dura and secondary dural sacculations. Peridural fibrosis from inflammation also reduces the pliability of the dura with increased transmission

Vrushali D. Bachhav,
Sumeet G. Dua,
Miral D. Jhaveri

*Department of Radiology,
Rush University Medical Center,
Section of Neuroradiology,
Chicago, IL, USA*

Address for correspondence:

*Dr. Sumeet G. Dua,
Department of Radiology, Rush
University Medical Center,
Section of Neuroradiology,
1653 W Congress Pkwy,
Chicago, IL 60612, USA.
E-mail: duasum@gmail.com*

Access this article online

Website: www.asianjns.org

DOI: 10.4103/ajns.AJNS_113_16

Quick Response Code:



How to cite this article: Bachhav VD, Dua SG, Jhaveri MD. Dural ectasia and cauda equina syndrome: A rare complication of long-standing fusion. *Asian J Neurosurg* 2018;13:465-7.

This is an open access journal, and articles are distributed under the terms of the Creative Commons Attribution-NonCommercial-ShareAlike 4.0 License, which allows others to remix, tweak, and build upon the work non-commercially, as long as appropriate credit is given and the new creations are licensed under the identical terms.

For reprints contact: reprints@medknow.com

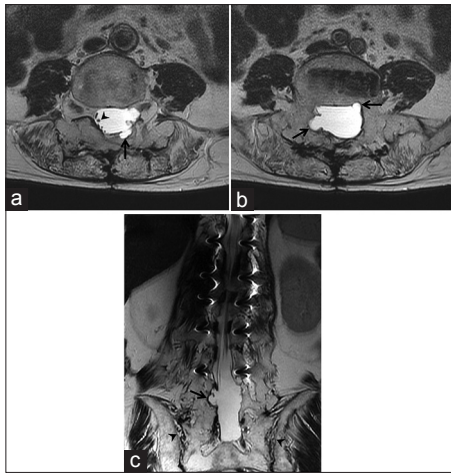


Figure 1: (a and b) Axial T2-weighted images through the lumbar spine at L4 and L5 levels reveal dural sacculations and scalloping of the posterior elements (arrows) representing dural ectasia. Note the peripheral displacement of the cauda equina nerve roots and empty thecal sac appearance due to arachnoiditis. (c) Coronal T2-weighted images reveal dural ectasia with vertebral scalloping (arrows) with unremarkable appearing sacroiliac joints (arrowheads). Note the susceptibility artifacts arising from thoracolumbar pedicle screws

of cerebrospinal fluid (CSF) pulsations through the dural sacculations and consequent scalloping of the vertebrae. This theory is also supported by preferential localization of dural ectasia to the lumbosacral region where CSF pressure is high.^[5,6]

Patients with dural ectasia are usually asymptomatic although constipation, urinary incontinence, back and leg pain have been variously reported.^[7,8] CES in the setting of dural ectasia is rare and has been described in patients with AS. Proposed mechanisms for damage to the nerve roots include small vessel angiitis involving the vasa nervorum, nerve root damage due to increased CSF pressure and decreased the elasticity of the dural sac, and chronic inflammatory process.^[9-11] The peridural inflammatory process is also believed to spread to the perineural soft tissues along the cauda equina nerve roots initiating arachnoiditis and resulting in gradual CES due to nerve damage.^[10]

Above theories have been proposed to explain dural ectasia and CES in patients with AS. Our patient is unique because the findings were seen in the absence of underlying AS or a connective tissue disorder. A comprehensive search of literature revealed only three similar cases and all of these patients, including ours, underwent multiple spinal surgeries over a protracted course of time. We believe that the findings in our case can be explained by prolonged and repetitive peridural inflammation secondary multiple spinal surgeries; similar to the pathogenesis in AS.

MRI findings of dural ectasia are characteristic. Dural sacculations are typically seen with scalloping of the posterior elements.^[12,13] The thecal sac is empty, and the cauda equina roots are adherent to the periphery consistent

with arachnoiditis. Occasional protrusion of the dura into the foramina can give rise to lateral pseudomeningocele and arachnoid cyst. These imaging features are pathognomonic and objective diagnostic criteria although proposed are not essential to make the diagnosis.^[13]

Nonsteroidal anti-inflammatory drugs reportedly decrease back pain. There is no effective treatment for the neurologic deficit although lumboperitoneal shunting has shown some benefit in anecdotes.^[14,15]

Conclusion

We present an extremely unusual case of CES and dural ectasia occurring as a complication of long-standing spinal fusion. Familiarity with this disease process in the atypical setting, such as ours, is invaluable in making the diagnosis and in the management of these patients.

Financial support and sponsorship

Nil.

Conflicts of interest

There are no conflicts of interest.

References

- Kotil K, Yavasca P. Lumbar radiculopathy in ankylosing spondylitis with Dural ectasia. *J Clin Neurosci* 2007;14:981-3.
- Pyeritz RE, Fishman EK, Bernhardt BA, Siegelman SS. Dural ectasia is a common feature of the Marfan syndrome. *Am J Hum Genet* 1988;43:726-32.
- Pepin MG, Superti-Furga A, Byers PH. Natural history of Ehlers-danlos syndrome type IV: Review of 137 cases. *Am J Hum Genet* 1992;5:A44.
- de Kleuver M, van Jonbergen JP, Langeloo DD. Asymptomatic massive Dural ectasia associated with neurofibromatosis type 1 threatening spinal column support: Treatment by anterior vascularized fibula graft. *J Spinal Disord Tech* 2004;17:539-42.
- Bilgen IG, Yuntun N, Ustun EE, Oksel F, Gumusdis G. Adhesive arachnoiditis causing cauda equina syndrome in ankylosing spondylitis: CT and MRI demonstration of Dural calcification and a dorsal Dural diverticulum. *Neuroradiology* 1999;41:508-11.
- Ahn NU, Sponseller PD, Ahn UM, Nallamshetty L, Rose PS, Buchowski JM, *et al.* Dural ectasia in the Marfan syndrome: MR and CT findings and criteria. *Genet Med* 2000;2:173-9.
- Fattori R, Nienaber CA, Descovich B, Ambrosetto P, Reggiani LB, Pepe G, *et al.* Importance of Dural ectasia in phenotypic assessment of Marfan's syndrome. *Lancet* 1999;354:910-3.
- Nallamshetty L, Ahn NU, Ahn UM, Nallamshetty HS, Rose PS, Buchowski JM, *et al.* Dural ectasia and back pain: Review of the literature and case report. *J Spinal Disord Tech* 2002;15:326-9.
- Confavreux C, Larbre JP, Lejeune E, Sindou M, Aimard G. Cerebrospinal fluid dynamics in the tardive cauda equina syndrome of ankylosing spondylitis. *Ann Neurol* 1991;29:221-3.
- Matthews WB. The neurological complications of ankylosing spondylitis. *J Neurol Sci* 1968;6:561-73.
- Soeur M, Monseu G, Baleriaux-Waha D, Duchateau M, Williame E, Pasteels JL. Cauda equina syndrome in

- ankylosing spondylitis. Anatomical, diagnostic, and therapeutic considerations. *Acta Neurochir (Wien)* 1981;55:303-15.
12. Hong TA, Koenigsberg RA, Brown F, Dastur CK, Kanoff R. Lumbar Dural ectasia secondary to spinal fusion: A report of two cases. *J Neuroimaging* 2006;16:357-60.
 13. Bartleson JD, Miller GM, Lanzino G. Cauda equina syndrome associated with longstanding instrumented spinal fusion. *World Neurosurg* 2013;79:594.e5-8.
 14. Ahn NU, Ahn UM, Nallamshetty L, Springer BD, Buchowski JM, Funches L, *et al.* Cauda equina syndrome in ankylosing spondylitis (the CES-AS syndrome): Meta-analysis of outcomes after medical and surgical treatments. *J Spinal Disord* 2001;14:427-33.
 15. Lan HH, Chen DY, Chen CC, Lan JL, Hsieh CW. Combination of transverse myelitis and arachnoiditis in cauda equina syndrome of long-standing ankylosing spondylitis: MRI features and its role in clinical management. *Clin Rheumatol* 2007;26:1963-7.