

## Endoscopic Excision of Intraventricular Neurocysticercosis Cyst with an Angiocatheter: A Retrospective Analysis

### Abstract

**Introduction:** An intraventricular cysticercus cyst is observed in 7%–30% patients of neurocysticercosis (NCC). Apart from causing arachnoiditis, intraventricular NCC (IVNCC) can cause sudden death due to acute episodes of hydrocephalus. Various treatment modalities available are external cerebrospinal fluid (CSF) diversion, microsurgical removal, and endoscopic management. There is no consensus regarding the optimal surgical treatment strategy. We are presenting our experience by doing a retrospective analysis of 26 patients having endoscopic removal of IVNCC with a rigid endoscope and angiocatheter. **Aim:** The aim of this study is to evaluate the results of neuroendoscopy in restoring the CSF pathway and removal of the cyst in patients of IVNCC. **Materials and Methods:** Retrospective analysis of clinical record and follow-up of 26 patients of IVNCC who were treated endoscopically between 2010 and 2018 was done. The diagnosis of IVNCC was made based on contrast enhanced magnetic resonance imaging of the brain. Transcranial endoscopy with 0° endoscope was performed through the frontal burr hole. Third ventriculostomy and removal of the cysticercus cyst with angiocatheter were the procedures done. **Results:** The success rate of intraventricular cyst excision, whether complete or partial, was 100% (14/14) in the third ventricular cyst, 62.5% (5/8) in the fourth ventricular cyst and 100% (4/4) in the lateral ventricular cyst. The overall success rate of cyst excision by endoscopy was 88.46%. The overall successful CSF flow pathway was established in 88.46% cases. The mean duration of follow-up was 44 months, and all the patients were found symptom free in the follow-up period. **Conclusion:** Neuroendoscopy, being a single burr hole technique successfully providing internal CSF diversion and cyst removal, is the treatment modality of choice for IVNCC.

**Keywords:** Hydrocephalus, neurocysticercosis, neuroendoscopy, ventriculostomy

### Introduction

Neurocysticercosis (NCC) is the most common parasitic infestation of the central nervous system worldwide. The oncosphere reaches the ventricular system, subarachnoid spaces, and basal cisterns via the choroid plexus through hematogeneous route.<sup>[1-4]</sup> An intraventricular cysticercus cyst is observed in 7%–30% patients of NCC.<sup>[5,6]</sup> The fourth ventricle is the most common site (53%) followed by the third ventricle (27%), lateral ventricle (11%), and the aqueduct (9%). The fourth ventricle is the most common site of intraventricular NCC (IVNCC) because of gravitational migration and cerebrospinal fluid (CSF) flow pattern. Isolated cystic lesions can migrate through the ventricular system, occluding vital communication corridors and can cause sudden death due to

acute episodes of hydrocephalus. Apart from causing obstructive hydrocephalus, IVNCC causes basal arachnoiditis and ependymitis. Hence, these patients require prompt diagnosis and treatment as they can develop brain herniation anytime. Available treatment modalities are medication, external CSF diversion, microsurgical removal, and endoscopic management. Shunt carries the risk of blockage, infection, and cyst migration.<sup>[7]</sup> Microsurgical approaches are technically challenging and are associated with huge surgical morbidity.<sup>[8]</sup> Endoscopic management of IVNCC has shown encouraging results; however, the literature regarding the use of this modality in the treatment of IVNCC is scarce.<sup>[9-13]</sup> A major advantage of endoscopy is the removal of the cyst and CSF diversion in the same sitting, with a single burr-hole

**Varun Kumar Aggarwal, Gopal Krishna, Ishwar Singh**

Department of Neurosurgery,  
PGIMS, Rohtak, Haryana, India

### Address for correspondence:

Dr. Ishwar Singh,  
22/8FM, Medical Campus,  
PGIMS, Rohtak - 124 001,  
Haryana, India.  
E-mail: drishwarsingh@yahoo.  
co.in

Video available on:  
[www.asianjns.org](http://www.asianjns.org)

Access this article online

Website: [www.asianjns.org](http://www.asianjns.org)

DOI: 10.4103/ajns.AJNS\_112\_20

Quick Response Code:



This is an open access journal, and articles are distributed under the terms of the Creative Commons Attribution-NonCommercial-ShareAlike 4.0 License, which allows others to remix, tweak, and build upon the work non-commercially, as long as appropriate credit is given and the new creations are licensed under the identical terms.

For reprints contact: WKHLRPMedknow\_reprints@wolterskluwer.com

**How to cite this article:** Aggarwal VK, Krishna G, Singh I. Endoscopic excision of intraventricular neurocysticercosis cyst with an angiocatheter: A retrospective analysis. *Asian J Neurosurg* 2020;15:527-31.

Submitted: 25-Mar-2020

Revised: 24-Apr-2020

Accepted: 03-Jun-2020

Published: 28-Aug-2020

technique ensuring the preservation of normal anatomical architecture. However, still, there is no consensus regarding optimal surgical treatment strategy in patients with IVNCC with hydrocephalus. We are presenting our experience by doing a retrospective analysis of 26 patients having endoscopic removal of IVNCC with rigid neuro endoscope and angiocatheter.

## Material and Methods

### Patient characteristics

Retrospective analysis of clinical record and follow-up of 26 patients of IVNCC who were treated endoscopically between 2010 and 2018 was done. The diagnosis of IVNCC was made based on contrast-enhanced magnetic resonance imaging (MRI) of the brain with constructive interference steady state (CISS) MR sequence. Of 26 patients, 14 patients had third ventricular NCC, 8 had fourth ventricular NCC, and 4 had lateral ventricle NCC. All the information regarding demographic variables, clinical presentation, neurological signs, radiological findings, and endoscopic findings was collected and analyzed.

### Endoscopic technique

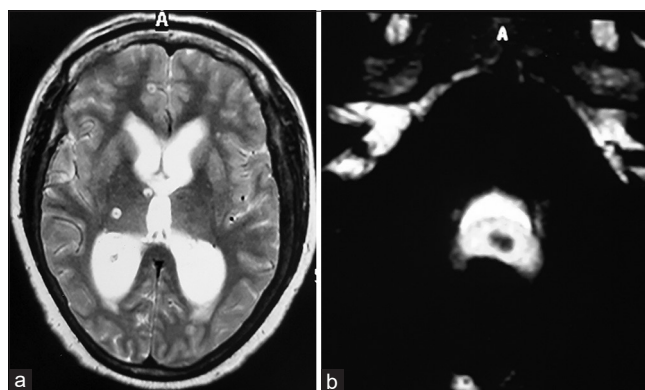
The Gaab endoscope system (Karl Storz GmbH, Tuttlingen, Germany) was used in all cases. After induction of general anaesthesia patients were kept supine with head in the neutral position and fixed by adhesive tape on the table. A precoronal burr hole was made for lateral ventricle and anterior third ventricle cyst, and burr hole 1 cm anterior to coronal suture was made for posterior third ventricular and fourth ventricle cyst. The duramater was coagulated and incised in a cruciate manner. Pia mater was coagulated, and endoscopic trocar with cannula was inserted into the right frontal horn. A 0° rigid neuroendoscope was introduced into the lateral ventricle, and cystic lesion was identified in the case of lateral ventricle and anterior third ventricle NCC. Then a 5-French cerebral angiography catheter, cut at 30–35 cm from the standard syringe-nozzle hub end, was introduced into the ventricle through the working channel. The cyst wall was held at the tip of the catheter by maintaining negative pressure using 5 ml disposable syringe, and the steering movement of the catheter helped in detaching the cyst from the ependyma without any bleeding or damage. Sometimes, the densely adherent cyst was opened up and was removed in piecemeal manner without any complication. Most of the cysts were withdrawn by removing the angiocatheter with the whole of endoscope assembly. Continuous irrigation with warm Ringer's solution was used during the whole procedure. For the posterior third ventricular cyst and fourth ventricular cyst, first endoscopic third ventriculostomy (ETV) was performed using a 5-F Fogarty balloon catheter, and then cyst is retrieved. For removal of the fourth ventricular cyst first opening of the dilated aqueduct was identified, then cyst was identified through the dilated aqueduct, and then

angiocatheter was negotiated into the dilated aqueduct and cyst was removed similarly. However, if the aqueduct was not found dilated, then only ETV was done in such cases. All patients were given steroid and antiepileptic coverage in the perioperative and postoperative period.

## Results

Patient characteristics, location of the cyst, procedure performed, complications, and follow-up are summarized in Table 1. There were 17 female patients and 9 male patients with overall age ranging from 11 years to 60 years (mean age 42.2 years). Clinical symptoms were headache in 18 patients, altered sensorium in 8, seizure in 6, diplopia in 6, ataxia in 4, and diminution of vision in 4 patients. Out of 26 patients, 14 patients had third ventricular NCC, 8 had fourth ventricular NCC, and 4 had lateral ventricle NCC. All the patients had hydrocephalus preoperatively. Twenty-four patients (92.3%) had noncommunicating hydrocephalus and two patients (7.7%) of lateral ventricle NCC were having communicating hydrocephalus. There was an associated parenchymal cyst in 14 patients. Of 26 patients, 13 patients had complete excision of cyst, 7 had ETV with complete excision of cyst, 3 had ETV alone, and 3 had partial excision of cyst with ventriculoperitoneal (VP) shunt.

In 14 patients having third ventricular cyst complete excision done in 11 patients, complete excision with ETV done in 2 patients, and in one patient having densely adhered cyst in posterior third ventricle partial excision was done. In 8 patients having fourth ventricular cyst [Figure 1] complete excision with ETV done in 5 patients as shown in the video 1 and in 3 patients cyst could not be retrieved from the aqueduct, so ETV was done. In 4 patients having lateral ventricle cyst complete excision done in 2 patients [Figure 2] and in two patients having densely adhered cyst partial excision was done [Figure 3]. Two patients developed intraventricular bleed during surgery, so the external ventricular drain put, and as the CSF became clear drain was removed after 48 h. However after

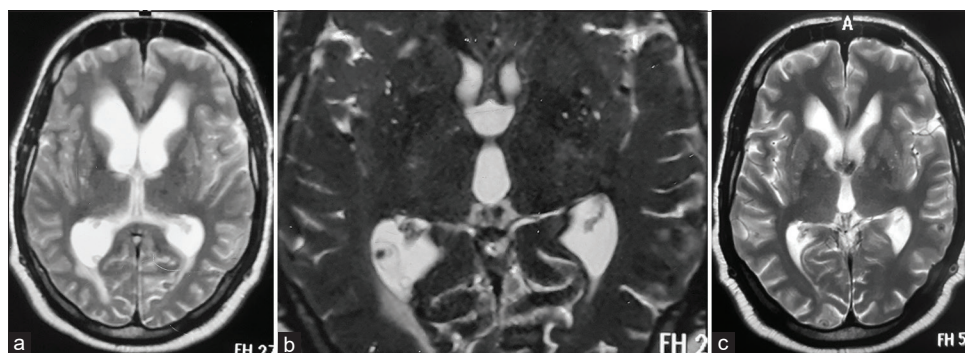


**Figure 1:** (a) T2-weighted image showing hydrocephalus with multiple parenchymal cysticercal cyst. (b) Magnetic resonance constructive interference steady state sequence showing fourth ventricular cysticercal cyst in the same patient

**Table 1: Summary of the patients with intraventricular neurocysticercosis who underwent endoscopic excision of cyst**

Case number	Age (years)/sex	Lesion site	Surgery	Perioperative and postoperative complication	Followup (months)
1	50/female	TV	PE+Shunt	Intraventricular bleed	132
2	42/male	TV	CE	None	108
3	45/female	FV	ETV	None	96
4	45/female	LV	CE	None	90
5	30/male	TV	CE+ETV	None	72
6	36/male	TV+P	CE	Seizure	70
7	52/male	LV+P	CE	None	60
8	55/female	FV+P	CE+ETV	None	48
9	60/female	LV	PE+Shunt	Intraventricular bleed	46
10	40/female	TV+P	CE+ETV	None	38
11	42/female	FV	CE+ETV	None	36
12	45/male	FV+P	CE+ETV	None	35
13	35/female	TV+P	CE	None	32
14	56/male	FV	CE+ETV	None	30
15	52/female	FV	ETV	None	27
16	41/female	TV	CE	None	26
17	25/male	TV+P	CE	Seizure	26
18	30/female	FV+P	ETV	None	25
19	40/female	TV+P	CE	None	24
20	11/female	LV+P	PE+Shunt	Hydrocephalus	24
21	60/male	TV	CE	None	23
22	57/female	TV+P	CE	None	21
23	55/female	TV	CE	None	20
24	14/male	FV	CE+ETV	None	14
25	35/female	TV	CE	None	12
26	45/female	TV+P	CE	None	8

LV – Lateral ventricle; TV – Third ventricle; FV – Fourth ventricle; P – Parenchymal cyst; CE – Complete excision of cyst; PE – Partial excision; ETV – Endoscopic third ventriculostomy; Shunt – Ventriculoperitoneal shunt



**Figure 2: (a) Preoperative magnetic resonance T2-weighted image showing hydrocephalus with cysticercal cyst in right occipital horn. (b) Magnetic resonance T2 constructive interference steady state sequence showing cysticercal cyst in right occipital horn. (c) Postoperative T2-weighted image showing resolution of hydrocephalus with no residual cyst in right occipital horn**

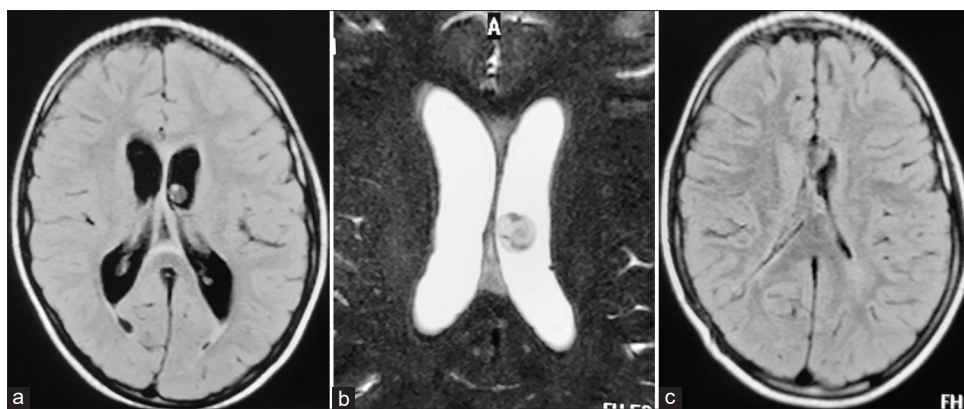
1 week of surgery, both patients developed communicating hydrocephalus and VP shunt was put. One patient having partially excised densely adherent cyst had persistent hydrocephalus, so VP shunt was put. Single episode of generalized tonic-clonic seizure occurred in two patients in the postoperative period, which was managed by the escalation of antiepileptic coverage. So the success rate of intraventricular cyst excision, whether complete or partial, was 100% in the third ventricular cyst, 62.5% in the fourth ventricular cyst and 100% in lateral ventricular

cyst [Table 2]. The overall success rate of cyst excision by endoscopy was 88.46%. The overall successful CSF flow pathway was established in 88.46% cases, as summarized in Table 3. The mean duration of follow-up was 44 months and all the patients were found symptom free in the follow-up period.

**Discussion**

IVNCC has a more aggressive behavior than their parenchymal counterpart. Parenchymal cysts cause





**Figure 3:** (a) Preoperative magnetic resonance flair image showing cysticercal cyst in left lateral ventricle. (b) Magnetic resonance constructive interference steady state sequence showing cysticercal cyst in left lateral ventricle. (c) Postoperative flair image showing resolution of hydrocephalus with residual cyst with ventricular catheter-*in situ* after partial excision of cyst

**Table 2: Overall successful ventricular cyst excision rate by endoscopy**

Location (n)	Excision cases (n')	Success rate (%)
Third ventricular cyst (14)	14	100
Fourth ventricular cyst (8)	5	62.5
Lateral ventricular cyst (4)	4	100
Total (26)	23	88.46

n – Total number of cases; n' – Number of cases having complete or partial excision

**Table 3: Overall successful cerebrospinal fluid pathway restoration by endoscopy**

Location (n)	Restoration cases (n')	Success rate
Third ventricular cyst (14)	13	92.86
Fourth ventricular cyst (8)	8	100.00
Lateral ventricular cyst (4)	2	50.00
Total (26)	23	88.46

n – Total number of cases; n' – Number of cases having successful CSF pathway restoration; CSF – Cerebrospinal fluid

symptoms due to host inflammatory response and brain edema. However, intraventricular cysts can cause obstructive hydrocephalus due to obstruction of the CSF pathway and arachnoiditis due to the host's inflammatory response.

Intraventricular cysts may cause either a gradual or an abrupt obstruction of CSF flow. Sites of obstruction include foramen of Monro, posterior third ventricle, the aqueduct of Sylvius, and fourth ventricle.<sup>[14]</sup> Abrupt obstruction leads to signs and symptoms of acute hydrocephalus such as headache, vomiting, seizures, lateral rectus palsy, somnolence, bradycardia, respiratory irregularity, and hypertension. Cases of sudden death have also been reported by abrupt intermittent hydrocephalus due to ball valve movement of third ventricular and fourth ventricular cysts.<sup>[15,16]</sup> Chronic obstructive symptoms such as headache, nausea, memory changes, visual blurring, and gait disturbance may be present for several months

before diagnosis and are more common in enlarging fourth ventricular cysts. Apart from causing obstructive hydrocephalus, IVNCC may cause communicating hydrocephalus due to ependymitis and basal arachnoiditis secondary to the inflammatory response to the dying larva. A large cyst in the fourth ventricle may produce symptoms of the brainstem and cerebellar compression and aqueduct of Sylvius syndrome. Hence, the patients of IVNCC require prompt diagnosis and management before they deteriorate. These are diagnosed mainly based on MRI brain with CISS imaging, immunoassay techniques, and in fewer cases by evidence of subretinal parasite. A viable intraventricular cyst appears as a spherical lesion of 10–20 mm in diameter with scolex appearing as hyperintense dot within the cyst.

Various treatment options for IVNCC are medical therapy with the antihelminthic drug, external CSF diversion with or without medical therapy, microsurgical excision and endoscopic removal. All the treatment modalities are in practice according to the patient's preference, surgeon's expertise, and experience. The endoscopic approach in the hands of expert neuroendoscopist not only allows internal CSF diversion but also gives maximum chances of cyst removal. It is a minimally invasive technique with less operating time, less blood loss, and short hospital stay. Rigid neuroendoscopy is the main modality being used by most of the neurosurgeons for removal of lateral ventricle, third ventricle, and fourth ventricle cyst.<sup>[11,16]</sup> But in cases of fourth ventricular neurocysticercosis (FVNCC) where aqueduct is not dilated or cyst is lying very low flexible endoscopy has been found a useful technique for removal of the cyst.<sup>[9,13]</sup> Even in cases of densely adherent cyst where only partial removal is accomplished, remaining debris in the CSF rarely causes ventriculitis.<sup>[12]</sup> Forniceal contusion, intraoperative bleed, and aqueductal contusions are the common complications that have rarely been found to cause any long term sequelae.

Husain *et al.* analyzed the record of 30 patients of IVNCC who were treated endoscopically, from 1996 to 2014.<sup>[11]</sup>

The mean age was 28.63 years (age range 6–85 years) with male-female ratio of 1.35:1. In our series, the mean age was 42.2 years (age range 11–60 years) with male-female ratio 2:1. The most common presentation in both the studies was a headache with papilledema and ataxia as the most common neurological signs. In Husain *et al.* series 16 patients were having third ventricular NCC, 12 had FVNCC, one temporal horn NCC and one cavum septum NCC.<sup>[11]</sup> In our series, 14 patients had third ventricular cyst, 8 had fourth ventricular cyst, and 4 had lateral ventricular cyst.

Although complete cyst excision does restore the CSF circulation pathway in cases of IVNCC but ETV along with complete excision of cyst in cases of posterior third ventricular NCC and fourth ventricle NCC has many advantages. First, it decreases the chances of hydrocephalus due to delayed stenosis of the aqueduct or fourth ventricle outlet caused by postinflammatory scarring.<sup>[11]</sup> Second, ETV provides prophylactic CSF diversion to bypass the CSF pathway blockage caused by any residual cyst. Third ETV gives the technical advantage of lowering CSF pressure in the third ventricle, which pushes the fourth ventricle cyst towards the aqueduct.<sup>[11]</sup> There are also many studies reporting minimal requirement of shunt placement in cases of the third ventricle and fourth ventricle NCC who underwent ETV with complete excision of cyst.<sup>[9,11,13]</sup> In our study also none of the patients of complete excision with ETV had hydrocephalus in the follow-up period.

The reported rate of endoscopic cyst excision ranges from 90% to 100%. Husain *et al.* and Suri *et al.* had cyst excision in 96.15% and 100%, respectively.<sup>[11,13]</sup> In our series, cyst excision was achieved in 88.46% because in 3 cases of FVNCC aqueduct was not dilated, and cyst could not be visualized. CSF diversion using endoscopic means has a success rate from 40% to 100%. We were able to successfully restore the CSF pathway by endoscopy in 88.46% cases. The success rate of ETV was 100% as none of the patients of ETV had symptoms of hydrocephalus in follow-up period, nor it was found in follow-up MRI.

## Conclusion

IVNCC requires prompt diagnosis and management to reduce the incidence of sudden death due to acute hydrocephalus. Contrast-enhanced MRI brain with CISS sequence is the imaging modality of choice for early diagnosis. Neuroendoscopy, being a single burr hole technique successfully providing internal CSF diversion and cyst removal, is the treatment modality of choice for IVNCC.

## Financial support and sponsorship

Nil.

## Conflicts of interest

There are no conflicts of interest.

## References

1. Apuzzo ML, Dobkin WR, Zee CS, Chan JC, Giannotta SL, Weiss MH. Surgical considerations in treatment of intraventricular cysticercosis. An analysis of 45 cases. *J Neurosurg* 1984;60:400-7.
2. Brown WJ, Voge M. Cysticercosis. A modern day plague. *Pediatr Clin North Am* 1985;32:953-69.
3. Flisser A. Taeniasis and cysticercosis due to *Taenia solium*. *Prog Clin Parasitol* 1994;4:77-116.
4. Salazar A, Sotelo J, Martinez H, Escobedo F. Differential diagnosis between ventriculitis and fourth ventricular cyst in neurocysticercosis. *J Neurosurg* 1983;59:660-3.
5. Cuetter AC, Andrews RJ. Intraventricular neurocysticercosis: 18 consecutive patients and review of the literature. *Neurosurg Focus* 2002;12:e5.
6. Cuetter AC, Garcia-Bobadilla J, Guerra LG, Martinez FM, Kaim B. Neurocysticercosis: Focus on intraventricular disease. *Clin Infect Dis* 1997;24:157-64.
7. Colli BO, Martelli N, Assirati JA Jr, Machado HR, de Vergueiro Forjaz S. Results of surgical treatment of neurocysticercosis in 69 cases. *J Neurosurg* 1986;65:309-15.
8. McCormick GF. Cysticercosis—review of 230 patients. *Bull Clin Neurosci* 1985;50:76-101.
9. Anandh B, Mohanty A, Sampath S, Praharaj SS, Kolluri S. Endoscopic approach to intraventricular cysticercal lesions. *Minim Invasive Neurosurg* 2001;44:194-6.
10. Cudlip SA, Wilkins PR, Marsh HT. Endoscopic removal of a third ventricular cysticercal cyst. *Br J Neurosurg* 1998;12:452-4.
11. Husain M, Rastogi M, Jha DK, Husain N, Gupta RK. Endoscopic transaqueductal removal of fourth ventricular neurocysticercosis with an angiocatheter. *Neurosurgery* 2007;60:249-54.
12. Psarros TG, Krumerman J, Coimbra C. Endoscopic management of supratentorial ventricular neurocysticercosis: Case series and review of the literature. *Minim Invasive Neurosurg* 2003;46:331-4.
13. Suri A, Goel RK, Ahmad FU, Vellimana AK, Sharma BS, Mahapatra AK. Transventricular, transaqueductal scope-in-scope endoscopic excision of fourth ventricular neurocysticercosis: A series of 13 cases and a review. *J Neurosurg Pediatr* 2008;1:35-9.
14. Citow JS, Johnson JP, McBride DQ, Ammirati M. Imaging features and surgery-related outcomes in intraventricular neurocysticercosis. *Neurosurg Focus* 2002;12:e6.
15. Estanol B, Kleriga E, Loyo M, Mateos H, Lombardo L, Gordon F, *et al.* Mechanism of hydrocephalus in cerebral cysticercosis: Implications for therapy. *Neurosurgery* 1983;13:119-23.
16. Zymberg ST, PalvaNeto MA, Gorguilo AA, Cavalheiro S. Endoscopic approach to fourth ventricular cysticercosis. *Arq Neuropsiquiatr* 2003;61:204-7.