Article published online: 2021-03-23

Case Report

Multiple, Bilateral Renal Oncocytomas: An Uncommon Condition Managed with Percutaneous Cryoablation

Abstract

Multiple, bilateral renal oncocytomas are uncommon, and the management of this condition is poorly described. Here, we report a case of multiple, bilateral, biopsy-proven renal oncocytomas that were successfully managed using percutaneous cryoablation. This procedure may serve as a less invasive treatment for patients with multiple, bilateral renal oncocytomas when compared to radical or partial nephrectomy.

Keywords: *Ablation, cryoablation, oncocytoma, renal mass*

Robert A. Esposito, Jennifer Gordetsky[1], Soroush Rais-Bahrami[2], Andrew J. Gunn

Departments of Radiology, [1]Pathology and [2]Urology, University of Alabama at Birmingham, Birmingham, AL, USA

Introduction

Benign oncocytomas comprise 3%–7% of renal tumors.[1] Of this, 4%–6% are multifocal and bilateral.[1] Oncocytomas are difficult to distinguish from other renal masses, such as renal cell carcinoma (RCC), without pathologic confirmation.[2] Historically, oncocytomas were managed conservatively until symptomatic, prompting radical or partial nephrectomy.[1] However, percutaneous ablation is a safe, minimally invasive, and effective therapy for small renal masses, including RCC and oncocytomas.[3,4] Yet, the role of ablation in managing patients with multiple, bilateral oncocytomas is not well described.[5] Here, we present a case of multiple, bilateral renal oncocytomas successfully managed with percutaneous cryoablation.

Case Report

A male patient with a history of coronary artery disease, atrial fibrillation, and prostatectomy presented with vague complaints of nausea and intermittent abdominal pain. A contrast-enhanced computed tomography (CT) revealed multiple, bilateral renal masses [Figure 1]. The differential diagnosis included RCC and oncocytoma. At presentation, the patient denied any dysuria, hematuria, and unintentional weight loss. Due to his significant cardiovascular history, he was referred to interventional radiology for percutaneous cryoablation with concurrent biopsy.

Procedure 1

The largest lesion (an enhancing, 2.5 cm mass in the left kidney) was targeted at the first visit. CT – fluoroscopy was used to guide the ablation. Moderate conscious sedation was administered and 2% lidocaine was used for local anesthesia. 18G core biopsies were obtained from the mass before ablation. After the biopsy, two cryoablation probes (IceRod™ 1.5 and IceSphere™ 1.5; Galil Medical, Arden Hills, MN, USA) were advanced into the mass. Cryoablation was performed with a 10-min freeze cycle, followed by an 8-min passive thaw, a second 10-min freeze cycle, and then active thawing. Intermittent CT was performed to evaluate coverage of the lesion by the ice ball [Figure 2]. A final CT ensured an adequate ablation without immediate complication. The patient was discharged home the same day. The biopsy results confirmed that this mass was an oncocytoma. Typically, we obtain follow-up imaging 3 months after a renal ablation. However, given that this patient had other renal masses, there was continued concern that one of the masses could be RCC. Thus, follow-up imaging was obtained 1 month after the first ablation.

Procedure 2

On the first follow-up, there were two new enhancing masses in the left kidney,

This is an open access journal, and articles are distributed under the terms of the Creative Commons Attribution-NonCommercial-ShareAlike 4.0 License, which allows others to remix, tweak, and build upon the work non-commercially, as long as appropriate credit is given and the new creations are licensed under the identical terms.

For reprints contact: reprints@medknow.com

How to cite this article: Esposito RA, Gordetsky J, Rais-Bahrami S, Gunn AJ. Multiple, bilateral renal oncocytomas: An uncommon condition managed with percutaneous cryoablation. Arab J Intervent Radiol 2019;3:23-5.

Address for correspondence:
Dr. Andrew J. Gunn, 619 19th St South, NHB 623, Birmingham, AL 35249, USA. E-mail: agunn@uabmc.edu

Access this article online

Website: www.arabjir.com

DOI: 10.4103/AJIR.AJIR_31_18

Quick Response Code:

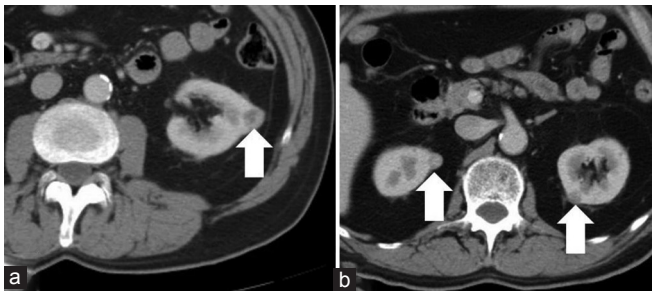

Figure 1: (a) Axial slice from a contrast-enhanced computed tomography demonstrates an exophytic, solid renal mass in the left kidney (white arrow). (b) Axial slice from the same contrast-enhanced computed tomography at a higher level shows similar but smaller solid masses in both kidneys (white arrows)

measuring 2.2 cm and 1 cm. Due to concern for RCC, a second cryoablation procedure was scheduled. Again, CT – fluoroscopy was used to guide the ablation. Moderate conscious sedation was administered and 2% lidocaine was used for local anesthesia. 18G core biopsies were obtained from the largest mass before ablation. After the biopsy, two cryoablation probes (both IceRod™ 1.5) were advanced into the largest mass. A single cryoablation probe (IceRod™ 1.5) was inserted into the smaller lesion. Cryoablation was performed in a similar fashion as the first procedure. Intermittent CT was used to evaluate coverage of the lesion by the ice ball. A final CT demonstrated an adequate ablation without immediate complication. The patient was discharged home the same day. The biopsy results confirmed that the largest mass was an oncocytoma. Once again, due to the concern for RCC, imaging was obtained approximately 6 weeks after the second ablation.

Procedure 3

Follow-up imaging did not show any new or growing lesions but continued concern for concomitant RCC on the right prompted a third cryoablation procedure. At this third procedure, the largest masses on the right were targeted. Both of these masses were enhancing and measured 1.7 cm and 1.3 cm. As before, CT – fluoroscopy was used to guide the ablation and moderate conscious sedation was administered. 2% lidocaine was used for local anesthesia. 18G core biopsies were obtained from the largest mass before ablation. After the biopsy, two cryoablation probes (both IceRod™ 1.5) were advanced into the largest mass. A single cryoablation probe (IceRod™ 1.5) was inserted into the smaller lesion. Cryoablation was performed in a similar fashion as the previous procedures. Intermittent CT was used to evaluate coverage of the lesion by the ice ball. A final CT demonstrated good coverage of the masses without immediate complication. The patient was discharged home the same day. The biopsy results confirmed that the largest mass was an oncocytoma. The patient underwent follow-up imaging at 1 month, which showed no new or enlarging masses. The patient then

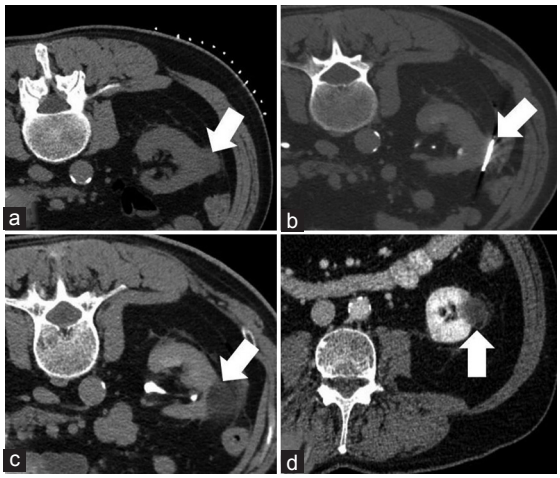

Figure 2: (a) Axial slice from an unenhanced computed tomography performed before ablation with the patient in prone position demonstrates the exophytic mass in the left kidney (white arrow). A localizing grid is seen overlying the patient. (b) Computed tomography image obtained during the procedure shows the tip of the ablation probe within the mass (white arrow). (c) computed tomography image obtained during the procedure shows the ice ball from cryoablation which has good coverage of the mass (white arrow). (d) Axial slice from a contrast-enhanced computed tomography scan approximately 3 years after cryoablation of the left renal mass shows no enhancement or growth (white arrow). This is compatible with excellent response to treatment

underwent surveillance imaging at approximately 6-month intervals.

Procedure 4

Approximately 2 years after the third ablation, the patient was noted to have an enlarging, enhancing 2 cm mass in the left kidney; therefore, a fourth ablation procedure was scheduled. CT – fluoroscopy was used to guide the ablation, moderate conscious sedation was administered, and 2% lidocaine was used for local anesthesia. 18G core biopsies were obtained from the mass before ablation. After the biopsy, two cryoablation probes (both IcePearl™ 2.1) were advanced into the mass. Cryoablation was performed in the same manner as the prior procedures. Intermittent CT was used to evaluate coverage of the lesion by the ice ball. A final CT demonstrated an appropriate ablation without immediate complication. The patient was discharged home the same day. The biopsy results confirmed that the largest mass was an oncocytoma. The patient underwent a follow-up scan approximately 3 months after this procedure that showed no evidence of new or enlarging masses. The patient has undergone surveillance imaging approximately every 12 months. It has now been approximately 4 years since the patient's initial presentation, and the patient is doing well without complication or deterioration of renal function. There have been no new or enlarging lesions. Biopsies from all the procedures have consistently demonstrated oncocytomas, suggesting the diagnosis of multiple, bilateral oncocytomas [Figure 3].

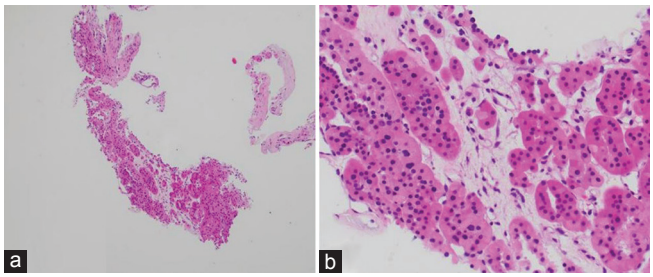

Figure 3: Hematoxylin and eosin stains from core biopsy samples obtained during the first ablation procedure. (a) At low magnification, an oncocytic renal neoplasm with nested growth in a fibromyxoid background. (b) At high magnification, the slide shows abundant eosinophilic cytoplasm and round nuclei without significant cytologic atypia, mitoses, or necrosis. Similar findings were seen from core biopsies obtained at each ablation procedure

Discussion

Prior reports of multiple, bilateral renal oncocytomas have been managed with either surveillance or surgery, including partial or radical nephrectomy.[1] Some reports of percutaneous cryoablation as a treatment for oncocytomas exist[4] although most describe the treatment of a single lesion. The rarity of this condition and lack of long-term outcomes has made it difficult to draw any substantive conclusions on management. Percutaneous ablation is a well-established, minimally invasive treatment for small RCCs with similar oncologic outcomes to partial nephrectomy for T1a disease.[6] Further, ablation is associated with less complications and quicker recovery times, making it an attractive alternative for patients who cannot undergo or do not desire traditional surgery.[6] Here, we used cryoablation for the treatment of multiple, bilateral oncocytomas. In the setting of multiple renal oncocytomas, image-guided ablation appears to have several potential advantages. First, as in this case, it allows for the simultaneous biopsy and treatment of the solid renal mass. Pathologic confirmation of either RCC or oncocytoma is essential in determining further management and/or surveillance. Second, percutaneous ablation is a more nephron-sparing approach than radical nephrectomy. Overall morbidity and mortality may improve if patients can avoid the initiation of dialysis. Third, percutaneous ablation can be performed as an outpatient procedure with comparatively short recovery times. Undoubtedly, percutaneous ablation carries a certain risk of complications even though they are relatively uncommon. For instance, postprocedural pain (7.2%),[7] bleeding (1%–15%),[8] hematuria (1%),[8] and damage to adjacent structures (i.e., ureter and bowel)[9] can occur. Complication rates are known to increase with increasing number of ablation probes, prolonged procedure time, and masses that are endophytic and located in the anterior kidney.[10] Nevertheless, percutaneous ablation of multiple, bilateral renal oncocytomas may be considered for the management of this uncommon pathology.

Acknowledgments

The authors would like to acknowledge the advice of Edgar S. Underwood, MD, on the preparation of this manuscript.

Financial support and sponsorship

Nil.

Conflicts of interest

Dr. Gunn receives speaking and consulting fees from BTG.

References

1. Dechet CB, Bostwick DG, Blute ML, Bryant SC, Zincke H. Renal oncocytoma: Multifocality, bilateralism, metachronous tumor development and coexistent renal cell carcinoma. J Urol 1999;162:40-2.
2. Kay FU, Pedrosa I. Imaging of solid renal masses. Urol Clin North Am 2018;45:311-30.
3. Gunn AJ, Gervais DA. Percutaneous ablation of the small renal mass-techniques and outcomes. Semin Intervent Radiol 2014;31:33-41.
4. Aoun HD, Littrup PJ, Jaber M, Memon F, Adam B, Krycia M, *et al.* Percutaneous cryoablation of renal tumors: Is it time for a new paradigm shift? J Vasc Interv Radiol 2017;28:1363-70.
5. Krokidis M, Sabharwal T, Adam A. Radiofrequency ablation of multifocal bilateral renal oncocytomas. Interv Med Appl Sci 2011;3:74-6.
6. Talenfeld AD, Gennarelli RL, Elkin EB, Atoria CL, Durack JC, Huang WC, *et al.* Percutaneous ablation versus partial and radical nephrectomy for T1a renal cancer: A population-based analysis. Ann Intern Med 2018;169:69-77.
7. Johnson DB, Solomon SB, Su LM, Matsumoto ED, Kavoussi LR, Nakada SY, *et al.* Defining the complications of cryoablation and radio frequency ablation of small renal tumors: A multi-institutional review. J Urol 2004;172:874-7.
8. Atwell TD, Callstrom MR, Farrell MA, Schmit GD, Woodrum DA, Leibovich BC, *et al.* Percutaneous renal cryoablation: Local control at mean 26 months of followup. J Urol 2010;184:1291-5.
9. Zhou W, Arellano RS. Thermal ablation of T1c renal cell carcinoma: A comparative assessment of technical performance, procedural outcome, and safety of microwave ablation, radiofrequency ablation, and cryoablation. J Vasc Interv Radiol 2018;29:943-51.
10. Azevedo AA, Rahal A Jr., Falsarella PM, Lemos GC, Claros OR, Carneiro A, *et al.* Image-guided percutaneous renal cryoablation: Five years experience, results and follow-up. Eur J Radiol 2018;100:14-22.