

# How to Deal with Infringuinal Arterial Calcifications: Atherectomy and Lithoplasty Devices

## Abstract

This overview article should describe current technical problems of severe infringuinal calcifications, outline solutions for challenging and complex lesions and give an overview over currently available debulking devices which are meant to deal with calcified lesions. As a relatively new device, arterial lithoplasty is discussed.

**Keywords:** *infringuinal calcifications, atherectomy, lithoplasty*

## Dierk Vorwerk

*Department of Radiology,  
Klinikum Ingolstadt, Ingolstadt,  
Germany*

## Introduction

Arterial calcifications are challenging. If massive both locally or generalized they may complicate or deteriorate technical and clinical outcomes of percutaneous interventions during each phase of an intervention during follow-up and at each vascular level.

Huge effort has been put in to improve the situation and an armamentarium of devices, tricks, ideas and advices has been utilized in getting along with arterial calcifications.

This overview article is meant to give some advice about the problems calcifications create and how to deal with them in every phase of an intervention.

## Problems

### Common femoral artery

In the common femoral arteries, huge eccentric calcifications are frequently located at the backside of the artery. In that case, access to the groin should be performed by a flat needle angulation to allow the safe introduction of a wire into the arterial lumen. In the case of tight, circumferential plaques, the puncture is often contraindicated, and a cross-over approach might be feasible. Furthermore, calcified groin arteries may be a good reason to plan an intervention as a hybrid or semi hybrid approach with an open

femoral endarterectomy (TEA) combined with balloon angioplasty (PTA) or else of further downward territories; alternatively, a precedent PTA of the distal segments may be performed followed by subsequent acute surgical TEA in the theatre while leaving the sheath in place over the waiting period.

### Superficial femoral and popliteal arteries

Calcified plaques occur very frequently in the superficial femoral and in the popliteal artery. Some are explicitly eccentric protruding into the lumen; others are circumferential and block the arterial lumen from all sides.

### Primary passage

Calcified lesions may be difficult to pass, especially in case a very irregular lumen remains. This is even more difficult if an occlusion is present as there is no potential pathway left that could be used as a guiding route through the stenosed segment. Even coated guidewires may fail to pass these irregularly formed tortuous and filiform lumina and may easily cause dissection ending in the subintimal route. In our experience, it is recommendable to overcome such difficult passages by the use of thin but stable 0.014-inch wires eventually combined by support catheters. In isolated short calcifications that do not allow any passage, we found it helpful in selected cases to perforate the calcified segment by the use of a 5F TIPS needle catheter.

**Received:** 15-04-2020  
**Revised:** 18-04-2020  
**Online Published:** 07-07-2020

### Address for correspondence:

*Prof. Dierk Vorwerk,  
Department of Radiology,  
Klinikum Ingolstadt, Ingolstadt,  
Germany.  
E-mail: dierk.vorwerk@  
klinikum-ingolstadt.de*

### Access this article online

**Website:** [www.arabjir.com](http://www.arabjir.com)

**DOI:** 10.4103/AJIR.AJIR\_12\_20

### Quick Response Code:



**How to cite this article:** Vorwerk D. How to deal with infringuinal arterial calcifications: atherectomy and lithoplasty devices. Arab J Interven Radiol 2020;4:60-6.

This is an open access journal, and articles are distributed under the terms of the Creative Commons Attribution-NonCommercial-ShareAlike 4.0 License, which allows others to remix, tweak, and build upon the work non-commercially, as long as appropriate credit is given and the new creations are licensed under the identical terms.

**For reprints contact:** WKHLRPMedknow\_reprints@wolterskluwer.com

Once the wire dislodges into a subintimal space, a spontaneous reentry into the true lumen is unlikely in the presence of heavy calcifications. Under those circumstances, it is recommended to switch to the use of a reentry device early before the dissecting channel creates extended damage to the distal arteries. We prefer the outback catheter (Cordis Inc., Miami, FL, USA) for this purpose as the relatively stiff needle can penetrate even calcified arterial walls, although frequently, it needs an extra push to perforate the wall back into the true lumen. However, once a reentry has been successfully established, calcified arteries add some other problems before an intervention can be safely terminated. First, it might be difficult to cross the entry point by larger catheters. This can be solved either by coaxially combining support and a diagnostic catheter or by ballooning the reentry point by small 0.014-inch balloon catheters (3–4 mm diameter).

#### *Infrapopliteal arteries*

In lower limb arteries, calcified vessels open a variety of technical difficulties during the primary passage. They may prevent safe passage even of very small guidewires, or they allow passage of a 0.014 in guidewire only but prevent the coaxial passage of any other instrument.

The first step would be to enforce the pushing force for all instruments. This could be done by antegrade access, use of support catheters, and use of a long sheath or guiding catheter with its tip placed close to the trifurcation.

If this is not enough to overcome the lesion, then debulking instruments can be utilized, such as the phoenix rotational atherectomy catheter (Philips Inc.) or the Crosser high-frequency CTO device (Bard Peripheral vascular, Inc, Tempe, Arizona, USA); the latter comes in an-over-the-wire and a no-wire version. Both systems are expensive and depending on each particular national reimbursement system they might be used only in selected cases.

#### *Luminal regain*

The next step is also frequently unpredictable in the presence of severe calcifications. Although it is true that frequently despite the presence of eccentric plaques a surprisingly wide lumen may be achieved by simple PTA only, it is not well tested how long this success will last as the plaques tend to relapse. Furthermore, in many cases, luminal gain remains moderate or disappointing. It is important to notice that this is still within the technical phase, and incomplete luminal regain may have an inverse relation to long-term patency and clinical success. However, long-term patency depends on many additional factors, such as remodeling and intimal growth. Calcified arterial segments are known to be no good target for additional treatment, such as drug-eluting balloons (DCB).

The decision whether to accept an incomplete regain as a final result depends on the location of a lesion, the clinical stage of the disease and the degree of residual stenosis. In lesions located at the popliteal artery at the Pop 2 level, less can be more if a stent can be avoided in this location, while in the superficial femoral artery far away from joint regions, a more aggressive approach might be feasible. In stage III or IV (Fontaine), even incomplete opening of an artery >50% might be enough to improve the clinical situation, while in claudicants, this would be not sufficient for relief. Nevertheless, in claudicants with Pop 2 popliteal lesions, stenting should be only considered as a very last option, and other techniques should be used before. Hence, the decision-making depends on the individual situation and should be tailored to the requirements in each patient, taking into account the location of the lesion, technical outcome, situation of inflow and outflow vessels, and clinical stage. In the eyes of the author, there are two no-go areas for stents: The common femoral artery as there are good surgical options available and the pop 2 segments where stents should be avoided under all circumstances if possible-if appearing unavoidable interdisciplinary agreement with vascular surgery should be obtained.

#### **Alternatives to PTA**

There are a number of debulking devices having been described over the past two decades. This includes laser atherectomy, directional, orbital, rotational atherectomy, and others. Quite recently, shock-wave lithoplasty was introduced into clinical usage. Unfortunately, for most of these techniques, only limited numbers of trials exist, mostly nonrandomized case series on low-scale numbers.

#### **Debulking techniques**

##### *Laser atherectomy*

Although being in clinical use for more than two decades, laser atherectomy has been tested by very few randomized trials and usually was not successful to show a major technical and clinical benefit. There is one randomized trial<sup>[1]</sup> showing a significant benefit over balloon angioplasty in treating in-stent stenosis in femoral arteries. This difference was mainly due to a higher technical success rate but not an evident advantage concerning long-term patency. Laser atherectomy can penetrate calcified plaques and may be used for plaque reduction by eccentric positioning of the laser fibers to gain a larger diameter.

##### **Directional atherectomy**

Simpson atherectomy catheters (Guidant, Brussels, Belgium) were the first atherectomy devices available in the Nineties with an eccentric balloon and a lateral window with a rotational cutter that allowed to shave plaque material from the wall collecting the debris within the collecting chamber. This device has been modified over the decades giving up the eccentric balloon, which allowed to

miniaturize the device diameter. The current design (Hawk One, Medtronic, Zurich, Switzerland) is a 7 F catheter with an eccentric cutter and differently long nose cones that allow the collection of debris. Especially in calcified plaques, it is highly recommended to use an additional protection device distally to the lesion to prevent distal embolization of debris. The device is very suitable to treat focal eccentric lesions to debulk and eventually followed by balloon angioplasty. It is cumbersome to be used in long segment lesions and has some limitations in the distal popliteal artery as the nose cone should always be above the protection device, and this is not possible in every case. We prefer the device in eccentric popliteal stenoses and popliteal dissections [Figure 1].

Zeller *et al.*<sup>[2]</sup> tried to compare directional atherectomy (DA) combined with DCB to DCB alone in the DEFINITIVE AR study. One hundred two patients with claudication or rest pain were randomly assigned 1:1 to DA + DCB ( $n = 48$ ) or DCB alone ( $n = 54$ ), and 19 additional patients with severely calcified lesions were treated with DA + DCB. Mean lesion length was  $11.2 \pm 4.0$  cm for DA + DCB and  $9.7 \pm 4.1$  cm for DCB ( $P = 0.05$ ). Technical success was superior for DA + DCB (89.6% versus 64.2%;  $P = 0.004$ ). Overall bail-out stenting rate was 3.7%, and rate of flow-limiting dissections was 19% for DCB and 2% for DA + DCB ( $P = 0.01$ ). One-year primary outcome of angiographic percent diameter stenosis was  $33.6 \pm 17.7\%$  for DA + DCB versus  $36.4 \pm 17.6\%$  for DCB ( $P = 0.48$ ), and clinically driven target lesion revascularization was 7.3% for DA + DCB and 8.0% for DCB ( $P = 0.90$ ). Duplex ultrasound patency was 84.6% for DA + DCB, 81.3% for DCB ( $P = 0.78$ ), and 68.8% for calcified lesions. Freedom from major adverse events at 1 year was 89.3% for DA + DCB and 90.0% for DCB.

DA + DCB treatment was effective and safe, but the study was not powered to show significant differences

between the two methods of revascularization in the 1-year follow-up.

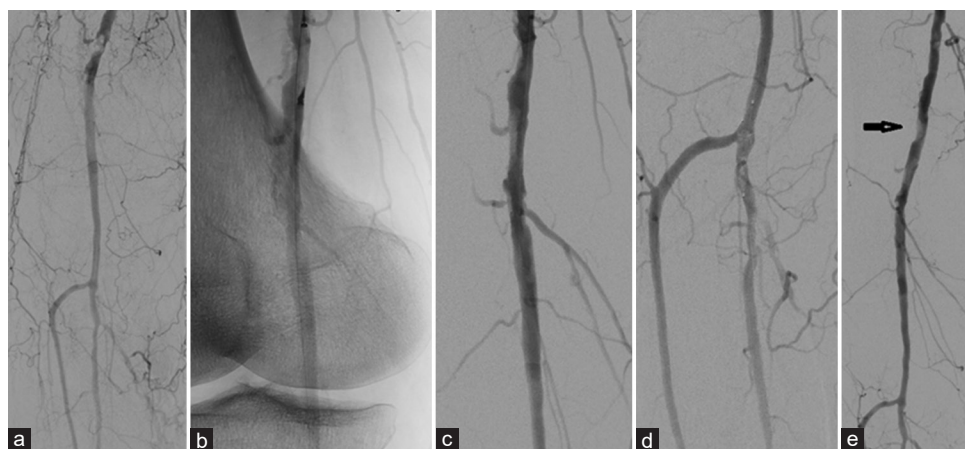
The tragedy of DA is that although it works well technically and gains successful technical outcome there is no proof<sup>[3]</sup> that DA is able to achieve a significant long-term benefit over balloon angioplasty in general. I am convinced, however, that is mainly due to the concept of trials and a true comparison dedicated to particular types of lesions— such as profoundly calcified eccentric lesions of the popliteal artery—would be able to show its usefulness and technical strength.

### Orbital atherectomy

Orbital atherectomy (Diamondback 360, CSI Inc., St. Paul, MN, USA) is an over-the-wire high-speed rotational system that wears an eccentric abrasive crown of different diameter (1.25–2 mm) at its tip and will be guided through eccentric lesions thus pulverizing hard wall material. An external nondisposable pump is used for cooling.

The calcium 360 study<sup>[4]</sup> compared 25 patients and below-the-knee lesions with PTA alone to 25 patients with PTA and orbital angioplasty. This small study showed a significant absence of adverse events in favor of atherectomy and a lower balloon pressure needed for angioplasty but no significant difference in freedom from reintervention.

The compliance 360 study<sup>[5]</sup> was a small randomized study on calcified lesions above the knee, comparing 25 patients (38 lesions) with orbital atherectomy and PTA to 25 patients (27 lesions) with PTA only. They found a lower pressure necessary for ballooning and a significant lower stent rate but no difference in 12-month patency, which was around 80% in both arms.



**Figure 1: Directional atherectomy. (a) Patient with rest pain and a highly eccentric stenosis of the P2 segment combined with advanced changes of the lower limb arteries. (b) Hawk One directional atherectomy system in place. (c) Significant debulking of the plaque was achieved by atherectomy only. (d) Protection device at the level of the trifurcation. Please note filling of the basket by debris. No further downward embolization happened. (e) Mild residual stenosis (arrow) at the P2 level with good patency of the popliteal artery**

### Rotational and aspiration atherectomy (Jetstream)

The Jetstream device (BSIC, Boston Mass) combines rotational atherectomy and active aspiration. It has a front cutter and side blades, which can be expanded to achieve a larger luminal gain. It comes with catheters from 1.6 mm to 3.4 mm in diameter. It comes with an external nondisposable console. It is not dedicated to calcified lesions alone but may be used with all types of obstructive material.

In a registry including 241 patients, the authors were able to demonstrate a good technical success and satisfying patency (TLR) at 12 months around 80%. Shammam *et al.* could retrospectively demonstrate significantly better patency combining Jetstream atherectomy with DCBs (94% vs. 68%).<sup>[6-9]</sup>

An intravascular ultrasound study was able to show that active and significant removal of intraluminal calcifications were possible by the use of this device.<sup>[9]</sup>

Higher rates of distal embolization up to 22%<sup>[8]</sup> has been reported with the Jetstream device; however, mainly in conjunction with in-stent restenosis or total occlusions.

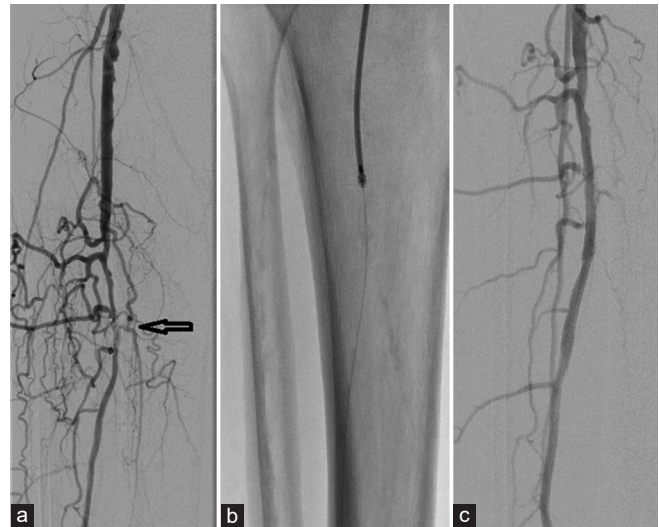### Hybrid atherectomy

Hybrid atherectomy describes an over-the-wire rotational atherectomy system (Phoenix, Philips Inc., Eindhoven, The Netherlands) that combines a high-speed rotating frontal cutter with passive suction in order to collect the abraded debris. It comes with a disposable drive and does not need an additional external console or motor. It has to be used with a dedicated guide-wire and comes with tip diameters of 1.8 mm, 2.2 mm, and 2.4 mm [Figure 2]. The 2.4 mm device is also deflectable to achieve a larger diameter.

Gandini *et al.*<sup>[10]</sup> recently published their results on 52 patients with moderately to highly calcified lesions with a mean length of 9.2 cm. They found good technical results and 12 months patency of 86%. Comparative data or randomized trials are not available for this device.

### Other devices

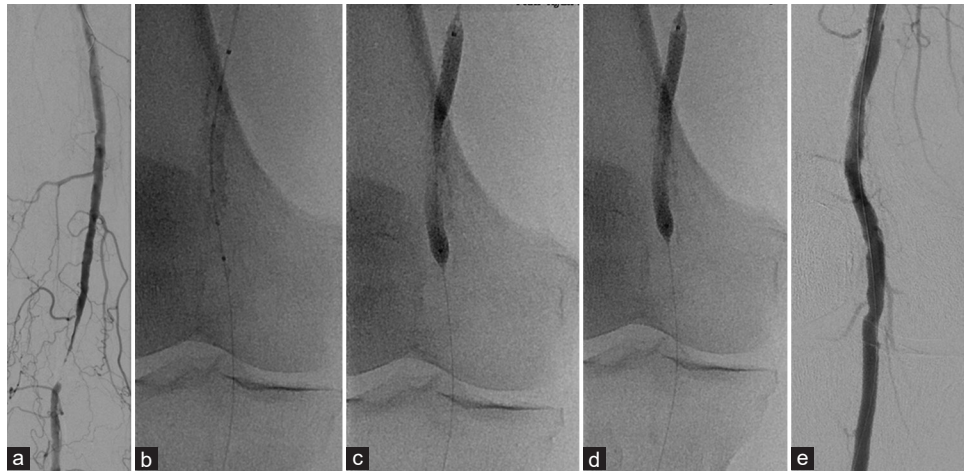
Among numerous devices that have been described for the purpose of atherectomy, there are two that might be mentioned. One is the Crosser device (Bard Inc., New Providence NJ) that uses high frequency vibration to overcome rigid and calcified lesions and is more meant to be a recanalization device but a debulking device but may be used for this purpose in very small arteries in the lower leg. The same purpose serves the Truepath device (BSIC, Boston, Massachusetts, USA) that wears an abrasive tip in front that is dedicated to facilitating passage through rigid lesions. Both devices have been described as safe, but no comparative data to established techniques are available.



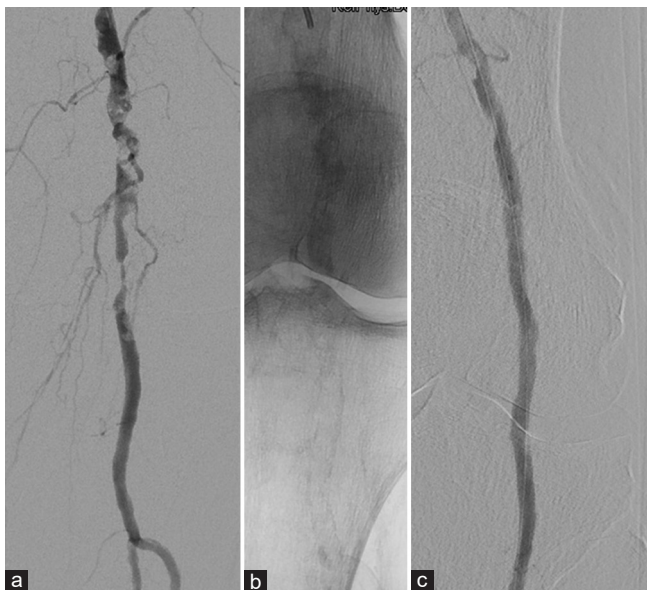**Figure 2: Hybrid atherectomy.** (a) Patient with stage IV (Fontaine) disease and single outflow via the fibular artery. Irregular ill defined calcified lesion (arrow) that was difficult to be passed by a 0.014 in guidewire but did not allow passage of any other device (balloon, support catheter). (b) A 2.2 mm Phoenix (Philips Inc) hybrid atherectomy device was used to debulk the lesion and to facilitate passage of a 3.0 mm 0.014 inch balloon catheter. (c) Following atherectomy and PTA a nice and wide lumen was created. No signs of peripheral embolization

### Lithoplasty

A relatively new technique is the application of shockwaves on mural plaques. The Shockwave Peripheral IVL System (Shockwave medical Inc., Santa Clara, California, USA) is indicated for lithotripsy-enhanced, low-pressure balloon dilation of calcified lesions. It delivers pulsatile sonic pressure waves locally to effectively modify vascular calcium. The system consists of a generator, a connector cable, and a catheter that houses an array of lithotripsy emitters enclosed in an integrated balloon. Once a calcified arterial lesion is crossed with a 0.014-inch guidewire, the IVL catheter is advanced to the lesion and positioned using radiopaque marker bands. The generator produces 3 kV of energy that travels through the connector cable and catheter to the lithotripsy emitters at 1 pulse/s. With the integrated balloon expanded to 4 atmospheres using a mixture of saline and contrast solution to achieve balloon-vessel wall apposition without significant angioplasty, a small electrical discharge at the emitters vaporizes the fluid and creates a rapidly expanding bubble within the balloon. This bubble generates a series of sonic pressure waves that travel through the fluid-filled balloon and pass through soft vascular tissue, ideally cracking the hardened, calcified plaque. The emitters positioned along the length of the device create a localized field effect within the vessel to fracture both intimal and medial calcium. The integrated balloon plays a double role: first, its apposition to the vessel wall enables efficient energy transfer, and second, it safely constrains the expansion of the bubble. Following calcium disruption, balloon is used as a usual PTA device up to a nominal pressure of 6 atm to maximize lumen gain.



**Figure 3: Shockwave lithoplasty (Popliteal artery stenosis).** (a) Female patient with calcification and a filiform but circumferentially calcified stenosis of the Pop 2 segment. (b) Lithoplasty balloon in place but yet not inflated. (c) Shockwave lithoplasty balloon on site inflated with a pressure of 3 atm but not yet activated. (d) Shockwave lithoplasty balloon on site inflated with a pressure of 3 atm but after delivery of 10 shocks. (e) Angiography after full circle of 300 shocks and additional balloon angioplasty



**Figure 4: Shockwave lithoplasty (Irregular popliteal artery stenosis).** (a) Patient suffering from severe rest pain and trophic changes (Fontaine IV) with a mid-size highly irregular partly eccentric popliteal stenosis in the Pop 2 segment. (b) Native image shows long and extensive calcifications of the wall. (c) After lithoplasty and ballooning regular and smooth lumen regained

This cycle can be repeated until a maximum of 300 pulses has been delivered per device.

By this, the plaque is supposed to be softened and the plaque structure is broken up. Calcified material will stay within the wall but will be rearranged and flattened. There is no risk of embolization, as no material is removed and collected.

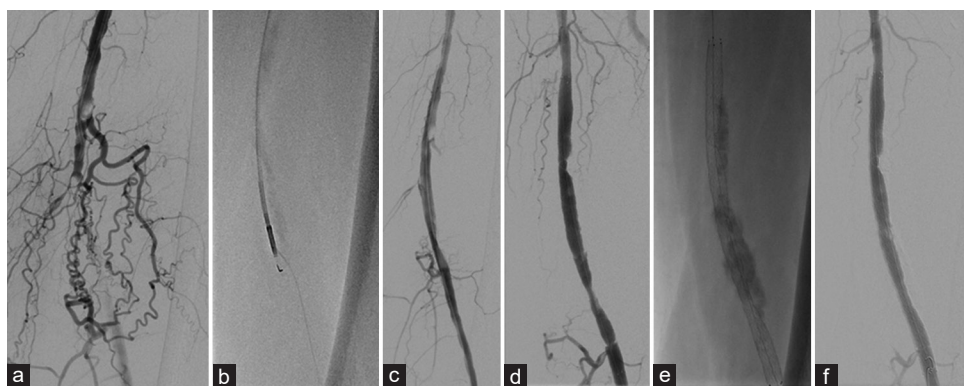
The technique has been tested to be safe. The numbers of published cases are relatively low for peripheral cases, and no randomized data exist. The amount of calcification was very mixed in the published cases,

and the system was applied to a more or less average population of patients with peripheral arterial disease. A rising number of publications also about coronary applications have also been published. Brodmann *et al.* published their first experience below the knee.<sup>[11]</sup> The Disrupt BTK study was a prospective, nonrandomized, multicenter, feasibility, and safety trial that enrolled 20 patients. Fifteen patients had Rutherford category 5 ischemia, and all patients had moderate to severe below-the-knee arterial calcification. Patients were followed for 30 days.

Catheter delivery was successful in 19 patients. The composite of major adverse events at 30 days was 0%. The acute reduction in percent diameter stenosis of target lesions was 46.5%. All patients achieved residual diameter stenosis  $\leq 50\%$ . Vascular complications were minimal with only one type B dissection reported and 2 stents placed. None of the subjects experienced thrombus formation, abrupt closure, distal embolization, or perforation. There were no device-related complications.

In a larger study,<sup>[12]</sup> authors published their results of the Disrupt PAD II study, which was a nonrandomized, multi-center study that enrolled 60 subjects with so-called complex, calcified peripheral arterial stenosis. Anyhow the morphology varied from no calcifications to severe with a medium amount of calcium in its majority. Patients were treated with lithoplasty and followed up to 12-months. The primary safety endpoint was major adverse events through 30 days. The primary effectiveness endpoint was patency at 12 months.

The final residual stenosis was 24.2%, with an average acute gain of 3.0 mm. The 30-day MAE rate was 1.7%, with one severe dissection that required stent placement. Primary patency at 12 months was 54.5%, and clinically driven TLR at 12 months was 20.7%. The optimized



**Figure 5: Shockwave lithoplasty (Eccentric calcifications and subintimal pathway).** (a) Middle sized occlusion of the superficial femoral artery (Fontaine stage IV) with moderate collateralization. (b) Solid calcifications prevent endoluminal passage but by use of a reentry device (Outback, Cordis Inc.) the true lumen can be reentered via a subintimal pathway. (c) After balloon angioplasty an insufficient lumen can be achieved. (d) After placing a long self-expanding stent two compression zones are still present. (e) Native image shows the massive calcifications partly compressing the stent. (f) After additional lithoplasty, the distal compression could be resolved while the proximal compression was only partly improved

technique defined by correct balloon sizing improved 12-month primary patency and TLR outcomes to 62.9% and 8.6%, respectively.

There are no randomized studies yet comparing the system to debulking techniques and/or PTA. Nevertheless, the system is expensive, and interventionalists need advice in which cases the system should be used.

From a practical view on a case-to-case experience, this technique is very easy to apply, is technically reliable and safe. We have the feeling that it works particularly well in circumferential calcified lesions [Figures 3 and 4] while in eccentric calcifications, it seems to be less effective [Figure 5]. Some patients feel some painful nerve stimulation, especially at the pop 2 and 3 levels during activation. It is not yet sure how effective the system will be when residual stent stenosis due to compression of underlying plaque material needs to be cracked. The results for this particular situation in our hands were yet of mixed efficacy. All these questions need to be scientifically answered, but until now, the systems seem to be a valuable additional tool in the treatment of calcified plaques— at least concentric ones.

### Critical evaluation

Technically, many of these devices do for what they have been designed: debulking of lesions without major dissections. The problem is however, that they are usually expensive and will have an impact on treatment costs. Most of them are a little bulky and require larger introducing systems. The technical outcome frequently is very good with low residual stenosis and smooth surface. Debulking devices, however, create their own new complications with macro- and microembolization, which are feared and may drastically impair a clinical situation.

On the other hand, it has been missed to prove that these devices really lead to improved patency over time. This is not surprising as firstly, the technical outcome

is not necessarily correlated to long-term cause of the underlying disease. So, the factors influencing restenosis still exist and may – albeit never tested or investigated – be bolstered by the debulking procedure. Secondly, most of the devices have been tested on a general population of atherosclerotic lesions, which can be easily treated by balloon angioplasty and or stenting likewise. This will make it difficult to distillate the individual advantages of these new devices.

One solution to this could be that trials with these new devices focus on the challenging types of lesions (heavily calcified and eccentric) and locations (popliteal segment 2 and 3) where stents are no good option instead of being tested on an average group of SFA and popliteal lesions where particular technical and clinical advantages of the new techniques are likely to be blurred by the overwhelming influence of simple lesions.

For the day-to-day business, we should select these helpful instruments by the type of problem we want to solve: lithoplasty in circumferentially calcified lesions, directional or rotational atherectomy in eccentric calcifications, rotational atherectomy and or high-frequency ablation in tight stenosis of lower limb arteries. By this, we have highly dedicated tools on hand to warrant technical success even in lesions otherwise difficult to treat. Long term benefits still have come to be validated.

### Financial support and sponsorship

Nil.

### Conflicts of interest

There are no conflicts of interest.

### References

1. Dippel EJ, Makam P, Kovach R, George JC, Patlola R, Metzger DC, *et al.* Randomized controlled study of excimer laser atherectomy for treatment of femoropopliteal in-stent restenosis: Initial results from the EXCITE ISR trial (EXCimer Laser

- Randomized Controlled Study for Treatment of Femoropopliteal In-Stent Restenosis). *JACC Cardiovasc Interv* 2015;8:92-101.
2. Zeller T, Langhoff R, Rocha-Singh KJ, *et al.* Directional Atherectomy Followed by a Paclitaxel-Coated Balloon to Inhibit Restenosis and Maintain Vessel Patency: Twelve-Month Results of the DEFINITIVE AR Study. *Circ Cardiovasc Interv* 2017;10: pii: e004848. doi: 10.1161/CIRCINTERVENTIONS.116.004848.
  3. Ambler GK, Radwan R, Hayes PD, Twine CP. Atherectomy for peripheral arterial disease. *Cochrane Database Syst Rev* 2014;17:CD006680. doi: 10.1002/14651858.CD006680.pub2.
  4. Shammam NW, Lam R, Mustapha J, Ellichman J, Aggarwala G, Rivera E, *et al.* Comparison of orbital atherectomy plus balloon angioplasty vs. balloon angioplasty alone in patients with critical limb ischemia: Results of the CALCIUM 360 randomized pilot trial. *J Endovasc Ther* 2012;19:480-8.
  5. Dattilo R, Himmelstein SI, Cuff RF. The COMPLIANCE 360° Trial: A randomized, prospective, multicenter, pilot study comparing acute and long-term results of orbital atherectomy to balloon angioplasty for calcified femoropopliteal disease. *J Invasive Cardiol* 2014;26:355-60.
  6. Shammam N, Shammam G, Banerjee S, Popma JJ, Mohammad A, Jerin M. Jet stream rotational and aspiration atherectomy in treating in-stent restenosis of the femoropopliteal arteries: Results of the JETSTREAM-ISR feasibility study. *J Endovasc Ther* 2016;23:339-46.
  7. Gray W, Garcia L, Amin A, Shammam NW; JET Registry Investigators. Jet stream atherectomy system treatment of femoropopliteal arteries: Results of the post-market JET Registry. *Cardiovasc Revasc Med* 2018;19:506-11.
  8. Reeves R, Imsais JK, Prasad A. Successful management of lower extremity distal embolization following percutaneous atherectomy with the Jet stream G3 device. *J Invasive Cardiol* 2012;24:E124-8.
  9. Maehara A, Mintz GS, Shimshak TM, Ricotta JJ 2<sup>nd</sup>, Ramaiah V, Foster MT 3<sup>rd</sup>, *et al.* Intravascular ultrasound evaluation of JETSTREAM atherectomy removal of superficial calcium in peripheral arteries. *EuroIntervention* 2015;11:96-103.
  10. Gandini R, Pratesi G, Merolla S, *et al.* Single Center Experience With Phoenix Atherectomy System in Patients With Moderate-Heavily Calcified Femoropopliteal Lesions *Cardiovasc Revasc Med* 2019;23:pii: S1553-8389(19)30492-0. doi: 10.1016/j.carrev.2019.08.019. [Epub ahead of print].
  11. Brodmann M, Holden A, Zeller T. Safety and feasibility of intravascular lithotripsy for treatment of below-the-knee arterial stenoses. *J Endovasc Ther* 2018;25:499-503.
  12. Brodmann M, Werner M, Holden A, Tepe G, Scheinert D, Schwindt A, *et al.* Primary outcomes and mechanism of action of intravascular lithotripsy in calcified, femoropopliteal lesions: Results of disrupt PAD II. *Catheter Cardiovasc Interv* 2019;93:335-42.