

---

## Concealed vascular injury during coiling of intracranial aneurysm leading to severe resistant hypotension and poor outcome: The lesson learnt

***Vinay Byrappa, Ashwini Halesh, Hima Pendharkar<sup>1</sup>, Madhusudan Reddy K. R***

Intracranial aneurysms are increasingly being managed through endovascular route. Interventional

neuroradiology (INR) procedures are safe but complications can be rapid and catastrophic.<sup>[1]</sup> Here, we describe a known complication of endovascular technique, leading to severe intraoperative hypotension and poor outcome.

A 70-yr-old lady with ruptured left distal anterior cerebral artery (DACA) aneurysm was posted for coiling of aneurysm under general anaesthesia [Figure 1a]. The patient came with a history of sudden onset of headache and brief loss of consciousness 5 days back. On examination patient was conscious and oriented (Glasgow coma scale E<sub>4</sub>V<sub>5</sub>M<sub>6</sub>) with Fischer grade of 3 and WFNS grade 1. She was a known hypertensive. Patient was induced with thiopentone 250 mg, fentanyl 100 µg and rocuronium 50 mg. Induction was uneventful. Anaesthesia was maintained with 0.6% isoflurane in N<sub>2</sub>O and O<sub>2</sub>.

After right femoral arterial puncture, a 7-Fr long sheath was introduced. Heparin 5000 units were given

Departments of Neuroanaesthesia and <sup>1</sup>Neuroimaging and Interventional Radiology, National Institute of Mental Health and Neurosciences, Bangalore, Karnataka, India

---

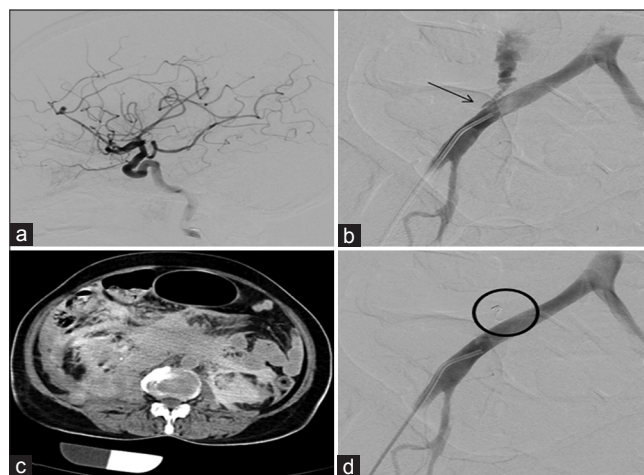
**Address for correspondence:**

Prof. Madhusudan Reddy K. R, Department of Neuroanaesthesia, National Institute of Mental Health and Neurosciences, Bangalore - 560 029, Karnataka, India. E-mail: krmsr2000@yahoo.com

intravenously. In view of associated vasospasm in the anterior communicating artery (ACA) territory, nimodipine infusion was started at 0.2 mg/hr. Activated clotting time (ACT) was 410 sec. The aneurysm was then coiled as per standard protocol.

About 1 hour into the procedure hypotension (90-100/65-70 mmHg) was noted, initially we thought it to be because of nimodipine infusion so we decreased the rate of infusion and 6 mg of i.v mephentaramine was given. But there was no significant improvement in the BP. At the same time a check angio revealed an increased mean transit time of the contrast suggesting a sluggish flow and increased ICP, but there was no rupture of the aneurysm as the aneurysm was already secured. One litre bolus of crystalloid was given and norepinephrine infusion at the rate of 3 mcg/kg/min was started but the hypotension worsened and persistent hypotension (70-80/50-55 mmHg) was noted refractory to fluid therapy and inotropes. The puncture site was immediately inspected and generalised abdominal distension was noted. Sequential angiogram from arch to the right external iliac artery revealed extravasation of contrast from right superior margin of right common iliac artery [Figure 1b] with active extravasation of contrast into the peritoneal cavity [Figure 1c]. A microcatheter was passed through the perforation and a 2 mm × 3 cm coil was deployed followed by a drop of Onyx which sealed the perforation completely [Figure 1d]. Mean time we reversed the effect of heparin by giving Inj protamine 50 mg i.v. slowly over a period of 15 minutes.

Arterial blood gas showed significant metabolic acidosis with a pH of 7.1 and Hb was 3.8 g%, PaCO<sub>2</sub> 27.6 mmHg,



**Figure 1:** (a) Left ICA lateral view: Saccular distal anterior cerebral artery aneurysm with proximal vasospasm (b) Exploratory angiogram shows site of perforation (black arrow) with free contrast extravasation from the superior margin of right common iliac artery (c) CT abdomen shows a large retroperitoneal haematoma predominantly on the right with extension to the left (d) Check angiogram shows complete closure of the perforation. Note the occluding coil (encircled black) that lies within the track

PaO<sub>2</sub> 534 mmHg and base deficit of -17.6. Noradrenalin infusion was increased to 5 µg/kg/min. The patient was transfused with 8 units of packed RBCs, 2 units FFPs and the blood pressure was maintained between 100 and 110 mmHg systolic with dopamine/adrenaline/noradrenalin infusion. Post-operatively patient was haemodynamically unstable on inotropic supports with a GCS of E<sub>1</sub>V<sub>1</sub>M<sub>2</sub> and was transferred to ICU for further management. In the ICU, patient developed DIC and multiorgan dysfunction led to death.

Interventional neuroradiology procedures (INR) usually involve introducing catheters into the arterial circulation of the head, neck or spine. The trans-femoral arterial approach is commonly used. Complications in INR can be central nervous system (CNS) and non-CNS related. CNS complications are aneurysmal rupture, thromboembolism, vasospasm, non-target coil detachment; non-CNS complications are contrast reaction, haemorrhage at puncture site, groin and retroperitoneal haematoma.<sup>[2]</sup> Kent KC<sup>[3]</sup> *et al.*, evaluated 9858 femoral artery catheterisations over 5 years and noted that retroperitoneal haematoma developed in 45 (0.5%) patients. The identified risk factors were protocol for sheath removal, female sex, nadir platelet count and excessive anticoagulation. Among 45 patients, four patients developed hypotension early after catheterisation unresponsive to fluid therapy. Though in our case platelet count was normal and ACT was maintained at 400 sec, age-related atherosclerotic changes might have predisposed to arterial perforation secondary to guide wire manipulation. It is very interesting to find that though vascular injury has been described previously with interventional cardiology procedures but they have been not reported with INR procedures. It is important to know that once the micro-catheters are placed in to the vessels of interest, further visualisation is limited to this area. Hence it is possible to overlook complications arising due to the femoral puncture/catheterisation at the site of puncture. This possibility is higher in the INR procedures than in cardiovascular procedures.

On careful evaluation it is interesting to know that the cause for poor neurological outcome in our patient is due to a sustained low blood pressure even after securing the aneurysm. The multitude of factors which might have played a role in leading to in our patients is:

- Age of the patient (70 yrs), associated chronic hypertension and diffuse atherosclerotic changes in the great vessels leading to vascular injury during manipulation of the micro-catheter
- Even though the aneurysm was secured, the flow in the cerebral vasculature had become sluggish due to raised intracranial pressure during the procedure. This can be explained by the raised intra-abdominal pressure (IAP) due to haemoperitoneum leading to transmission of increased IAP to the thorax leading

to increased intrathoracic pressure and central venous pressure, decreased venous return from the brain and increased ICP<sup>[4]</sup>

- Patients with aneurysmal SAH have disturbed autoregulation of cerebral blood flow. Hence, intraoperative hypotension of any cause has an adverse effect on the outcome of SAH<sup>[5,6]</sup>
- Patients with poor grade SAH (Fischer III/IV) and angiographic evidence of vasospasm which our patient had, are at risk for cerebral hypoperfusion because of impaired cerebral autoregulation and thus intraoperative hypotension and cerebral hypoperfusion compounds the poor outcome<sup>[6,7]</sup>
- Blood loss leading to severe anaemia (Hb 3.8 g%) during the procedure might have lead to decreased oxygen-carrying capacity of blood and further exacerbate the hypoxic injury to brain.

Thus a combination of age, poor grade SAH, diffuse atherosclerosis, pre-existing vasospasm, raised intra-abdominal pressure leading to raised ICP, severe anaemia and delayed diagnosis and management of perforated iliac artery injury lead to poor clinical outcome in our patient.

This case demonstrates that possibility of catastrophic vascular perforation with intra-abdominal haematoma although rare, must be considered during INR procedures when severe hypotension unresponsive to fluid management develops during the procedure. The combination of severe hypotension with elevated intra-abdominal pressure in poor grade SAH can have deleterious effect on intracranial compliance leading to poor neurological outcome in patients with sub-arachnoid haemorrhage and pre-existing vasospasm. Thus, the anaesthesiologist must be aware of this complication and should anticipate and inform the interventional

radiologist regarding vascular injury when there is refractory hypotension so that necessary steps can be taken to identify and treat iatrogenic complications that might compound the pre-existing morbidity.

## REFERENCES

1. Young WL, Pile-Spellman J. Anesthetic considerations for interventional Neuroradiology (Review). *Anesthesiology* 1994;80:427-56.
2. Varma MK, Price K, Jayakrishnan V, Manickam B, Kessell G. Anaesthetic considerations for interventional neuroradiology. *Br J Anaesth* 2007;99:75-85.
3. Kent KC, Moscucci M, Mansour KA, Dimattia S, Gallagher S, Kuntz R, *et al.* Retroperitoneal hematoma after cardiac catheterization: Prevalence, risk factors, and optimal management. *J Vasc Surg* 1994;20:905-10.
4. De Laet I, Citerio G, Malbrain ML. The influence of intraabdominal hypertension on the central nervous system: Current insights and clinical recommendations, is it all in the head? *Acta Clin Belg Suppl* 2007;1:89-97.
5. Chang HS, Hongo K, Nakagawa H. Adverse effects of limited hypotensive anesthesia on the outcome of patients with subarachnoid hemorrhage. *J Neurosurg* 2000;92:971-5.
6. Voldby B, Enevoldsen EM, Jensen FT. Cerebrovascular reactivity in patients with ruptured intracranial aneurysms. *J Neurosurg* 1985;62:59-67.
7. Rabinstein AA, Friedman JA, Weigand SD, McClelland RL, Fulgham JR, Manno EM, *et al.* Predictors of cerebral infarction in aneurysmal subarachnoid hemorrhage. *Stroke* 2004;35:1862-6.

Access this article online	
Quick Response Code:	Website: www.jnaccjournal.org
	DOI: 10.4103/2348-0548.139118