

# Role of volumetric three-dimensional computed tomography in guiding the treatment of a dentigerous cyst associated with a mesiodens, approaching the nasal cavity

Chetna Arora, Rohit Bahri<sup>2</sup>, Varun Kapoor, Samrity Paul<sup>1</sup>

Departments of Conservative Dentistry and Endodontics, and <sup>1</sup>Oral and Maxillofacial Surgery, Swami Devi Dayal Dental College, Panchkula, Haryana, <sup>2</sup>Orthodontics, Post Graduate Institute of Medical Sciences and Research, Chandigarh, India

Address for correspondence:

Dr. Chetna Arora,  
Department of Conservative  
Dentistry and Endodontics,  
Swami Devi Dayal Dental College,  
Panchkula, Haryana, India.  
E-mail: drchetnaarora1@gmail.com

## ABSTRACT

This is a case report highlighting the role of volumetric three-dimensional computed tomography (3D-CT) in the treatment of a dentigerous cyst (DC) associated with a mesiodens approaching the nasal cavity. The incidence and histopathogenesis of DC associated with mesiodens have been discussed. The advantages of volumetric multi-slice light speed 3D-CT imaging over alternative CT imaging techniques have also been discussed.

## Key words

Dentigerous cyst, mesiodens, three-dimensional computed tomography

## INTRODUCTION

Dentigerous cyst (DC) is a cyst, which encloses the crown of an unerupted tooth by expansion of dental follicle, and is attached to the tooth neck.<sup>[1]</sup> DCs are the second most common odontogenic cysts. However, only 5-6% DCs are found in association with supernumerary teeth, 90% of which are associated with mesiodens.<sup>[2]</sup> This is probably because mesiodens are the most commonly impacted supernumerary teeth with an incidence of 0.5-1.9%.<sup>[3]</sup> They may result in a host of complications ranging from diastema, delayed eruption or altered position of incisors, to root resorption or even DC formation.<sup>[3]</sup> Further, 62.5-67% mesiodens are found impacted in an inverted position.<sup>[3,4]</sup> This is important because mesiodens tend to migrate and move along the direction of their crowns, often taking them to region of poor surgical access such as the mid-palate or nasal cavity.<sup>[3,5]</sup>

While regular two dimensional radiographs are adequate to primarily diagnose DCs with mesiodens, advanced

imaging techniques such as computed tomography (CT) for intra-osseous lesions are important in cases of proximity to vital anatomic structures, for visualization and clearer delineation.

This article reports a similar, uncommon incidence of a DC associated with a long standing impacted, inverted mesiodens, with resultant proximity to the nasal floor, as well as discoloration and root resorption of associated incisors, thereby necessitating advanced three-dimensional (3D) CT imaging. It discusses the pros and cons of volumetric light speed 3D-CT imaging in comparison to alternative CT methods for visualization of oral and maxillofacial pathology.

## CASE REPORT

A 23-year-old male patient was referred by a general dentist to our department with a unilateral swelling in the left anterior palate. The maxillary left central and lateral incisors were discolored. Diagnostic intraoral periapical radiography revealed the presence of a radiolucent lesion in the anterior maxilla associated with an inverted impacted mesiodens [Figure 1]. The apical portion of left maxillary lateral incisor root was resorbed [Figure 1] and a Panoramic radiograph [Figure 2] reiterated the same. Thermal vitality test and electrical pulp testing (Vitality Scanner, Analytic Technology, Glendora CA, USA) resulted in lingering pain in 21, 22, 23, and 24. On the basis of these clinical and radiographic features, a

### Access this article online

Quick Response Code:



Website:  
www.ejgd.org

DOI:  
10.4103/2278-9626.112326

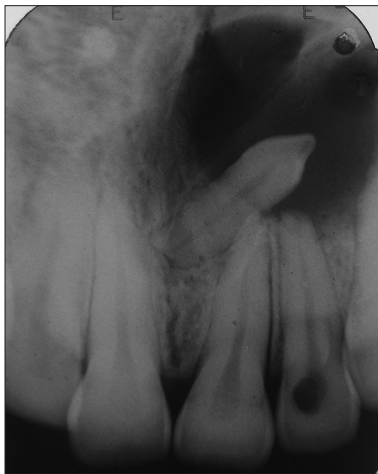diagnosis of DC was made, with radicular cyst as possible differential diagnosis, along with chronic irreversible pulpitis in the involved teeth.

To confirm the extent of lesion, three dimensional imaging with the help of 64 slice CT scan (light speed Volumetric CT, GE Healthcare, NY, USA) of the maxilla was performed. With the help of Dentascan software (GE, Milwaukee, WI, USA) images of the maxilla were constructed in all the three planes (axial, sagittal, and coronal planes). The axial sections showed the perforation of labial cortical plate [Figure 3] and the Coronal and sagittal section showed the involvement of roots of teeth within the lesion, from the left maxillary central incisor to premolar [Figures 4-6]. The 3D-CT images of maxilla confirmed that the lesion was very close to the nasal floor [Figure 7], with a fortuitous absence of the nasal or palatal perforation.

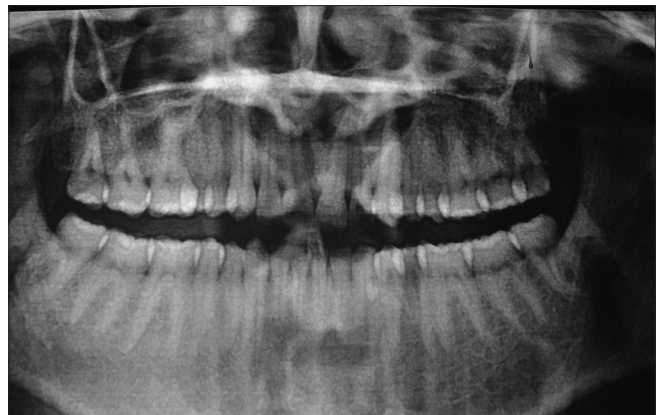The therapeutic approach included enucleation of the lesion, surgical extraction of mesiodens and

endodontic treatment of the four affected teeth. Single visit root canal treatment of the left maxillary central incisor to premolar was performed. Enucleation was performed under local anesthesia (2% lignocaine with 1:80,000 adrenaline). A window was fabricated in the labio-buccal bone plate, and the lesion was enucleated along with the mesiodens [Figure 8]. Curettage of the surgical site was performed for the removal of epithelial remnants. Retrograde condensation of Pro-root white Mineral Trioxide Aggregate (Dentsply mallifer) was done in roots of the lateral incisor, as it was partly resorbed. Surgical site was closed and the patient recalled after 1 week for suture removal and follow-up, which was uneventful.

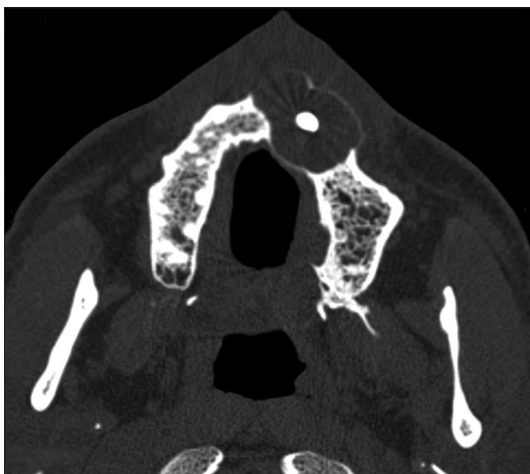
The histological examination of the lesion confirmed the diagnosis of DC. After 1 month, the endodontically treated teeth were restored with Porcelain Fused to Metal crowns. The patient has remained under follow-up for 1 year, with radiographically documenting decrease in the size of radiolucency and significant bony healing with new trabecular formation [Figure 9].



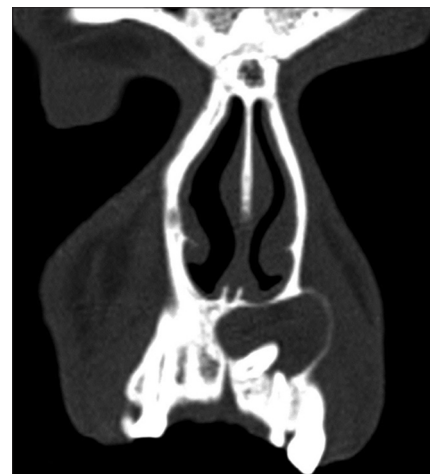**Figure 1:** Intra oral peri apical radiograph shows the radiolucency around the inverted and impacted mesiodens. There is resorption of the roots of maxillary left lateral incisor



**Figure 2:** Orthopantomogram shows the radiolucency involving the mesiodens but the extent of the lesion is not clearly visible



**Figure 3:** Axial section of three-dimensional computed tomography shows perforation of labial cortical plate



**Figure 4:** Coronal section shows the involvement of roots of maxillary left first premolar within the lesion

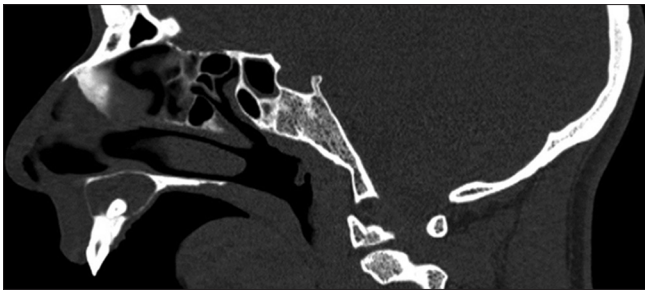


Figure 5: Sagittal section shows the involvement of the root of maxillary left central incisor with in the lesion

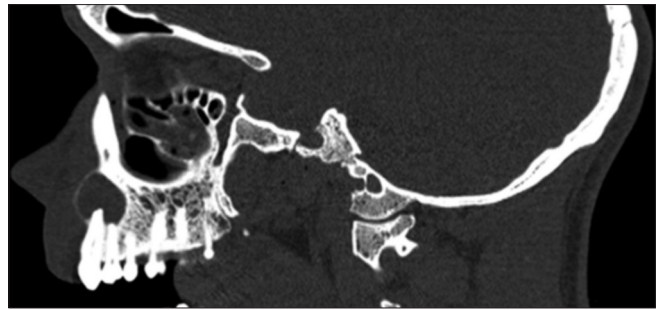


Figure 6: Sagittal section shows the involvement of the roots of maxillary left first premolar with in the lesion

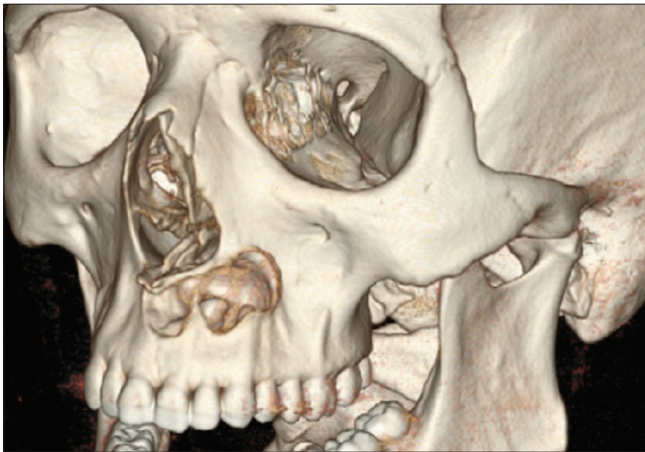

Figure 7: Three-dimensional view shows the perforation of the labial cortical plate with absence of nasal perforation

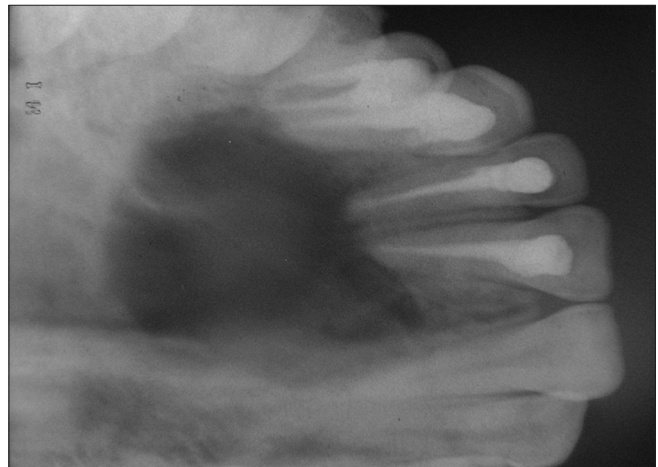


Figure 8: Immediate occlusal view after the enucleation of the cyst

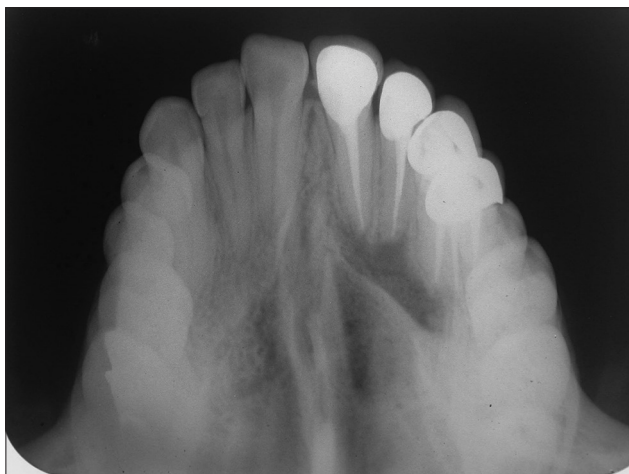

Figure 9: Occlusal view after 1 year shows bony healing

## DISCUSSION

The scarcely reported incidence of DCs occurring in association with mesiodens teeth varies from 2.7%<sup>[6]</sup> to 11%.<sup>[3]</sup>

Supernumerary teeth are believed to be of dental lamina origin, arising from either a third molar tooth bud near the secondary (permanent) tooth bud, or by splitting of the secondary tooth bud itself.<sup>[2,6]</sup> This

theory is supported by the fact that supernumerary teeth resemble their neighbors. Familial incidence has also been reported.<sup>[7]</sup> Mesiodens are further known to retain their eruptive potential even while impacted, and migrate along the direction of their crowns. The pressure exerted by the potentially erupting tooth on the impacted follicle is also responsible for DC formation. Eruptive pressures obstruct venous outflow, inducing rapid serum transudation across capillary walls, resulting in raised hydrostatic pressure, which separates the follicle from crown; altered capillary permeability later allows osmotic protein passage into the transudate.<sup>[1]</sup>

Unfortunately (as discussed earlier), the most common position of an impacted mesiodens is inverted. Its misguided eruptive forces, potential tooth migration, and direction of cyst expansion are, therefore, all directed away from the dentoalveolar region, and towards the nasal floor, canine-premolar region, or mid-palate, or, as in our case, both nasally and palatally.

In our patient, treatment was further complicated by discoloration and root resorption of the adjacent maxillary incisor, necessitating root canal treatment and retrograde restoration. Root resorption is an unfortunate characteristic of impacted mesiodens as well as DCs. It is considered a manifestation of dental follicular origin, and



the ability of the dental follicle of a potential successor to resorb the roots of its predecessor, in an attempt to replace it.<sup>[1]</sup>

While marsupialization and enucleation with open packing are often employed for treatment of DCs, they are required when the tooth impacted in the cyst can be preserved for masticatory function, as is the case with impacted canines or premolars. This is not the case with supernumerary teeth or third molars. It, therefore, made no surgical sense to employ these alternative treatment modalities, with their attendant limitations of longer treatment, patient discomfort and incomplete eradication of pathology. The surgical implications clearly indicated that the present lesion had to be enucleated in-toto, with minimal surgical damage to nasal apparatus or the incisors, and avoidance of a palatal perforation, thereby necessitating advanced imaging for better pre-operative visualization and delineation of the pathology from its bony bed and the nasal floor/walls, if in close proximity.

For intra-osseous lesions, CT has been the imaging technique for many decades now. While radiographs are the two dimensional image of a 3D structure, CT provides imaging in not only the mesiodistal (as with radiographs), but also the buccolingual plane.<sup>[8]</sup> They provide the images in mesiodistal plane but not in buccolingual plane. Its benefits are further enhanced by 3D-CT imaging. Volumetric computed tomography (64 slice CT scan, Light speed Volumetric CT, GE Healthcare, NY, USA) was therefore employed in this case. Volumetric method, light speed, and 64 slice CT scanner – all have significant advantages over other 3D-CT techniques.

There are two ways to obtain 3D-CT images, based on a surface based or volume based method. Out of these, volumetric 3D-CT holds most aces. This is due to preservation of all vowels during volumetric 3D-CT construction, resulting in superior final 3D image construction. The use of transparency and color enhancement tools allows a better appreciation of the differences in surface characteristics and textures of various anatomic structures, such as normal bone, and nasal and palatal apparatus, in contrast to the pathological part. The volumetric method also has advantages over surface based technique in terms of greater precision (especially in linear measurements) and sensitivity. Cavalcanti and Antunes (2002) found a sensitivity of 94.2% with the volumetric method of 3D-CT construction in delineation of oral and maxillofacial lesions, in contrast to only 46% sensitivity of surface based 3D-CTs.<sup>[9]</sup> The specificity of both methods is comparable.

Manufacturers make an evidence based claim that light speed volumetric CT provides higher resolution and 73% more coverage per second as compared to a 32-40 slice CT scanner. A 64 slice CT scanner provides 400 mm coverage per rotation, in sharp contrast to the 10 mm coverage per rotation of a 16 slice CT scanner. Furthermore, as compared to the 16 slice system, 64 slice light speed Volumetric CT has the advantage of a four-fold decrease in acquisition time, well-illustrated by the fact that a better resolved complete body scan can be completed in less than 10 s with this system.

Volume based light speed 3D-CT helped us recognize the pre-operative extent of the lesion and also illustrated the distance between lesion and the nasal and palatal apparatus, thereby simplifying surgical planning. The only equivalent in imaging equality to volume based light speed 3D-CT would be cone beam CT (for dental use), which has the added advantage of lower radiation dose.<sup>[10]</sup> These are, therefore, recommendable for the pre-operative imaging of oral and maxillofacial pathology with unique anatomic associations, and also for well-documented comparative follow-up post-operatively.

## REFERENCES

1. Shear M, Speight P. Dentigerous cyst. In: Shear M, Speight P, editors. *Cysts of the Oral and Maxillofacial Regions*. Oxford: Blackwell Munksgaard; 2007. p. 59-75.
2. Lustmann J, Bodner L. Dentigerous cysts associated with supernumerary teeth. *Int J Oral Maxillofac Surg* 1988;17:100-2.
3. Asaumi JI, Shibata Y, Yanagi Y, Hisatomi M, Matsuzaki H, Konouchi H, *et al.* Radiographic examination of mesiodens and their associated complications. *Dentomaxillofac Radiol* 2004;33:125-7.
4. Roychoudhury A, Gupta Y, Parkash H. Mesiodens: A retrospective study of fifty teeth. *J Indian Soc Pedod Prev Dent* 2000;18:144-6.
5. Chopra SS, Joshi MR. Mesiodens erupted in the nasal cavity. Report of a case. *Oral Surg Oral Med Oral Pathol* 1969;28:856-8.
6. Von Arx T. Anterior maxillary supernumerary teeth: A clinical and radiographic study. *Aust Dent J* 1992;37:189-95.
7. Sedano HO, Gorlin RJ. Familial occurrence of mesiodens. *Oral Surg Oral Med Oral Pathol* 1969;27:360-1.
8. Patel S, Dawood A, Whaites E, Pitt Ford T. New dimensions in endodontic imaging: Part 1. Conventional and alternative radiographic systems. *Int Endod J* 2009;42:447-62.
9. Cavalcanti Mde G, Antunes JL. 3D-CT imaging processing for qualitative and quantitative analysis of maxillofacial cysts and tumors. *Pesqui Odontol Bras* 2002;16:189-94.
10. Hashimoto K, Kawashima S, Kameoka S, Akiyama Y, Honjaya T, Ejima K, *et al.* Comparison of image validity between cone beam computed tomography for dental use and multidetector row helical computed tomography. *Dentomaxillofac Radiol* 2007;36:465-71.

**How to cite this article:** Arora C, Bahri R, Kapoor V, Paul S. Role of volumetric three-dimensional computed tomography in guiding the treatment of a dentigerous cyst associated with a mesiodens, approaching the nasal cavity. *Eur J Gen Dent* 2013;2:187-90.

**Source of Support:** Nil, **Conflict of Interest:** None declared.