

Mesiodens used for allotransplantation

Suryakanth M. Pai, Piyusha S. Patil[†], P. Poornima, V. V. Subbareddy

Departments of Pedodontic and Preventive Dentistry, College of Dental Sciences, Davangere,

[†]Pedodontic and Preventive Dentistry, Bangalore, Karnataka, India

Address for correspondence:

Dr. Piyusha S. Patil,
#30/90, 43rd Cross, 5th Main, Jayanagar
5th Block, Bangalore - 560 041,
Karnataka, India.
E-mail: piyushapatil@gmail.com

ABSTRACT

This is a case report of an 11-year-old male patient in whom a mesiodens from a donor was used as an allotransplant to replace his missing central incisor. The treatment results over 1 year showed successful periodontal healing and functioning of the allotransplanted tooth. The aim of this paper is to report a procedure, allotransplantation of tooth, which is followed from ages but less preferred and documented and is surrounded by variable prognosis and also highlight the use of a mesiodens, which in any case has to be extracted and usually of no other use.

Key words

Allotransplantation of human tooth, mesiodens, missing central incisor

INTRODUCTION

Allotransplantation of tooth is the transplantation of tooth sourced from a genetically non-identical member of the same species as the recipient. From being a method of rather poor prognosis, allotransplantation has developed to be a safe treatment procedure. Scientific criteria for selecting patients, donor teeth, surgical procedures and post-operative care have contributed to this. With the advent of dental implants and its increasing usage, allotransplantation has not been considered as a regular treatment option any more. However, in poorer third world countries allotransplantation if done properly could surely be a cost effective alternative to expensive dental implants.^[1,2]

Indications for transplantation of teeth include-replacement of unrestorable tooth or lost tooth due to trauma, congenitally missing tooth, surgical repositioning of impacted tooth.^[1-3]

Important prognostic factors which influences the long-term fate of tooth grafts transplanted from one individual to another and genetically different individual

include age of transplantation, type of donor tooth, stage of eruption/developmental stage of graft, surgical technique.^[4,5]

Success rate varies widely with reported results from 0% to near 100%.^[4]

The treatment result in a patient in whom a Mesiodens^[6] from a donor was used to replace a lost maxillary central incisor is presented.

CASE REPORT

An 11-year-old male patient presented to the Department of Pedodontics with the chief complaint of inability to close the mouth. Patient gave a history of trauma (fall) 1 day ago.

Clinical examination of the oral tissues revealed lacerated lower lip, missing maxillary right central incisor, intruded maxillary right lateral incisor, mobile (Grade II) upper left central incisor, dento-alveolar fracture in relation to lower left central, lateral and lower right central incisors. Radiographic examination confirmed avulsed maxillary right central incisor, intruded maxillary right lateral incisor and lingual displacement of lower anterior segment [Figure 1].

General treatment plan: In view of the younger age of the patient and immature dentition a conservative treatment approach was undertaken which included surgical repositioning of maxillary right lateral incisor and reduction of lower fragment followed by stabilization

Access this article online	
Quick Response Code:	Website: www.ejgd.org
	DOI: 10.4103/2278-9626.112324

with wire composite splint. Three days later an allotransplantation of mesiodens extracted from a female patient was carried out to replace the lost maxillary right central incisor.

Procedure of allotransplantation

Extraction of a mesiodens of the female patient was scheduled such that it could be used as an allotransplant immediately to minimize the extraoral time for the extracted donor tooth. The donor was investigated for Hepatitis-B and HIV and she tested negative for all these. Initially the socket of the recipient was cleared of all debris and fresh bleeding was initiated and was prepared with minimal trauma. The orthodontic wire-composite splint which was put in place earlier was not disturbed [Figure 2]. Intentional root canal treatment was done on the mesiodens followed by extraction of tooth atraumatically. The tooth was held by crown structure, apicectomy done and apex sealed with glass ionomer cement. It was later stored in chilled 2% chlorhexidine solution diluted with saline (1:1) [Figure 3 and 4].

The donor tooth was then placed immediately in the socket. Bleeding was controlled and then the tooth was secured to the orthodontic wire-composite splint

which was already in place. All occlusal interference was relieved and an intra-oral periapical radiograph was made to check the position of the mesiodens in its new socket [Figures 5 and 6].

The patient was put on regular chlorhexidine mouth rinse and no systemic antibiotics/immune supplements were given. This was done with the sole intention of evaluation the body's response to an allograft. Proper oral hygiene instructions were given and recall checkup was done after 1 week, 15 days and every month thereafter. Splint was removed after 4 weeks once the tooth had stabilized. Radiograph at 6 month recall revealed good periapical and periodontal healing when a permanent restoration with porcelain fused to metal crown was fabricated and cemented [Figure 7]. Patient is still under follow-up.

DISCUSSION

Evaluation of the post-treatment records of allotransplanted tooth indicates an excellent healing and acceptance by the recipient. The patient is rehabilitated, smile and occlusion restored without compromising esthetics or any adjacent teeth. Intraoral radiograph revealed adequate alveolar bone level was maintained with normal periodontal ligament space.

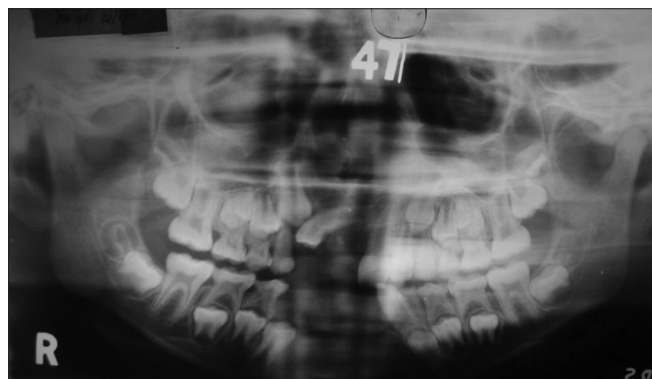


Figure 1: Pre-treatment radiograph

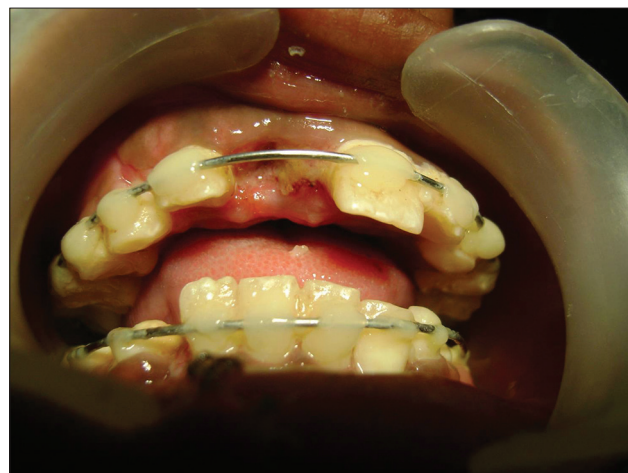

Figure 2: Treatment photograph-recipient- socket of missing central incisor

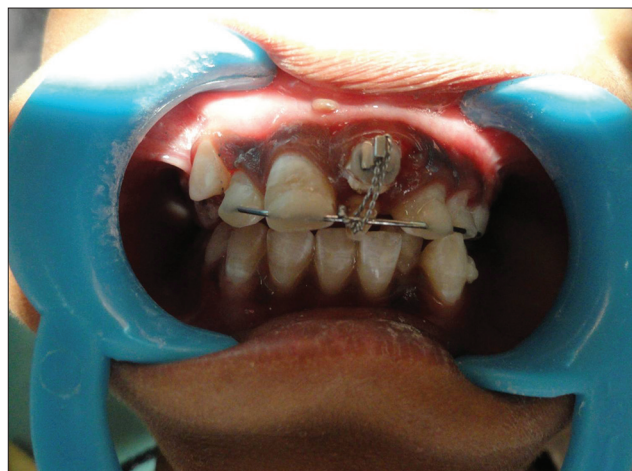

Figure 3: Treatment photograph-donor tooth




Figure 4: Extracted donor tooth

Studies have reported a poor prognosis for allotransplanted teeth when compared to auto-transplantation. The result shows two types of response, depending on the treatment used. A more prominent acute inflammatory response with stored teeth in the initial phase and a more prominent chronic inflammatory response with fresh teeth at about 18 days after transplantation.^[7-9]

The complication to be taken care of (immediate or delayed) includes pulp necrosis, progressive root resorption and ankylosis/infraocclusion, which jeopardize the long-term result of the allotransplant. The first complication is eliminated in the present case as root canal treatment was done for the donor tooth prior to its extraction. The other two are not seen as the follow-up radiograph shows normal periodontal ligament space. The reasons attributed can be because of the use of a small single rooted tooth compared to the large socket available so that enlarged socket will optimize periodontal and pulpal healing as the future graft will be surrounded by a 1-2 mm of coagulum (Andreasen)^[2] and the waiting period of 3 days so that good bone healing had started.

The prognosis appears to be good for the present patient as clinically the tooth is well stabilized, shows good gingival health and radiographically no signs of resorption or ankylosis are visible over the last 1 year [Figure 8]. Only regular follow-up will check the long-term result.

CONCLUSION

The consideration of tooth allotransplantation should not be neglected in treatment planning. Even should a graft fail in later life and be lost, the dentist has then a more mature dentition to deal with, and the patient would have experienced a growing period without the encumbrance of the removable prosthesis usually prescribed for an immature dentition.

Importance and significance

This case report showed:

- Allotransplantation of tooth is an acceptable procedure in younger children to restore function and esthetics
- Mesiodens could be successfully used as an allotransplant

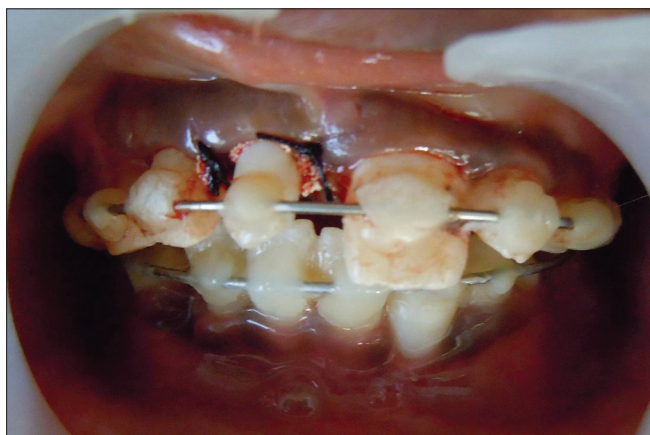


Figure 5: Post-treatment-intraoral photograph

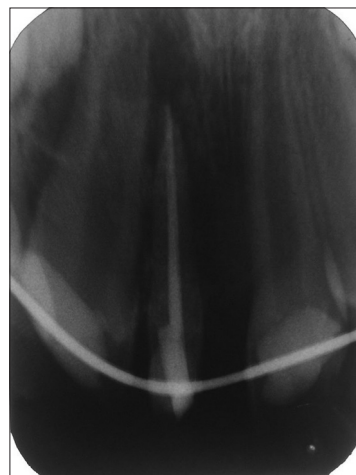

Figure 6: Post-treatment-intra oral peri apical radiograph

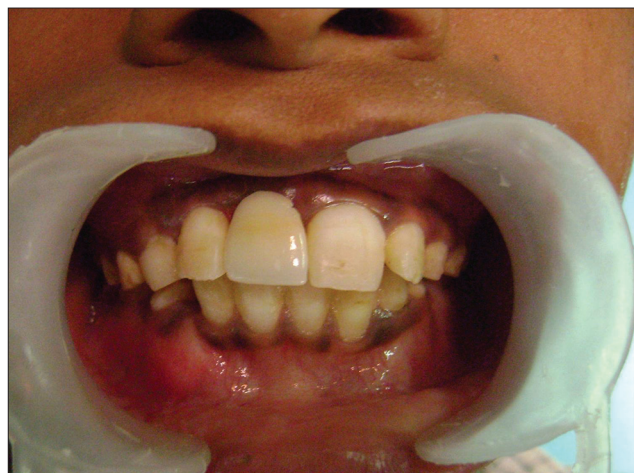

Figure 7: Permanent restoration

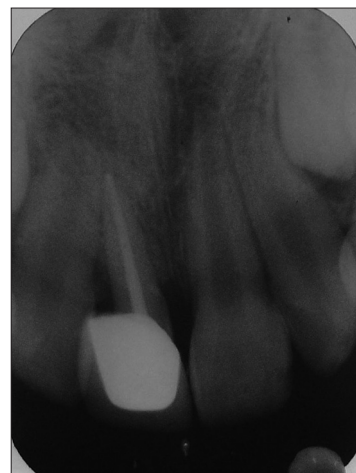

Figure 8: Follow-up radiograph

- Care must be taken to minimize the time between the extraction of the donor tooth and placement into its new socket. So the procedure must be planned to ensure availability of the donor and the recipient at the same time. In-out care this time was less than 10 min, which could probably explain the success of the procedure.

REFERENCES

1. Schuman NJ, Owens BM, Mincer HH. Dental transplants: Discussion and case report. *J Clin Pediatr Dent* 1997;21:281-5.
2. Andreasen JO and Andreasen FM. Autotransplantation of Teeth to the Anterior Region. *Textbook and Color Atlas of Traumatic Injuries to the Teeth*. 3rd ed. Munksgaard: Mosby publishing; 1994. p. 671-90.
3. Plainfield S. A viable alternative: Tooth transplantation. *J Prosthet Dent* 1983;50:667-71.
4. Schwartz O, Frederiksen K, Klausen B. Allotransplantation of human teeth. A retrospective study of 73 transplantations over a period of 28 years. *Int J Oral Maxillofac Surg* 1987;16:285-301.
5. Dr. Eddie CK YAU. Tooth autotransplantation as a treatment option. *Dent Bull* 2009;14:21-4.
6. Neville BW, Damm DD, Allen C, Bouquot JE. *Abnormalities of Teeth. Oral and Maxillofacial Pathology*. 3rd ed. Missouri: Saunders Elsevier publishing; 2009.p. 58.
7. Park JH, Tai K, Hayashi D. Tooth autotransplantation as a treatment option: A review. *J Clin Pediatr Dent* 2010;35:129-35.
8. Anneroth G, Lundquist G, Nordenram A, Söder PO. Re- and allotransplantation of teeth – An experimental study in monkeys. *Int J Oral Maxillofac Surg* 1988;17:54-7.
9. Shulman LB. Allogenic tooth transplantation. *J Oral Surg* 1972;30:395-409.

How to cite this article: Pai SM, Patil PS, Poornima P, Subbareddy VV. Mesiodens used for allotransplantation. *Eur J Gen Dent* 2013;2:178-81.

Source of Support: Nil, **Conflict of Interest:** None declared.

Announcement

Android App



Download
**Android
application**

FREE

A free application to browse and search the journal's content is now available for Android based mobiles and devices. The application provides "Table of Contents" of the latest issues, which are stored on the device for future offline browsing. Internet connection is required to access the back issues and search facility. The application is compatible with all the versions of Android. The application can be downloaded from <https://market.android.com/details?id=comm.app.medknow>. For suggestions and comments do write back to us.