

# Interdisciplinary approach to treating a patient with amelogenesis imperfecta: A clinical report

Mustafa Erhan Sari, Nursel Arici<sup>a</sup>, Bilal Ozmen

Departments of Pediatric Dentistry and <sup>1</sup>Orthodontics, Ondokuz Mayıs University, Faculty of Dentistry, Samsun, Turkey

Address for correspondence:

Dr. Mustafa Erhan Sari,  
Department of Pediatric Dentistry,  
Ondokuz Mayıs University, Faculty of  
Dentistry, 55139, Samsun, Turkey.  
E-mail: dterhansari@hotmail.com

## ABSTRACT

Amelogenesis imperfecta is a rare hereditary condition in which enamel structure without evidence of systemic disorders. Amelogenesis imperfecta is a disorder, requiring treatment due to esthetic, functional and related psychosocial problems. This article represents, a patient that referred to our clinic suffering from amelogenesis imperfect who successfully overcame the esthetic, functional and psychosocial problems by receiving multidisciplinary team rehabilitation.

## Key words

Amelogenesis imperfecta, composite restoration, restorative treatment

## INTRODUCTION

Amelogenesis imperfecta is a hereditary disorder that disturbs the developing enamel of the dental enamel structure. This anomaly affects both the primary and permanent dentitions resulting in poor development or complete absence of the enamel of the teeth.<sup>[1,2]</sup>

Amelogenesis imperfecta patients have similar oral complications. Amelogenesis imperfecta include quantitative and qualitative enamel deficiencies, dental sensitivity, unaesthetic appearance, reduced occlusal vertical dimension, multiple impacted teeth, congenitally missing teeth and root malformation.<sup>[3]</sup> The disorder may create unaesthetic appearance, dental sensitivity and attrition.<sup>[4]</sup> There are various classification systems for different amelogenesis imperfecta type. The most commonly used of these are hypocalcified, hypoplastic, or hypomature.<sup>[5]</sup> In the hypomaturation type, abnormalities in the maturation stage of enamel formation result in a mottled appearance, opaque white to yellow-brown or red-brown coloration, and enamel that is softer than normal that tends to chip from the underlying dentin.<sup>[6]</sup>

A variety of treatment methods, such as several case studies deal with the interdisciplinary treatment approaches, have been described to provide proper dental function and aesthetic for the patients suffer from amelogenesis imperfect.<sup>[2,3]</sup> The aim of this case report is to describe the functional and esthetic rehabilitation of a patient affected by amelogenesis imperfecta.

## CASE REPORT

The patient, a 12-year-old girl, she was unable to chew her food properly and also suffered from esthetic inadequacy and sensitivity of her teeth. The patient was examined dentally and medically; photographs and dental radiographs were obtained.

The enamel layer of all teeth was very thin and yellow-brown in color and cuspal structures were nearly flattened in posterior regions. Oral hygiene was not satisfactory. Gingival health of the patient was improved by periodontal therapy after three weeks.

The interdisciplinary treatment was applied because of the complex needs of the patient. A treatment plan was developed that would include treatments to both reduce the dental sensitivity and improve esthetics.

After oral hygiene improvement, a clinical examination was performed by the orthodontist. Clinical examination and analysis of the records showed that the upper jaw was narrow in the transversal direction, upper lateral teeth were in cross bite and over jet was decreased. In

### Access this article online

#### Quick Response Code:



Website:  
www.ejgd.org

DOI:  
10.4103/2278-9626.112323

the cephalometric analysis, upper and lower jaws were in normal position in the sagittal plane according to the base of the cranium, but the upper incisors were found to be slightly into retrusive position. In order to eliminate the narrow upper jaw and obtain a positive over jet, a removable expansion appliance with a three-way screw was planned [Figure 1a and 1b].

At the appliance adaptation appointment, she was instructed to turn the screw twice a week and wear the appliance all day. When the right and left upper lateral teeth came to the correct position in the arch, the orthodontic treatment was finished [Figure 2a].

Following orthodontic treatment the final stages of the treatment was performed by a pedodontist. A simulation of the treatment plan was performed with a diagnostic self-curing composite restorations made on the casts with a semi adjustable articulator in order to show a model of the final result to the patient and her parents.

The cervical enamel of the six anterior and posterior teeth was largely beveled; the discolored dentine was removed carefully. The occlusal contacts were determined by intercuspation position before cavity preparation. Teeth were conditioned and primed with a self-etching

adhesive (Clearfil SE Bond, Kuraray Medical, Tokyo, Japan) for 20 s.

The restorations were formed using a hybrid resin composite (Filtek Z-250, 3M/ESPE, St. Paul, MN, USA) which was placed using an incremental technique. The resin composite restorations were polymerized for at least 2 min with the polymerization unit (Free light II, 3M ESPE, Germany). The patient was finally furnished with a combination of direct composite resin restorations, the final result was esthetically pleasing [Figure 2b].

After restoration of teeth, the patient's dental sensitivity disappeared completely, and normal eating habits were established. The patient was recalled at 3-month intervals. On the control 1 year [Figure 3a and b] would be interesting to do improve better prophylaxis and the final result of clinical case.

## DISCUSSION

The unfavorable effects of amelogenesis imperfecta on aesthetic appearance, function, occlusion, phonation, and the health of the gingiva necessitate different approaches from traditional dental treatments.<sup>[7]</sup>

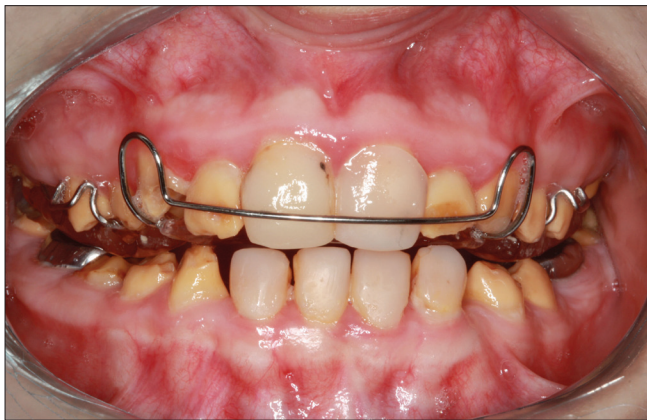

Figure 1a: Patient's intra-oral view with removable orthodontic appliance




Figure 1b: Removable orthodontic appliance

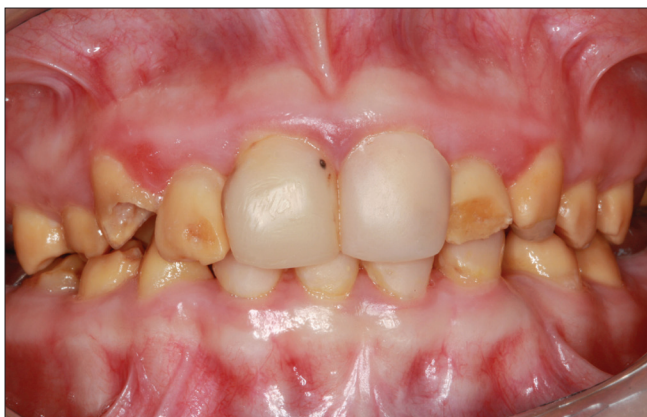

Figure 2a: Frontal view after finishing orthodontic treatment

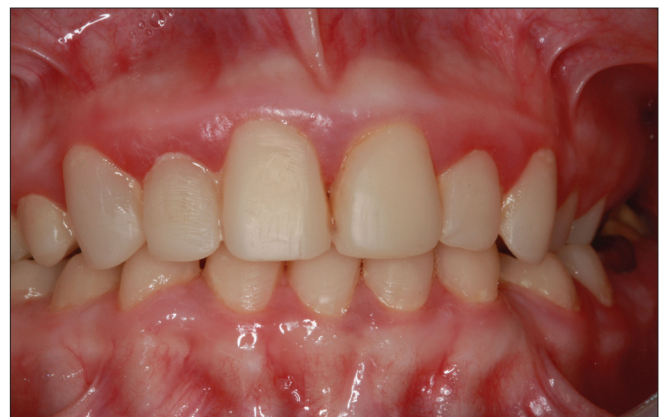

Figure 2b: Frontal view of final restorations

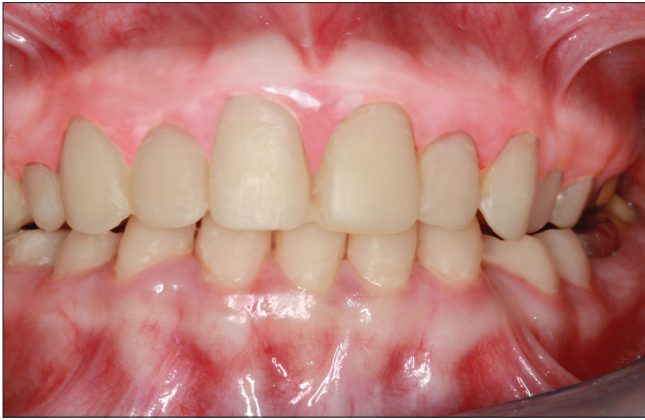

Figure 3a: Postoperative frontal view after one year

Full-mouth rehabilitation of an adult with amelogenesis imperfecta can be demanding. It requires better treatment planning and patient communication before commencing restorative treatment.

There are many alternatives for the treatment of teeth affected by amelogenesis imperfecta. However, the treatment planning for patients with amelogenesis imperfecta is related to many factors such as the age and socioeconomic status, the type, severity of the disorder, periodontal condition, and orthodontic need.<sup>[8]</sup>

While the priority of the patients was pain relief in the past, it has been replaced by aesthetic considerations. Material choice and appropriate restoration is important to mimic the natural teeth in dentistry.<sup>[9]</sup>

Nowadays, some clinicians are often applied the technique of covering the teeth with crowns. However, the large amounts of tooth preparation for this process may cause gingival problems and destruction of the surrounding tissue.<sup>[10]</sup>

Direct composite resin restorations minimal tooth tissue the removal of an aesthetic treatment provided in the clinic. Moreover, composite veneers have the advantage of being repaired by the addition of composite resin in the event of breakage.<sup>[11]</sup>

Because of the tremendous advances in the field of esthetic dentistry, especially in bonding to dentin, it is today possible to restore function and esthetics to an acceptable level.

This adhesive restorative procedure preserves tooth structure and is not very time consuming or costly to the patient.<sup>[1,9]</sup>

In spite of considering the indication of porcelain or composite laminate veneers at the aesthetic restoration of anterior teeth, the dentist should also consider the cost, retention and technical accuracy between the two options.<sup>[12]</sup>

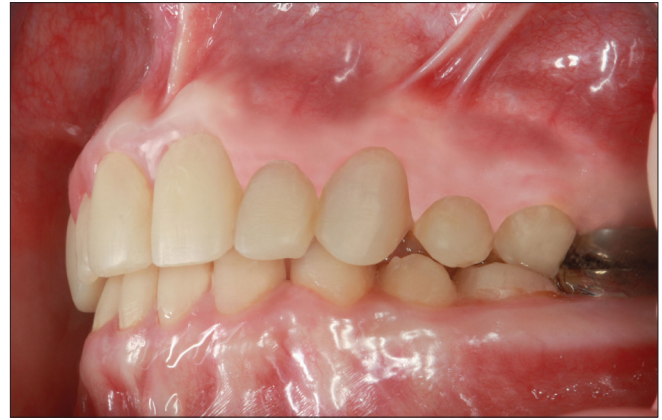

Figure 3b: Postoperative sagittal view after one year

In this case, two-years follow-up and evaluation of the clinical application of direct composite laminate veneer technique was reported.

## CONCLUSION

This clinical report described the functional and esthetic rehabilitation of a child female patient affected by amelogenesis imperfecta. For patient satisfaction, it is important to achieve a successful treatment outcome with multidisciplinary approaches, if the expectation and demands of the patients with amelogenesis imperfecta were considered at the beginning of therapy.

## REFERENCES

1. Aldred MJ, Savarirayan R, Crawford PJ. Amelogenesis imperfecta: A classification and catalogue for the 21<sup>st</sup> century. *Oral Dis* 2003;9:19-23.
2. Martelli-Junior H, dos Santos Neto PE, de Aquino SN, de Oliveira Santos CC, Borges SP, Oliveira EA, et al. Amelogenesis imperfecta and nephrocalcinosis syndrome: A case report and review of the literature. *Nephron Physiol* 2011;118:62-5.
3. Peters E, Cohen M, Altini M. Rough hypoplastic amelogenesis imperfecta with follicular hyperplasia. *Oral Surg Oral Med Oral Pathol* 1992;74:87-92.
4. Gadhia K, McDonald S, Arkutu N, Malik K. Amelogenesis imperfecta: An introduction. *Br Dent J.* 2012;212:377-9.
5. Nel JC, Pretorius JA, Weber A, Marais JT. Restoring function and esthetics in a patient with amelogenesis imperfecta. *Int J Periodontics Restorative Dent* 1997;17:478-83.
6. Akin H, Tasveren S, Yeler DY. Interdisciplinary approach to treating a patient with amelogenesis imperfecta: A clinical report. *J Esthet Restor Dent* 2007;19:131-5.
7. Ayna E, Çelenk S, Kadiroğlu ET. Restoring function and esthetics in 2 patients with amelogenesis imperfecta: Case report. *Quintessence Int* 2007;38:51-3.
8. Patel RR, Hovijitra S, Kafrawy AH, Bixler D. X-linked (recessive) hypomaturation amelogenesis imperfecta: A prosthodontic, genetic, and histopathologic report. *J Prosthet Dent* 1991;66:398-402.
9. Lee YK, Lim BS, Kim CW. Effect of surface conditions on the color of dental resin composites. *J Biomed Mater Res* 2002;63:657-63.
10. Aristidis GA. Etched porcelain veneer restoration of primary tooth: A clinical report. *J Prosthet Dent* 2000;83:504-7.



11. Robinson S, Nixon PJ, Gahan MJ, Chan MF. Techniques for restoring worn anterior teeth with direct composite resin. *Dent Update*. 2008;35:551-2, 555-8.
12. Garber DA. Direct composite veneers versus etched porcelain laminate veneers. *Dent Clin North Am* 1989;33:301-4.

**How to cite this article:** Sari ME, Arici N, Ozmen B. Interdisciplinary approach to treating a patient with amelogenesis imperfecta: A clinical report. *Eur J Gen Dent* 2013;2:174-7.

**Source of Support:** Nil, **Conflict of Interest:** None declared.

### "Quick Response Code" link for full text articles

The journal issue has a unique new feature for reaching to the journal's website without typing a single letter. Each article on its first page has a "Quick Response Code". Using any mobile or other hand-held device with camera and GPRS/other internet source, one can reach to the full text of that particular article on the journal's website. Start a QR-code reading software (see list of free applications from <http://tinyurl.com/yzh2tc>) and point the camera to the QR-code printed in the journal. It will automatically take you to the HTML full text of that article. One can also use a desktop or laptop with web camera for similar functionality. See <http://tinyurl.com/2bw7fn3> or <http://tinyurl.com/3ysr3me> for the free applications.