

Similar caries pattern in monozygotic twins: Role of nature and/or nurture

Anshula Deshpande, Neeraj Deshpande*

Departments of Pedodontics and *Periodontics, K.M. Shah Dental College, Sumandeep Vidyapeth, Vadodara, Gujarat, India

Address for correspondence:

Dr. Anshula Deshpande,
Department of Pedodontics,
K. M. Shah Dental College, Sumandeep
Vidyapeth, Vadodara – 391 760,
Gujarat, India.
E-mail: dranshula@rediffmail.com

ABSTRACT

The present article attempts to relook at the role of genetics in the caries pattern in pediatric patients. Genetics exerts a major influence on initiation and progression of caries. Several investigators have studied the genetic aspects in humans using both twin studies and family pedigree approaches. The recent advances in molecular biology and the outcomes of the Human Genome Project can help to have innovative approaches to understand the etiology of this complex disease. A pair of 5-year-old monozygotic twin brothers was referred by the Pediatrician for multiple caries. Both the brothers were reared apart but presented with similar dental caries traits. Comprehensive oral health care with a preventive and therapeutic procedure was provided. Periodic recall visits were scheduled after every 6 months. By studying dental diseases in the twins reared apart, the element of environmental influence is eliminated while retaining the advantage of similar genotype in monozygotic twins. This report of monozygotic twins imparts light on the significant contribution of genetic factors on caries susceptibility.

Key words

Dental caries, genetics, monozygous twins, reared apart

INTRODUCTION

Dental caries is a complex, multifactorial disease for which multiple host and environmental etiologic factors have been projected. Twin studies are used to estimate the influence of genetic factors on dental caries. This is a case report of 5-year-old identical twin brothers who were reared apart demonstrating a similar caries pattern. Review of the literature reveals that the genomic era has allowed us to learn about evolution, organization and rearrangements of genomes in health and disease, and the genetic influence can modify the expression of caries and has a heritable component in young children.

The role of twins in the analysis of human behavioral and physical development was first described by Galton.^[1] Genetic contribution to dental caries and

monozygous (MZ) twin pairs show smaller intrapair variances for caries than dizygous (DZ) pairs.^[2] Goodman *et al.*^[3] and Finn and Caldwell^[4] in their study of twins indicated toward the genetic component of dental caries. Bretz *et al.*^[5] suggested that variation in dental caries surface traits has a significant genetic contribution and microbial acid production is modulated by the environment in their study. Table 1 show several genetically variable factors associated with dental caries as studied by various researchers. Environmental contribution has been proposed by Liu.^[6]

Bertz *et al.* stated in their study that 70% of the variation in frequency and severity of dental caries could be explained by a genetic contribution to dental caries traits.^[5] Heredity plays a significant role in lesion progression and site-specific incidence rate.

Table 1: Studies showing genetic variables for dental caries

Salivary factors and oral flora	<ul style="list-style-type: none"> Goodman <i>et al.</i> 1959^[3] Mandel 1974^[37]
Tooth eruption	<ul style="list-style-type: none"> Finn and Caldwell 1963^[4]
Tooth morphology	<ul style="list-style-type: none"> Wood and Green 1969^[38] Townsend <i>et al.</i> 1988^[9]
Dental spacing and alignment	<ul style="list-style-type: none"> Corruccini and Potter 1980^[39]
Propensity for diet	<ul style="list-style-type: none"> Forrai and Bankovi 1984^[20]

Access this article online	
Quick Response Code:	Website: www.ejgd.org
	DOI: 10.4103/2278-9626.103397

CASE REPORT

Case 1

AM, a 5-year-old twin boy [Figures 1–4] was referred to a dental care center by the pediatrician for carious teeth. He was in a good general health; his medical history revealed an asthmatic bronchitis for which he was treated. He also underwent adenotonsillectomy.

Clinical examination revealed that AM was in deciduous dentition. Clinically detectable carious lesions were recorded using a mouth mirror, explorer and dental lighting and severity of the lesions was determined by measuring its extent as follows: 1 = white spot lesions; 2 = lesions confined to enamel with loss of intact surface; 3 = lesions where the dentin could be visualized at initial stages of breakdown; 4 = lesions >2–3 mm into dentin [Table 2]. Salivary pH was 5.2. Intraoral periapical radiograph was taken for teeth 75 and 85.

Treatment: All decayed teeth except 75, 85 were restored with composite. Pulpectomy was done in 75, 85, followed with stainless steel crown. Saliva pH was recorded after complete oral rehabilitation, which was 7.4. Follow-up was carried out after 6 months and 1 year [Figures 5 and 6].

Case 2

AN, a 5-year-old twin boy [Figures 7–9] was referred to a dental care center by the pediatrician for carious teeth. Like his brother, he was in good general health; his medical history revealed an asthmatic bronchitis for which he was treated. He also underwent adenotonsillectomy.

Clinical examination revealed that AN was also in deciduous dentition. Clinically detectable carious lesions were recorded using a mouth mirror, explorer and dental lighting and severity of lesions on each surface was determined by measuring its extent on the same scale as described in case 1 [Table 3]. Saliva pH was 5.4. There was periapical abscess in relation to 75. An intraoral periapical radiograph was taken for teeth 75 and 85.

Treatment: All decayed teeth except 75, 85 were restored with composite. Pulpectomy was done in 85 followed with stainless steel crown. Tooth 75 was extracted under block anesthesia followed by removable nonfunctional space maintainer. Saliva pH was recorded after complete oral rehabilitation, which was 7.4. Follow-up was carried out after 6 months and 1 year. After the eruption of 36, band and loop (fixed space maintainer) was cemented [Figures 10 and 11].

DISCUSSION

Twin studies are used to estimate the influence of genetic factors on dental caries. By studying the dental disease

of multifactorial origin in monozygotic twins reared apart, the problem of shared environmental influence is eliminated.^[7] This case of twins reared apart allows us to study their growth and development as non twins, while retaining the unique research advantages of controlling for genotype.^[8]

If hereditary factors are predominant, the caries patterns in identical twins are similar,^[4] which was found in the case presented here. In this case of monozygotic twins, the similar caries pattern affirms that, at the early age, the genetic contribution to caries susceptibility is significant and later environmental factors account for more of the variance in dental caries traits.^[5] Less intrapair difference in caries experience in MZ twins^[4] have been reported, and it is within the time frame that clinical phenotypic endpoints must be characterized.

In this report, the important features to note are: the surfaces involved are similar in the corresponding teeth and the extent and severity of the lesions are also identical. Townsend has shown that human crown morphology is under a degree of genetic control.^[9] Occlusal surface characteristics, lesion progression and site-specific

Table 2: Caries status for case 1

Teeth decayed (FDI)	Surface involved with severity of lesion				
	Occlusal /incisal	Buccal	Lingual	Mesial	Distal
55	2				
52				2	
51				3	
61				3	
62				2	
65	2				
75	4				
73		2			
83		2			
85	4				

Table 3: Caries status for case 2

Teeth decayed (FDI)	Surface involved with severity of lesion				
	Occlusal /incisal	Buccal	Lingual	Mesial	Distal
55	2				
52				2	
51				3	
61				3	
62				2	
65	2				
75	4				
73		2			
83		2			
85	4				

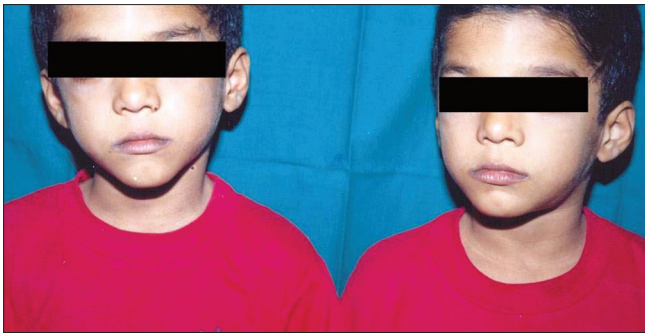

Figure 1: Extraoral photograph of monozygotic twins AM and AN

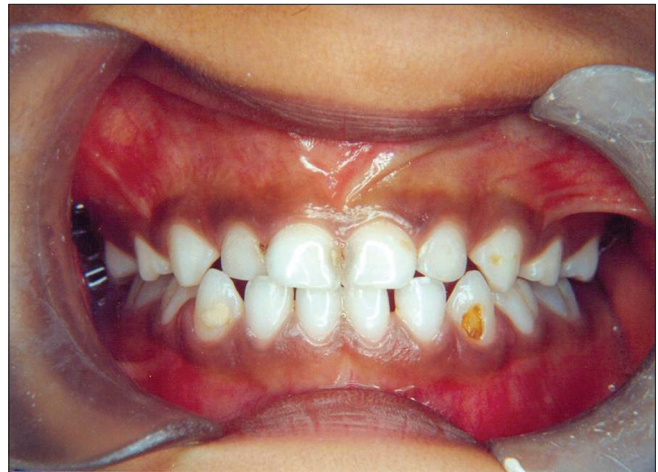

Figure 2: Intraoral photograph of AM – in occlusion

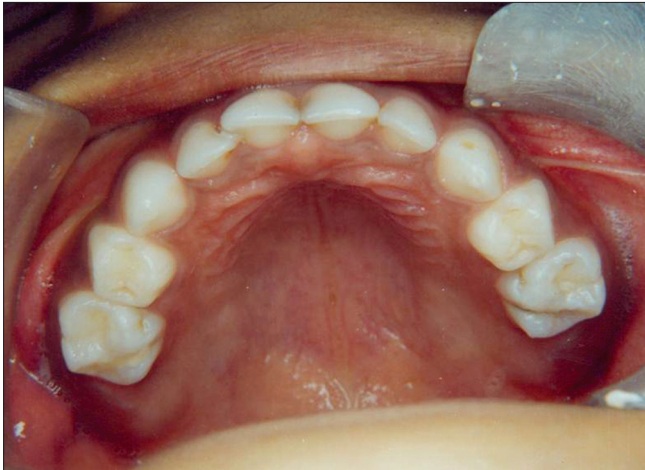


Figure 3: Intraoral photograph of AM – maxillary arch

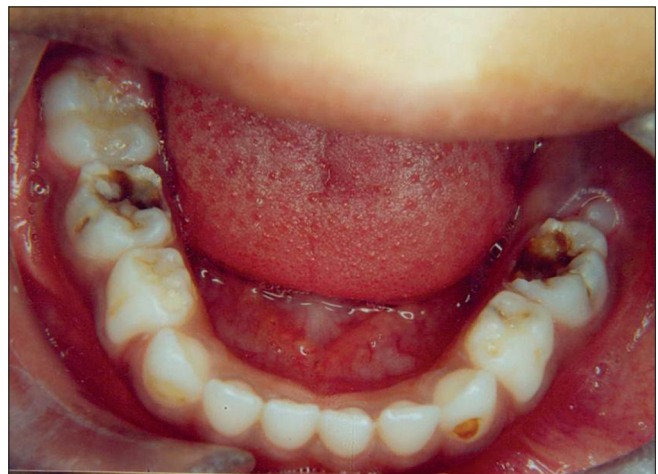


Figure 4: Intraoral photograph of AM – mandibular arch

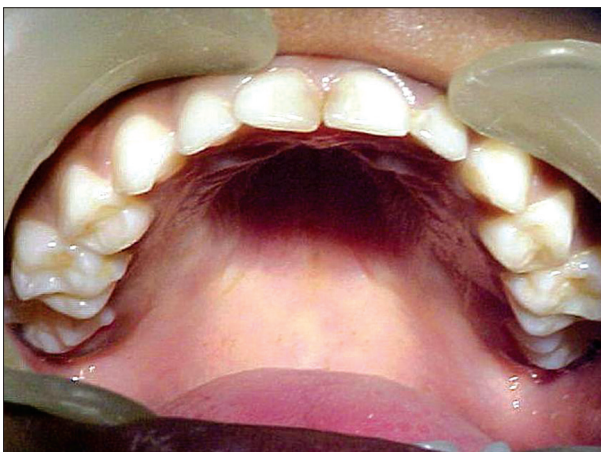

Figure 5: Intraoral photograph of AM – maxillary arch after 1-year follow-up

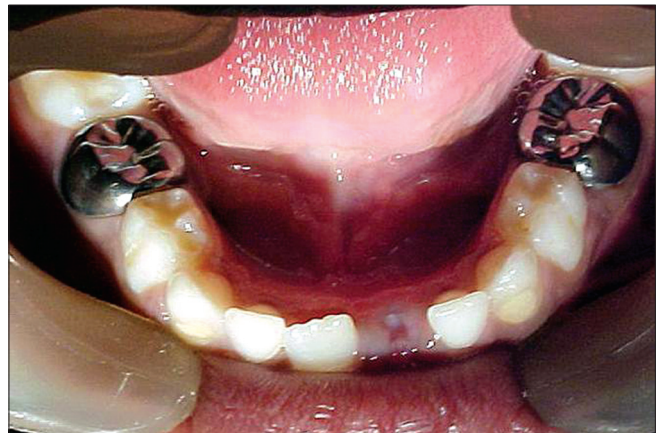


Figure 6: Intraoral photograph of AM – mandibular arch after 1-year follow-up

incidence rate are influenced by genotype,^[5] which is evident in the present case. The study by Conry *et al.*^[10] demonstrated a significant proportion of variance for the number of teeth and surfaces restored, and the caries present was attributable to genetic variance. The study carried out by Bretz *et al.*^[5] indicated that the highest incidence of dental caries occurs at an early age, and may correlate with eruption of primary dentition where occlusal surfaces presented with the highest net increment rates, followed by smooth and interproximal surfaces.

The lesion severity variance may be explained by genetic factors. The progression of dental caries involves both demineralization of dentin and degradation of the organic matrix.^[11] It has been well established that odontoblasts are capable of responding to dentin injury and can up regulate their secretory activity. Growth factors

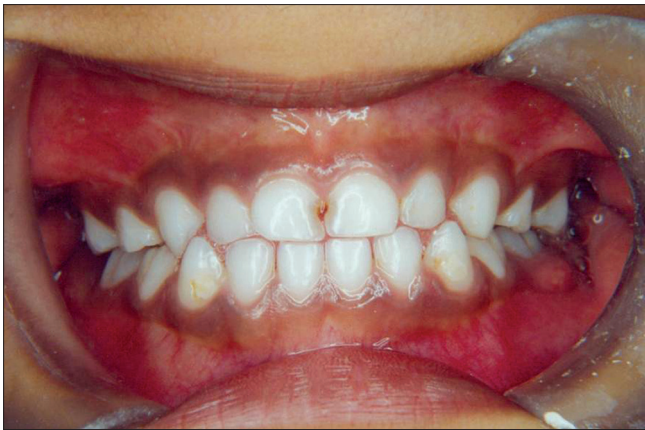

Figure 7: Intraoral photograph of AN – in occlusion

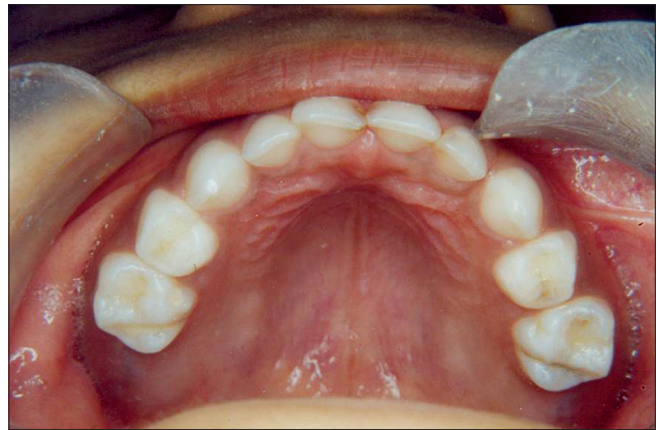

Figure 8: Intraoral photograph of AN – maxillary arch

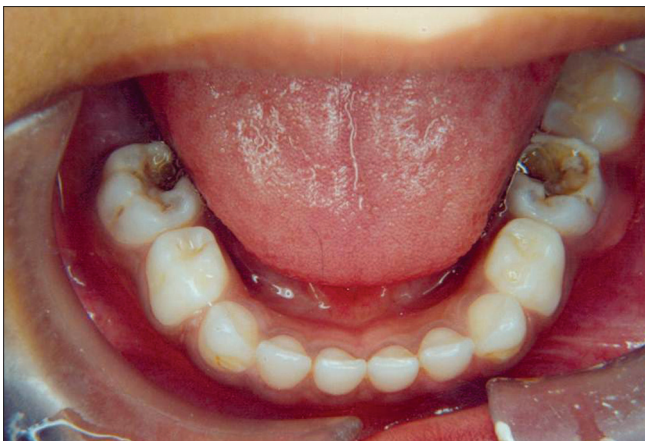

Figure 9: Intraoral photograph of AN – mandibular arch

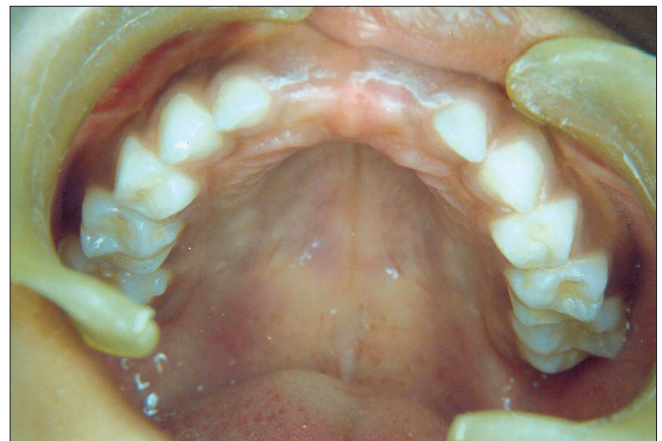


Figure 10: Intraoral photograph of AN – maxillary arch after 1-year follow-up

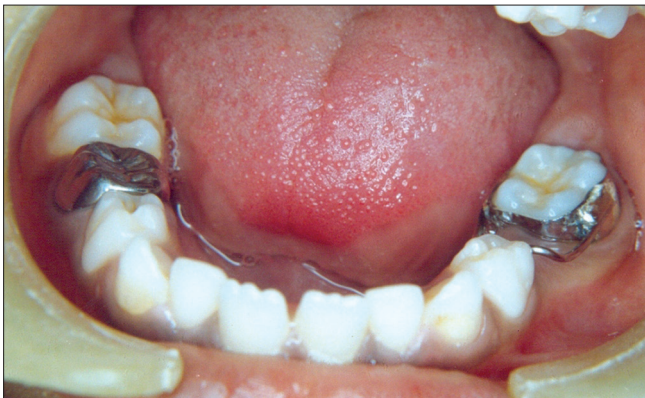

Figure 11: Intraoral photograph of AN – mandibular arch after 1-year follow up

sequestered within the dentin matrix may be released following tooth injury associated with caries, and may initiate or modulate reparative responses.^[12] Host MMP's may also be involved in caries progression, e.g. dentin-bound MMP20.^[13] The role of genetic susceptibility in dentinal degradation remains to be determined, but the twin studies with similar phenotype gives some amount of understanding for characteristics of tooth morphology and anatomy related to genotype.

The introduction of “positional cloning” improved the fidelity of the search for genetic causes of human diseases.^[14,15] Multiple gene mutations coupled to multiple environmental factors is termed “human complex diseases,” which include cleft lip and palate, dental caries, severe malocclusion, periodontal diseases and many more. These complex diseases or disorders have a genetic etiology but their inheritance is complex (non-Mendelian), such that multiple gene and gene-environment interactions develop the clinical phenotypes or traits.^[16-20]

CONCLUSION

Genetic influence can modify the expression of dental caries. There is a need for an increased appreciation regarding how genetic factors interact with environmental factors to influence growth and pathology, in understanding of pathogenesis and recognition of susceptible groups and individuals. The human genome era heralds a call to reform dental education. Clinicians should be aware of the genetic component and patient's family members may also be susceptible. Genetic linkage studies on well-defined populations are the necessary next step in analyzing the relationship

between inheritance and dental caries, which can relate to important clinical implications for the timing of dental caries intervention.

Clinical significance

- Well-designed twin studies have a central role to play in this new era
- Twin studies can throw new light on how genes influence developmental mechanisms and provide efficient ways in search of quantitative trait loci (QTL's)
- Challenge to translate the knowledge into improved preventive and treatment strategies for the community at large
- Teeth are not re-modelled and hence can be used to understand how developmental disturbances affect morphogenetic processes both pre- and post-natally
- Number of genes and the identification of the specific genes responsible for enamel alterations and occlusal characteristics
- Human genome sequence will provide new avenues for dental education.

REFERENCES

- Galton F. The history of twins as a criterion of the relative powers of nature and nurture, *Fraser's Magazine* 1875;12:566-76.
- Horowitz SL, Osborne RH, De George FV. Caries experience in twins. *Science* 1958;128:300-1.
- Goodman HO, Luke JE, Rosen S, Hackel E. Heritability in dental caries, certain oral microflora and salivary components. *Am J Hum Genet* 1959;11:263-73.
- Finn SB, Caldwell RC. Dental caries in twins-i. A comparison of the caries experience of monozygotic twins, dizygotic twins and unrelated children. *Arch Oral Biol* 1963;70:571-85.
- Bretz WA, Corby PM, Schork NJ, Robinson MT, Coelho M, Costa S, *et al.* Longitudinal analysis of heritability for dental caries traits. *J Dent Res* 2005;84:1047-51.
- Liu H, Deng H, Cao CF, Ono H. Genetic analysis of dental traits in 82 pairs of female-female twins. *Chin J Dent Res* 1998;1:12-6.
- Bouchard TJ. Whenever the twain shall meet. *The Sciences* 1997;37:52-7.
- Farber SL. Identical twins reared apart: A reanalysis, New York: Basic Books, Inc; 1981.
- Townsend GC, Richards LC, Brown T, Burgess VB. Twin zygosity determination on the basis of dental morphology. *J Forensic Odontostomatol* 1988;6:1-15.
- Conry JP, Messer LB, Boraas JC, Aeppli DP, Bouchard TJ Jr. Dental caries and treatment characteristics in human twins reared apart. *Arch Oral Biol* 1993;38:937-43.
- Clarkson BH, Feagin FF, McCurdy SP, Sheetz JH, Speirs R. Effects of phosphoprotein moieties on the remineralization of human root caries. *Caries Res* 1991;25:166-73.
- Smith AJ, Lesot H. Induction and regulation of crown dentinogenesis: Embryonic events as a template for dental tissue repair? *Crit Rev Oral Biol Med* 2001;12:425-37.
- Sulkala M, Wahlgren J, Larmas M, Sorsa T, Teronen O, Salo T, *et al.* The effects of MMP inhibitors on human salivary MMP activity and caries progression in rats. *J Dent Res* 2001;80:1545-9.
- Ballabio A. The rise and fall of positional cloning? *Nat Genet* 1993;3:277-9.
- Collins FS. Positional cloning moves from perdictional to traditional. *Nat Genet* 1995;9:347-50.
- Slavkin HC. The human genome, implications for oral health and diseases, and dental education. *J Dent Educ* 2001;65:463-79.
- Mandel ID. Relation of saliva and plaque to caries. *J Dent Res* 1974;53:246-66.
- Wood BF, Green LJ. Second premolar morphologic trait similarities in twins. *J Dent Res* 1969;48:74-8.
- Corruccini RS, Potter RH. Genetic analysis of occlusal variation in twins. *Am J Orthod*. 1980;78:140-54.
- Forrai G, Bánkóvi G. On the food favoritism of twins. *Acta Physiol Hung* 1984;64:25-32.

How to cite this article: Deshpande A, Deshpande N. Similar caries pattern in monozygotic twins: Role of nature and/or nurture. *Eur J Gen Dent* 2012;1:104-8.

Source of Support: Nil, **Conflict of Interest:** None declared.

"Quick Response Code" link for full text articles

The journal issue has a unique new feature for reaching to the journal's website without typing a single letter. Each article on its first page has a "Quick Response Code". Using any mobile or other hand-held device with camera and GPRS/other internet source, one can reach to the full text of that particular article on the journal's website. Start a QR-code reading software (see list of free applications from <http://tinyurl.com/yzh2tc>) and point the camera to the QR-code printed in the journal. It will automatically take you to the HTML full text of that article. One can also use a desktop or laptop with web camera for similar functionality. See <http://tinyurl.com/2bw7fn3> or <http://tinyurl.com/3ysr3me> for the free applications.