

## Forced eruption for all four maxillary incisors prior to implant rehabilitation

Gerson Luiz Ulema Ribeiro, José Vinicius Bolognesi Maciel<sup>1</sup>, Juliana da Silva Pereira<sup>2</sup>, Orlando Motohiro Tanaka<sup>3</sup>

Graduate Dentistry Program, Orthodontics, Federal University of Santa Catarina, Florianópolis, Brazil, Diplomate of Brazilian Board of Orthodontics and Dentofacial Orthopedics, <sup>1</sup>Federal University of Rio de Janeiro, Rio de Janeiro, Brazil, Professor, Residence in Orthodontics, PUCPR, <sup>2</sup>Dentistry Graduate Program – Orthodontics, Federal University of Santa Catarina, Florianópolis, Brazil, <sup>3</sup>Graduate Dentistry Program, Orthodontics, Pontifical Catholic University of Parana, Curitiba, Brazil, Diplomate of Brazilian Board of Orthodontics and Dentofacial Orthopedics, Postdoctoral Fellow at The Center for Advanced Dental Education at Saint Louis University, Bolsista da CAPES - Proc. No BEX 1632/11-6

**Address for correspondence:**  
Dr. Orlando Motohiro Tanaka,  
Graduate Dentistry Program -  
Orthodontics, R. Imaculada Conceição,  
Curitiba, Brazil.  
Email: tanakaom@gmail.com

### ABSTRACT

Periodontally compromised teeth are a common problem observed in adults, and the extraction is a viable solution in some of these situations. When prosthetic rehabilitation with implants take place after the extraction, orthodontic extrusion may convert the tooth indicated for extraction into a useful tooth. A 48-year-old woman's chief complaint was the esthetics of her maxillary incisors with advanced periodontal disease. The incisors were orthodontically erupted to augment the bone topography for implant recipient sites and prosthetic rehabilitation. Three implants were selected and inserted in a single surgical procedure without any complications. A 10 months follow-up showed that the implants were stable with the prosthetic crowns preserving the surrounding soft tissues, and improving overall aesthetics and function.

### Key words

Extrusion, implant, periodontally compromised, prosthesis

### INTRODUCTION

From time to time, the orthodontist must treat teeth severely affected by periodontal disease. Periodontally compromised teeth are a common problem observed in adults, and the extraction is a viable solution in some of these situations. When prosthetic rehabilitation with implants take place after the extraction, orthodontic extrusion or forced eruption, rather than a simple tooth extraction, may convert the indicated teeth for extraction into a useful teeth.

The orthodontic extrusion of non restorable teeth prior to implant placement appears to be a viable alternative to conventional surgical augmentative procedures in implant site development,<sup>[1]</sup> and orthodontic tooth

movement is known to increase connective tissue attachment and alveolar bone height.<sup>[2]</sup>

Numerous treatment alternatives have been described in the literature for the bone loss resulting from severe periodontitis, such as surgical debridement and osseous grafts. Orthodontic extrusion<sup>[3-6]</sup> is one such technique that can be employed both for restorative treatments and for treatments in which clinical crown lengthening or bone crest incrementing is needed. This procedure is also known as forced eruption, vertical extrusion, orthodontic eruption, and assisted eruption.<sup>[7]</sup> It is defined as a non-surgical procedure with orthodontic appliances to augment the bone topography and improving the implant site.

There is evidence that bone apposition in the alveolar crest could lengthen crest height during the spontaneous eruption of a tooth that had been removed from the occlusion.<sup>[8]</sup> Orthodontic extrusion places the defect above the crestal bone,<sup>[9]</sup> either the possibility of reducing both the depth of the pocket and the insertion gain,<sup>[10]</sup> or the development of the bone and gingiva in an incisal or occlusal direction to develop a potential implant site<sup>[11]</sup> A common discussion in the literature<sup>[3-5,11,12]</sup> involves

#### Access this article online

##### Quick Response Code:



**Website:**  
www.ejgd.org

**DOI:**  
10.4103/2278-9626.103396

the requirement for disease control before the beginning of orthodontic tooth movement. In absence of disease, tooth movement is accompanied by changes in the tooth attachment. However, in the presence of periodontitis, orthodontic movement causes a deepening of osseous defects.

The simultaneous use of orthodontic extrusion improves the three-dimensional topography of the recipient implant site before extraction.<sup>[5,12]</sup> The use of light and continuous force is recommended to obtain the best biological response, and forces between 20 and 25 cN per tooth are advisable.<sup>[5,7]</sup>

In this report, we describe effective orthodontic treatment in a case involving the extrusion of anterior teeth, vertical movement of the whole maxillary incisor, and an increase of the alveolar vertical dimension, followed by extraction prior to implant rehabilitation of the four maxillary incisors.

## CASE REPORT

A 48-year-old woman's chief complaint was the esthetics of her maxillary incisors. Clinical examination indicated advanced periodontal disease in all four maxillary incisors with a high degree of mobility [Figure 1].

The patient underwent complete periodontal therapy, including plaque control, root curettage, and root planning. After periodontal disease control was achieved, a non-torqued, non-angulated 3M-Unitek, Dyna Lock 0.022 × 0.028-in slot brackets were bonded. The alignment and leveling was performed with 0.012, 0.014, 0.016, and 0.018-in stainless steel arch wires. After leveling, the maxillary incisor step down bends using a 0.020-in stainless steel arch wire were placed distal to the lateral incisor brackets to perform the orthodontic extrusion. The degree of each step of activation was on the order of 0.5 mm was established to guarantee the delivery of light and continuous force to the periodontium and to perform a gentle orthodontic extrusion [Figure 2].

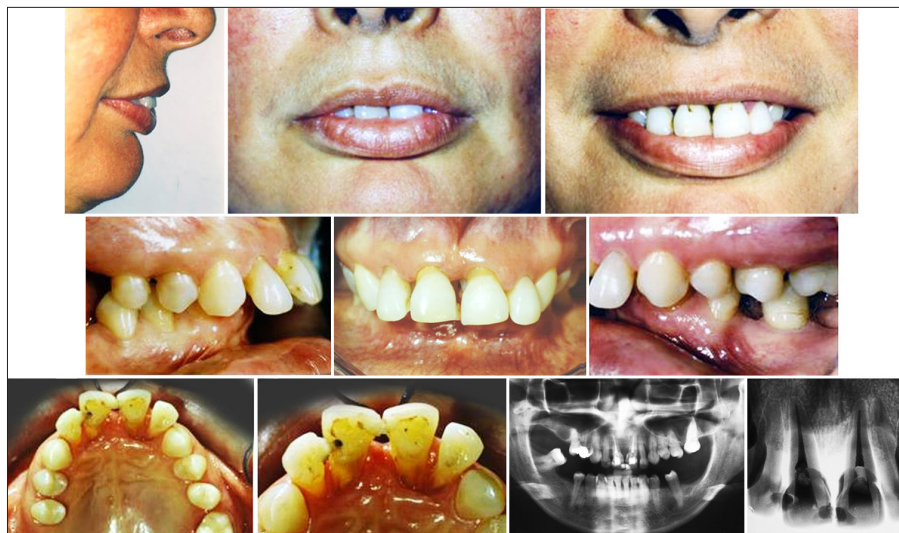

Figure 1: Pre-treatment photographs and radiographs

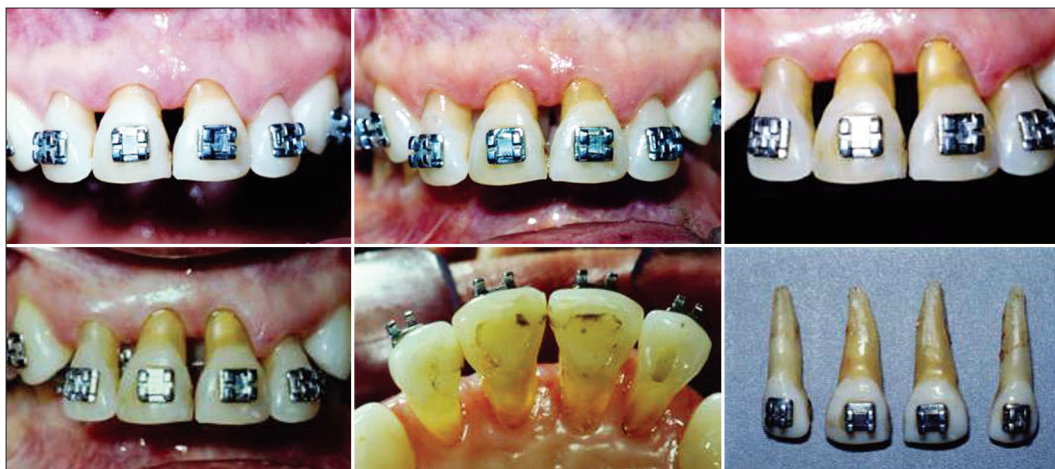

Figure 2: Extrusion with 0.020-in stainless steel arch wire and 0.5 mm step down between the lateral incisor and canine until final extraction

The activations took 4 weeks each, and the total time that elapsed until the completion of tooth extrusion was 9 months. From the beginning of the extrusion until completion, the teeth were not worn out. The result of this slow extrusion was a gain in vertical bone at the alveolar crest height that diminished the bone loss and created a good implant site [Figure 3].

For prosthetic rehabilitation, three implants were selected that were 3 and 4 mm in size. The three implants were inserted in a single surgical procedure without any complications. The healing time was 20 weeks. In a follow up examination 10 months after the treatment and installation of the implants, there was no evidence of any problems [Figure 4].

The three-dimensional morphology of the alveolar bone in potential implant sites is often less than ideal, especially in the anterior region, and the inadequate amount of cortical bone in the buccolingual dimension often

necessitates surgical or nonsurgical bone augmentation to ensure ideal implant positioning and adequate thread coverage.<sup>[13]</sup> Then a bone graft was placed in the upper right molar area to permit the future placement of an implant and prosthetic crowns. The patient underwent mandibular surgical advancement to correct maxillary and mandibular discrepancy and achieve a better aesthetic result [Figure 5].

## DISCUSSION

The implant site development with orthodontic reconstruction is always preferable to mechanical and surgical modifications as a means of achieving osseous modifications since these solutions do not pay sufficient heed to the biologic situation.<sup>[5]</sup>

Augmentative surgical procedures are often used to improve the hard and soft tissue profiles of implant

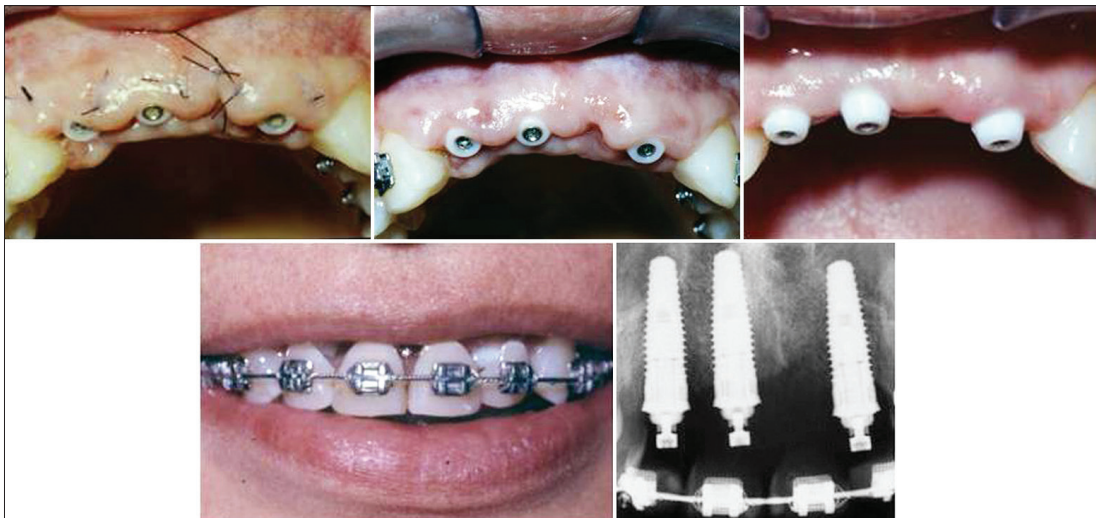

Figure 3: Implant placement and provisional anterior restoration

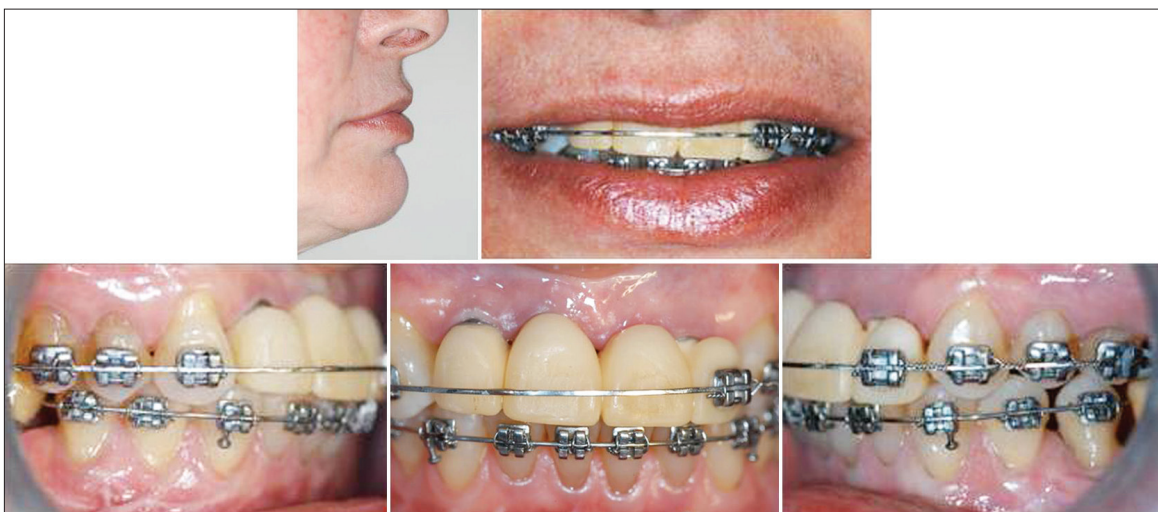

Figure 4: Finishing after mandibular surgical advancement

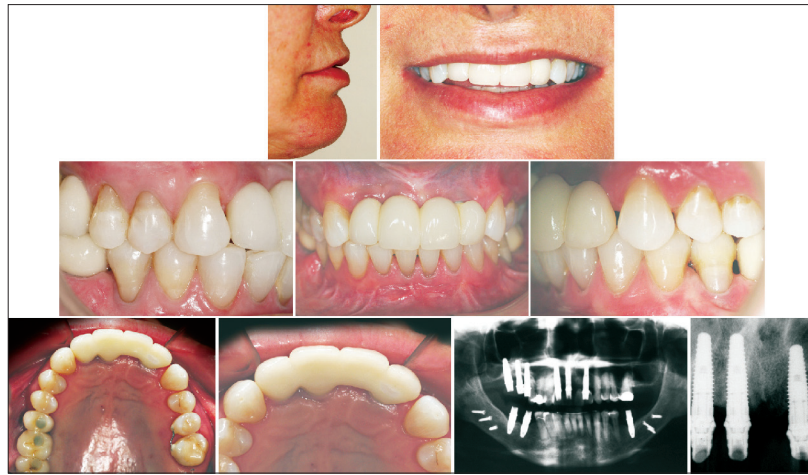

Figure 5: Post-treatment photograph and radiograph

recipient sites. Allogeneous grafting and autogenous bone grafting from intraoral or extra oral donor sites is currently the most widely used and best studied method of increasing the amount of alveolar bone available for primary implant anchorage, stability, and thread coverage.<sup>[1,13]</sup>

One might question whether the results observed here were somehow influenced by the periodontal therapy that the patient underwent. The answer is absolutely yes. It is not possible to increase bone without first eliminating the cause of the problem. However, it is also important to note that the periodontal therapy was performed in the absence of any osseous gain. The increase in alveolar crest height was achieved through slow orthodontic movement of the teeth, which was accompanied by the after the periodontal disease was controlled. In comparing the gingival level clinically and the bone level in radiographic image [Figures 1 and 5] the benefits for implant-prosthetic rehabilitation was clinically significant.

The most important aspect of the extrusion of severely fractured, carious, or diseased teeth is the possibility of increasing both bone tissue and bone quality, achieving restoration procedures much simpler. In some case upper central incisors are extracted, space closed followed by periodontal and cosmetic procedures of re-shaping of laterals.<sup>[14]</sup>

During orthodontic extrusion, bone formation occurs in the tension areas of the periodontum.<sup>[5]</sup> Ideally, there are no areas of compression during this particular type of tooth movement because the tooth is being pulled out of its socket, and all of the fibers are stretched equally. In this clinical case, some periodontal preparation before treatment as supracrestal fiberotomy might be cogitated, but only the maintenance of periodontal health throughout all phases of mechanotherapy was considered.

When restoring the esthetics of the maxillary central teeth, the preservation or reconstruction of the interdental papillary area is an important issue. Employing orthodontic extrusion makes it possible to enhance the quality and quantity of the papilla. When a tooth with a negative osseous profile moves out of the socket, the interproximal bone is manipulated coronally. Thus, there is an increase in bone crest height that will stimulate and support a corresponding soft tissue.

The clinical crown heights of the maxillary anterior teeth can be intentionally modified during orthodontic treatment to produce a more esthetic result, and the success of the results depended upon coordination of care between the orthodontist and the restorative dentist are vitally important.<sup>[15]</sup>

The orthodontic extrusion of non restorable teeth prior to implant placement appears to be a viable alternative to conventional surgical augmentative procedures in implant site development,<sup>[1,13]</sup> as in the clinical case presented in this article, even teeth extrusion might be effective to improve one- and two-wall wide isolated vertical infrabony defects.<sup>[13]</sup>

## CONCLUSION

Orthodontic extrusion or forced eruption was used to extrude all four maxillary incisors to augment the bone topography for prosthetic rehabilitation with three implants in a single surgical procedure preserving the surrounding soft tissues, and improving overall aesthetics and function.

## REFERENCES

1. Korayem M, Flores-Mir C, Nassar U, Olfert K. Implant site development by orthodontic extrusion. A systematic review. *Angle Orthod* 2008;78:752-60.
2. Bondemark L. Interdental bone changes after orthodontic treatment: A 5-year longitudinal study. *Am J Orthod Dentofacial Orthop*

- 1998;114:25-31.
3. Ingber JS. Forced eruption. Part I. A method of treating isolated one and two wall infrabony osseous defects-rationale and case report. *J Periodontol* 1974;45:199-206.
  4. Ingber JS. Forced eruption: Part II. A method of treating nonrestorable teeth-Periodontal and restorative considerations. *J Periodontol* 1976;47:203-16.
  5. Mantzikos T, Shamus I. Forced eruption and implant site development: An osteophysiologic response. *Am J Orthod Dentofacial Orthop* 1999;115:583-91.
  6. Kim SH, Tramontina VA, Papalexiou V, Luczyszyn SM, Grassi MB, de Fatima Scarpim M, *et al.* Rapid orthodontic extrusion using an interocclusal appliance for the reestablishment of biologic width: A case report. *Quintessence Int* 2011;42:201-4.
  7. Potashnick SR, Rosenberg ES. Forced eruption: Principles in periodontics and restorative dentistry. *J Prosthet Dent* 1982;48:14-18.
  8. Oppenheim A. Artificial elongation of teeth. *Am J Orthod Oral Surg* 1940;26:931-40
  9. Heithersay GS. Combined endodontic-orthodontic treatment of transverse root fractures in the region of the alveolar crest. *Oral Surg Oral Med Oral Pathol* 1973;36:404-15.
  10. Brown IS. The effect of orthodontic therapy on certain types of periodontal defects. I. Clinical findings. *J Periodontol* 1973;44:742-56.
  11. Salama H, Salama M. The role of orthodontic extrusive remodeling in the enhancement of soft and hard tissue profiles prior to implant placement: A systematic approach to the management of extraction site defects. *Int J Periodontics Restorative Dent* 1993;13:312-33.
  12. Mantzikos T, Shamus I. Case report: Forced eruption and implant site development. *Angle Orthod* 1998;68:179-86.
  13. Iino S, Taira K, Machigashira M, Miyawaki S. Isolated vertical infrabony defects treated by orthodontic tooth extrusion. *Angle Orthod* 2008;78:728-36.
  14. Vassao SJ, Cavina DA, Kreia TB, Cerci BB, Maciel JV, Tanaka OM. Space closure after extraction of two central upper incisors and re-shaping of laterals. *Dent Traumatol* 2009;25:532-4.
  15. Kokich VG, Nappen DL, Shapiro PA. Gingival contour and clinical crown length: Their effect on the esthetic appearance of maxillary anterior teeth. *Am J Orthod* 1984;86:89-94.

**How to cite this article:** Ribeiro GL, Maciel JV, Pereira Jd, Tanaka OM. Forced eruption for all four maxillary incisors prior to implant rehabilitation. *Eur J Gen Dent* 2012;1:99-103.

**Source of Support:** Nil, **Conflict of Interest:** None declared.

## New features on the journal's website

### Optimized content for mobile and hand-held devices

HTML pages have been optimized of mobile and other hand-held devices (such as iPad, Kindle, iPod) for faster browsing speed.

Click on **[Mobile Full text]** from Table of Contents page.

This is simple HTML version for faster download on mobiles (if viewed on desktop, it will be automatically redirected to full HTML version)

### E-Pub for hand-held devices

EPUB is an open e-book standard recommended by The International Digital Publishing Forum which is designed for reflowable content i.e. the text display can be optimized for a particular display device.


Click on **[EPub]** from Table of Contents page.

There are various e-Pub readers such as for Windows: Digital Editions, OS X: Calibre/Bookworm, iPhone/iPod Touch/iPad: Stanza, and Linux: Calibre/Bookworm.

### E-Book for desktop

One can also see the entire issue as printed here in a 'flip book' version on desktops.

Links are available from Current Issue as well as Archives pages.

Click on  View as eBook