

Surgical management of bronchopulmonary carcinoids: A single center experience

Ashish Jakhetiya¹, Pankaj Kumar Garg^{1,2}, Rambha Pandey³, Palaniappan Ramanathan¹, Sunil Kumar¹, Debojit Nath⁴, Durgatosh Pandey¹

Abstract

Introduction: Bronchopulmonary carcinoids are uncommon tumors with relatively indolent biological behavior but a distinct malignant potential. Surgery is the mainstay of treatment. Our aim was to study preoperative characteristics, surgical approaches, and outcome in patients with bronchopulmonary carcinoid tumors. **Patients and Methods:** This retrospective study was done in the Department of Surgical Oncology of a Tertiary Teaching Hospital of North India. The case records of all the patients who underwent surgical treatment for lung neoplasms and were diagnosed to have bronchopulmonary carcinoids were reviewed. Details concerning the clinical presentation, preoperative therapy, operative procedure, postoperative complications, and outcome were retrieved from the case records. **Results:** Sixteen patients who underwent surgical treatment were found to have bronchopulmonary carcinoids on histopathological examination. The median age of the patients was 34 years (range 18–62 years). There were 11 men and five women. All patients were symptomatic, and the median duration of symptoms was 12 months (range 6–72 months) before presentation. Six patients had received antitubercular treatment before presentation, and one patient had been treated with chemotherapy due to misdiagnosis. Surgical procedures included six pneumonectomies (one with carinoplasty), four bilobectomies, three lobectomies, and three bronchoplastic procedures (two with lobectomy and one with bilobectomy). There was no postoperative mortality; three patients had morbidity in the form of lobar collapse, prolonged pleural collection, and surgical site infection. With a median follow-up time of 11 months (range 2–85 months), all the 16 patients are alive and disease-free. **Conclusions:** Delayed presentation and misdiagnosis of bronchial carcinoid are major concerns in North India. Adequate surgical resection can be performed without undue morbidity and is associated with good long-term results.

Key words: Bronchial neoplasms, carcinoid tumor, lung neoplasms, surgery

Introduction

Neuroendocrine tumors (NETs) of lung comprise a heterogeneous population of tumors from well-differentiated bronchial NETs to highly malignant small cell lung carcinoma. Well-differentiated NETs derived from pulmonary neuroendocrine cells are known as bronchopulmonary carcinoid.^[1] These tumors are classified into typical and atypical carcinoids on the basis of a number of mitotic figures and presence of necrosis.^[2,3] Improved detection methods and diagnostic protocols have probably led to the increased incidence of bronchopulmonary carcinoids in recent years.^[4] Although carcinoid tumors account for a very small population of pulmonary neoplasm (1–2%), they merit special consideration because of their excellent prognosis following optimal surgical management.^[4,5] Lung preserving surgery is the treatment of choice for both types of carcinoid.^[6] Typical carcinoid exhibits good prognosis, whereas atypical has comparatively aggressive behavior and poor prognosis.^[7] We present our experience of the management of bronchopulmonary carcinoids at a Tertiary Cancer Centre of North India.

Patients and Methods

We analyzed a prospectively lung cancer database at our tertiary care cancer center. Out of 110 patients who underwent surgery for primary lung malignancy from December 2006 and August 2014, 16 were bronchopulmonary carcinoids. Preoperative evaluation included chest roentgenogram (chest X-ray), contrast-enhanced computed tomography (CECT) of the chest, bronchoscopy, and pulmonary function test. Tissue diagnosis was established with bronchoscopy guided biopsy in central tumors and CT guided biopsy in peripheral

tumors. Pathological confirmation was based on routine light microscopy and immunohistochemical staining for chromogranin and synaptophysin, WHO criteria 2004 was used to classify typical and atypical carcinoid.^[2,3] Tumors were staged according to 2007 American Joint Committee on Cancer/Union for International Cancer Control TNM classification.^[8] Bronchoscopic debulking was reserved for inoperable patients or for preoperative optimization before surgery. All patients underwent on-table bronchoscopy before thoracotomy to map the tumor accurately. Muscle sparing open thoracotomy was the preferred approach. Anatomical lung resection with preservation of functional lung parenchyma was the standard approach whenever feasible, and pneumonectomy was reserved for situations such as involvement of main bronchus, when preservation was not possible due to significant extraluminal hilar component or irreversibly damaged lung parenchyma. Adjuvant cisplatin and etoposide-based chemotherapy were considered for atypical carcinoid stage II or above and adjuvant radiotherapy was reserved for the situation of residual disease (R1/R2 resection). After completion of treatment, all the patients were followed up in clinic every 3 months for the first 2 years, and every 6 months thereafter. At every follow-up visit, patients underwent detailed clinical examination and chest X-ray; any suspicious finding led to estimation of serum chromogranin A levels, CECT evaluation of chest, and bronchoscopic examination. Age, gender, preoperative symptoms and duration, relationship with smoking and tuberculosis, tumor location, preoperative diagnosis, staging, surgical procedure, complications, histology, and outcome were analyzed. Statistical analysis was performed

This is an open access article distributed under the terms of the Creative Commons Attribution-NonCommercial-ShareAlike 3.0 License, which allows others to remix, tweak, and build upon the work non-commercially, as long as the author is credited and the new creations are licensed under the identical terms.

For reprints contact: reprints@medknow.com

How to cite this article: Jakhetiya A, Garg PK, Pandey R, Ramanathan P, Kumar S, Nath D, *et al.* Surgical management of bronchopulmonary carcinoids: A single center experience Letter to the Editor. *South Asian J Cancer* 2017;6:6–10.

Access this article online

Quick Response Code:



Website: www.sajc.org

DOI: 10.4103/2278-330X.202568

Departments of ¹Surgical Oncology and ³Radiation Oncology, Dr. B.R.A. Institute Rotary Cancer Hospital, All India Institute of Medical Sciences, ²Department of Surgery, University College of Medical Sciences and Guru Teg Bahadur Hospital, University of Delhi, ⁴Department of Pathology, All India Institute of Medical Sciences, New Delhi, India

Correspondence to: Dr. Durgatosh Pandey, E-mail: durgatosh@gmail.com

using Statistical Package for Social Sciences (SPSS) software (version 16, SPSS, Inc, Chicago, IL, USA).

Results

Out of 110 patients of primary lung malignancy treated surgically between December 2006 and August 2014, 16 had bronchopulmonary carcinoids. The median age of the patients was 32 years (range 18–62 years). There were 11 men and five women. Only one patient was a smoker with 40 pack-years of cigarette smoking. Median duration of symptoms before presentation was 12 months (range 6–72 months). Initial clinical presentation was cough in 14, hemoptysis in 12, dyspnea on exertion in five, recurrent pneumonia in two, chest pain in two, and empyema in one patient. None of the patient presented with carcinoid syndrome. Six patients were previously treated with antitubercular drugs empirically at other centers. One patient was misdiagnosed as small cell carcinoma and had received six cycles of chemotherapy (cisplatin and etoposide) before presenting to our center. Bronchoscopy showed smooth intraluminal polypoidal growth in 14 patients; the growth was located in main stem bronchus in eight and in lobar bronchus in another six patients. Preoperative histopathological diagnosis was confirmed by bronchoscopy guided biopsy in 11, image-guided biopsy in two, and bronchoalveolar lavage (BAL) in one patient; two patients underwent definitive surgical procedure based on clinical and bronchoscopy finding as repeated biopsies failed to provide a definitive histopathological diagnosis. Figure 1 displays the CT findings of two patients.

All the patients were subjected to surgery after adequate preoperative optimization. Muscle sparing lateral thoracotomy was the preferred surgical approach. Surgical procedures included six pneumonectomies, four bilobectomies, three lobectomies, and three bronchoplastic procedures (two with lobectomy and one with bilobectomy). One of the patients who had involvement of the carina underwent pneumonectomy with carinoplasty. Median tumor size was 35 mm (range 6–90 mm). Median number of lymph nodes harvested was 3 (range 0–12); however, none of them showed metastatic deposit. There was no postoperative mortality. One patient had middle lobe collapse which was resolved after bronchoscopic suctioning, one patient had surgical site infection, and one had prolonged postoperative pleural collection which was managed conservatively. Median postoperative hospital stay was 8 days (range 5–11 days).

According to TNM classification (approved for the bronchopulmonary carcinoids by the International Association

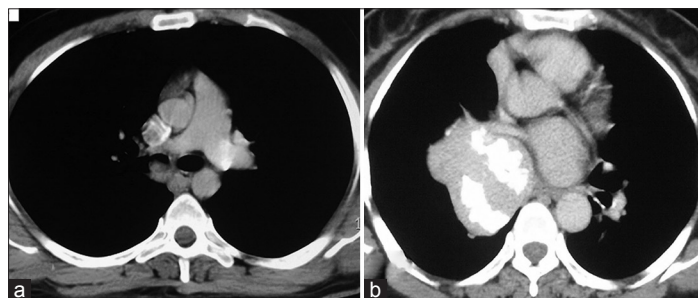


Figure 1: Axial section of contrast enhanced computed tomography chest displays. (a) Intrabronchial mass in right main bronchus. (b) Large mass in right hilar location with chunky calcification (extrabronchial component) and small intrabronchial component into right main bronchus

for the Study of Lung Cancer), disease stage distribution was stage IA in six, IB in two, IIB in seven and IIIA in one patient. One patient of stage IIB atypical carcinoid received six cycles of carboplatin and etoposide-based adjuvant chemotherapy while no adjuvant treatment given to typical carcinoid patients. With a median follow-up time of 11 months (range 2–85 months), all the 16 patients are alive and disease-free. Table 1 displays the demographic details, bronchoscopic findings, surgical procedures undertaken, histopathological findings, disease staging details and outcome. Figure 2 displays the histopathological features seen in our series of patients.

Discussion

Akin to previous studies,^[1,9] our study also indicates that smoking is unlikely to be related to bronchopulmonary carcinoids, only one patient in our study cohort was a chronic smoker. Cough, hemoptysis, and pneumonia are the classical triad of presentation.^[1] The diagnosis of a bronchial carcinoid is often delayed, and patients may receive several courses of antibiotics before diagnosis.^[1] In our study, median duration of symptoms before presentation was 12 months (range 6–72 months) with cough and hemoptysis as common modes of presentation (87% and 75%, respectively). In the present study cohort, six patients were empirically treated for tuberculosis at other centers before coming to our institution. No association between tuberculosis and bronchopulmonary carcinoid has been reported so far. In five patients out of the six who had received antituberculosis treatment, there was no evidence of active or healed tuberculosis on final histology; however, in one case necrotizing epithelioid granulomas and microabscesses were present in the resected specimen. In spite of many overlapping features between tuberculosis and carcinoid, the index of suspicion should be high whenever an empiric diagnosis of tuberculosis has been made, and bronchoscopy should be used early in such cases. Carcinoid syndrome is rare at presentation; none of our patients presented with carcinoid syndrome. Fink *et al.* observed carcinoid syndrome only in one of 142 cases of pulmonary carcinoid tumors.^[9]

WHO classification of bronchopulmonary NETs distinguishes four subtypes: Low-grade typical carcinoid, intermediate-grade atypical carcinoid, and two high-grade malignancies, large cell neuroendocrine carcinoma, and small cell lung cancer.^[2,3] The WHO diagnostic criteria for typical carcinoid are a tumor with carcinoid morphology, <2 mitoses/10 high power field and no necrosis. An atypical carcinoid is defined as a tumor with carcinoid morphology with 2–10 mitoses/10 high power field and/or necrosis.^[3] Although most carcinoids can be identified on routine light microscopy, immunopositivity for neuroendocrine markers (chromogranin A, synaptophysin, and CD56) and cytokeratin provides confirmatory evidence for the diagnosis. Of late, Ki-67 (MIB-1) is also emerging as a useful tool in diagnosis, particularly in small biopsy and cytology specimen.^[10] Typical carcinoid represents 80–90% of carcinoids, with the highest incidence in the fifth and sixth decades of life and in children typical carcinoids are the most common lung tumors.^[9] In our study, 14 out of 16 were typical carcinoid. For diagnostic confirmation biopsy is necessary and once diagnosis is confirmed more specific radiological and serological evaluations may be employed.^[1]

Table 1: Patient's demographic details, bronchoscopic findings, surgical procedure, tumor node metastasis stage, and follow-up

Number	Age (years)	Gender	Duration (months)	Previous treatment**	Bronchoscopic location of tumor***	Surgical procedure	Size (mm)	Pathologic stage	Follow-up (months)
1	49	Male	12	ATT	RMB	Right pneumonectomy	25	T3N0M0	85
2	49	Male	24	Chemotherapy	Not visible	Right upper lobectomy	30	T1bN0M0	46
3	62	Male	12	None	Not visible	Left lower lobectomy	30	T1bN0M0	44
4	18	Male	48	Bronchoscopic debulking	RMB	Right upper lobectomy + wedge bronchoplasty	15	T3N0M0	23
5	36	Female	24	No	RMB	Right pneumonectomy	50	T3N0M0	23
6	27	Male	12	No	RIB	Right bilobectomy	44	T2aN0M0	23
7	44	Male	60	ATT	LMB	Left pneumonectomy	40	T3N0M0	12
8	32	Male	48	ATT	RIB	Right bilobectomy	20	T1aN0M0	11
9	48	Female	72	ATT	RMB	Right pneumonectomy	80	T3N0M0	11
10	18	Female	48	ATT	RMB	Right pneumonectomy	90	T3N0M0	11
11	28	Male	12	ATT	RMB	Right pneumonectomy + carinoplasty	60	T4N0M0	8
12	25	Male	12	No	RMLB	Right bilobectomy + wedge bronchoplasty	40	T2aN0M0	7
13	55	Female	6	No	RIB	Right bilobectomy	15	T1aN0M0	7
14	29	Male	6	No	RIB	Right bilobectomy	6	T1aN0M0	5
15	51	Male	6	No	RMLB	Right middle lobectomy	40	T3N0M0	5
16	21	Female	12	No	RLLB	Right lower lobectomy + wedge bronchoplasty	25	T1bN0M0	2

ATT=Anti-tuberculosis treatment, *RMB=Right main bronchus, RIB=Right intermediate bronchus, RMLB=Right middle lobe bronchus, LMB=Left main bronchus, RLLB=Right lower lobe bronchus

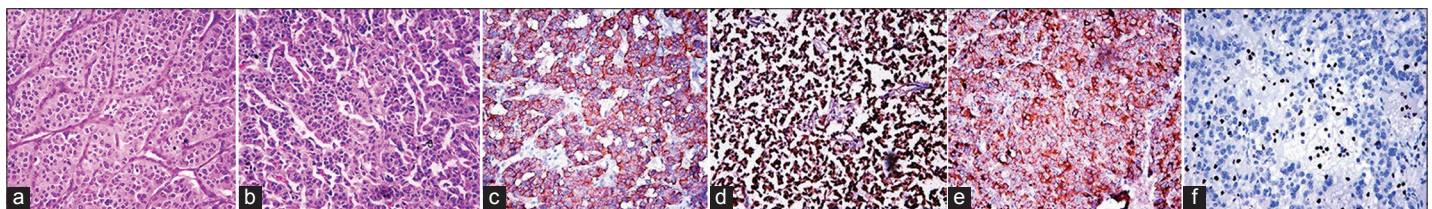


Figure 2: (a) Typical carcinoid: Tumor cells are arranged in an organoid nesting and trabecular pattern, with a fine vascular stroma. Mitosis index <2/10 high power field (x20, H, and E). (b) Atypical carcinoid: Tumor cells are arranged in organoid pattern with moderate eosinophilic cytoplasm and finely granular nuclear chromatin. Mitotic index approximately 3/10 high power field (x20, H, and E). (c-e) Tumor cells are diffusely immunopositive for chromogranin, synaptophysin, and pancytokeratin, respectively (x40). (f) MIB-1 labeling index approximately 3% (x40)

Carcinoid appears as isolated hilar or parahilar mass on chest radiograph. Plain X-rays are nonspecific and once suspicious lesion is detected CECT of chest and upper abdomen should be done to determine size, location, extent of primary tumor, mediastinal nodal status, and distant metastasis. On CT, carcinoid appears as well-defined, ovoid mass that narrow, deform or obstruct airways.^[1] Bronchoscopy remains gold standard for central carcinoid as it helps in early diagnosis for central tumor as well as helps in precise tumor localization before surgery.^[6] Diagnosis was suspected on bronchoscopy in 14 patients, eight had tumors in main stem bronchus, and six in lobar bronchus. In two patients, bronchoscopy was unremarkable; tissue diagnosis was established by CT-guided biopsy of the mass in the lung. Carcinoid tumors have a predilection for the major bronchi and are more common in main stem bronchi than lobar bronchi.^[11] On bronchoscopy carcinoid appears as pink to red polypoidal mass with smooth surface.^[1] The overlying intact mucosa prevents cells from exfoliation so yield of sputum cytology and BAL is very low.^[12] Only one patient in our series showed positive cytology on BAL, and diagnosis was made by bronchoscopic biopsy in other 11 patients. After flexible bronchoscopy with biopsy, bleeding was a major concern in past; however, now, various studies have shown that the incidence of serious bleeding complications during bronchoscopic biopsy is very low. In a study by Cardillo *et al.*, 89 patients underwent bronchoscopic

biopsy, and no significant bleeding occurred.^[13] Though two patients in the present series had significant bleeding following attempted bronchoscopic biopsy, it was successfully managed with bronchoscopic instillation of cold saline and diluted epinephrine; however, these two patients underwent definitive surgery without tissue diagnosis. On-table bronchoscopy should be performed just prior to/or during surgery to ensure margin-free resection.

Due to poor metabolism of carcinoids, fluorodeoxyglucose positron emission tomography (PET)/CT scan has low sensitivity.^[1,14] As 80% of typical carcinoids express somatostatin receptors, somatostatin receptor scintigraphy, and now 68 gallium-DOTATOC (1,4,7,10-tetraazacyclododecane-NI, NII, NIII, NIII-tetraacetic acid (D)-Phe1-thy3-octreotide) PET/CT have shown promising results and should be used more often particularly to plan targeted radionucleotide therapies and identify distant metastasis.^[1,14] For detection of bronchopulmonary carcinoid, Ga-68 DOTATOC PET/CT has shown sensitivity, specificity, and accuracy of 96%, 100%, and 96%, respectively.^[14] However functional imaging is not routinely practiced in our institute at present due to cost issues, and reliable diagnosis can be made with combination of bronchoscopy, CT scan, and biopsy. Various serum markers have been proposed for diagnosis but except chromogranin A none have showed significance. Though Chromogranin A is not a good marker for diagnosis, it has prognostic significance as it correlates with tumor burden.

Moreover, rising levels of chromogranin during follow-up may indicate disease recurrence.^[1,15]

Surgery is the mainstay for curative treatment of bronchopulmonary carcinoids. Bronchoscopic treatment alone appears suboptimal and should be reserved for inoperable patients or performed as preoperative debulking procedure before surgery.^[6,16,17] One patient in our series had bronchoscopic debulking before definitive surgery. This patient had a polypoidal tumor arising from the right upper lobe bronchus, extending to the right main bronchus and across the carina into the lower trachea. Following bronchoscopic snaring of the polypoidal component of the tumor, the true extent of the tumor could be accurately defined, pneumonia resolved, and he underwent right upper lobectomy with wedge bronchoplasty.^[18] Anatomical lung resection with preservation of functional lung parenchyma (lobectomy or sleeve resection/bronchoplastic procedure) is the treatment of choice, and every effort should be made to preserve functional lung.^[13,16] Pneumonectomy should be avoided whenever possible; however, it may be necessary in cases where the distal lung parenchyma is destroyed due to long-standing obstruction.^[17] Most of our patients presented very late with completely destroyed lung parenchyma and central lesions with a significant extraluminal component which was evident on chest CT. This probably explains high frequency of pneumonectomies (6 out of 16 patients) in our series. Some authors have shown possibility of multicentric carcinoid and tumorlet and supported that major pulmonary resections are inevitable.^[15] In our study, tumorlet was found in one patient, but none had multicentric disease.

Incidence of lymph nodal metastasis is reported to be 15–20% in typical and 40–50% in atypical carcinoid. Systematic mediastinal nodal dissection or sampling should be integral part of the surgery.^[6,13,16] We have followed a policy of mediastinal lymph node dissection selectively for atypical carcinoid, or when there was significant mediastinal lymphadenopathy on CT chest or on intraoperative exploration; in other cases, mediastinal sampling was performed. Median number of lymph nodes removed was 3 (range 0–12), however, none showed tumor deposit. R0 resection was achieved in all patients, no patient had positive margin on the final histopathology. The role of adjuvant treatment after complete resection is not clear, and North American Neuroendocrine Tumor society guidelines do not recommend adjuvant treatment after complete surgical resection.^[19] In contrast, the National Comprehensive Cancer Network suggests adjuvant chemotherapy with or without radiotherapy for resected stage II or III atypical carcinoids.^[20] One of our patients who had atypical carcinoid had adjuvant chemotherapy. Typical carcinoid exhibits good prognosis with 5 years survival of 87–90%, whereas atypical carcinoid has aggressive behavior and poor prognosis with 5 years survival of 44–78%.^[7] With a median follow-up of 11 months (range 2–85 months), all patients in the present series were alive and free of disease.

While the need for complete surgical resection is undoubted, the real surgical challenge is achieving an R0 resection with preservation of lung parenchyma. The fact that majority of these tumors are central makes it even more difficult to avoid pneumonectomy in such cases, especially when associated with long-standing collapse/consolidation of otherwise uninvolved

lung. Integration of bronchoscopic debulking before definitive surgery, and a greater application of bronchoplastic procedures would potentially improve the chances of lung preservation.

Conclusions

Bronchopulmonary carcinoids are low-grade tumors with benign characteristics; however, they do have malignant potential. Delayed presentation and misdiagnosis are major concerns in our scenario because of overlapping symptoms with tuberculosis and lung cancer; this increases the likelihood of patients receiving inappropriate treatment before being correctly diagnosed with carcinoid tumor. While complete and aggressive anatomical surgical resection is the key to good long-term outcome, all attempts should be made to preserve lung parenchyma and avoid pneumonectomy wherever feasible.

Financial support and sponsorship

Nil.

Conflicts of interest

There are no conflicts of interest.

References

- Gustafsson BI, Kidd M, Chan A, Malfertheiner MV, Modlin IM. Bronchopulmonary neuroendocrine tumors. *Cancer* 2008;113:5-21.
- Fink G, Krelbaum T, Yellin A, Bendayan D, Saute M, Glazer M, *et al.* Pulmonary carcinoid: Presentation, diagnosis, and outcome in 142 cases in Israel and review of 640 cases from the literature. *Chest* 2001;119:1647-51.
- Travis WD, Giroux DJ, Chansky K, Crowley J, Asamura H, Brambilla E, *et al.* The IASLC lung cancer staging project: Proposals for the inclusion of broncho-pulmonary carcinoid tumors in the forthcoming (seventh) edition of the TNM classification for lung cancer. *J Thorac Oncol* 2008;3:1213-23.
- Yao JC, Hassan M, Phan A, Dagohoy C, Leary C, Mares JE, *et al.* One hundred years after "carcinoid": Epidemiology of and prognostic factors for neuroendocrine tumors in 35,825 cases in the United States. *J Clin Oncol* 2008;26:3063-72.
- Skuladottir H, Hirsch FR, Hansen HH, Olsen JH. Pulmonary neuroendocrine tumors: Incidence and prognosis of histological subtypes. A population-based study in Denmark. *Lung Cancer* 2002;37:127-35.
- Öberg K, Hellman P, Ferolla P, Papotti M; ESMO Guidelines Working Group. Neuroendocrine bronchial and thymic tumors: ESMO clinical practice guidelines for diagnosis, treatment and follow-up. *Ann Oncol* 2012;23 Suppl 7:vii120-3.
- Travis WD, Rush W, Flieder DB, Falk R, Fleming MV, Gal AA, *et al.* Survival analysis of 200 pulmonary neuroendocrine tumors with clarification of criteria for atypical carcinoid and its separation from typical carcinoid. *Am J Surg Pathol* 1998;22:934-44.
- Edge S, Byrd DR, Compton CC, Fritz AG, Greene FL, Trotti A. American Joint Committee on Cancer Staging Manual. 7th ed. New York: Springer; 2010. p. 253.
- Fink G, Krelbaum T, Yellin A, Bendayan D, Saute M, Glazer M, *et al.* Pulmonary carcinoid: Presentation, diagnosis, and outcome in 142 cases in Israel and review of 640 cases from the literature. *Chest* 2001;119:1647-51.
- Rekhtman N. Neuroendocrine tumors of the lung: An update. *Arch Pathol Lab Med* 2010;134:1628-38.
- Thomas R, Christopher DJ, Balamugesh T, Shah A. Clinico-pathologic study of pulmonary carcinoid tumours - A retrospective analysis and review of literature. *Respir Med* 2008;102:1611-4.
- Aron M, Kapila K, Verma K. Carcinoid tumors of the lung: A diagnostic challenge in bronchial washings. *Diagn Cytopathol* 2004;30:62-6.
- Cardillo G, Sera F, Di Martino M, Graziano P, Giunti R, Carbone L, *et al.* Bronchial carcinoid tumors: Nodal status and long-term survival after resection. *Ann Thorac Surg* 2004;77:1781-5.
- Venkitaraman B, Karunanithi S, Kumar A, Khilnani GC, Kumar R. Role of 68Ga-DOTATOC PET/CT in initial evaluation of patients with suspected bronchopulmonary carcinoid. *Eur J Nucl Med Mol Imaging* 2014;41:856-64.
- Ferolla P, Daddi N, Urbani M, Semeraro A, Ribacchi R, Giovenali P,

- et al.* Tumorlets, multicentric carcinoids, lymph-nodal metastases, and long-term behavior in bronchial carcinoids. *J Thorac Oncol* 2009;4:383-7.
16. Daddi N, Ferolla P, Urbani M, Semeraro A, Avenia N, Ribacchi R, *et al.* Surgical treatment of neuroendocrine tumors of the lung. *Eur J Cardiothorac Surg* 2004;26:813-7.
 17. El Jamal M, Nicholson AG, Goldstraw P. The feasibility of conservative resection for carcinoid tumours: Is pneumonectomy ever necessary for uncomplicated cases? *Eur J Cardiothorac Surg* 2000;18:301-6.
 18. Pandey D, Ramanathan P, Khurse BB, Bharati SJ, Mishra S. Bronchoscopic debulking followed by bronchoplastic procedure helps in limiting lung resection in a bronchial carcinoid: A case report. *Indian J Surg Oncol* 2014;5:214-6.
 19. Phan AT, Oberg K, Choi J, Harrison LH Jr., Hassan MM, Strosberg JR, *et al.* NANETS consensus guideline for the diagnosis and management of neuroendocrine tumors: Well-differentiated neuroendocrine tumors of the thorax (includes lung and thymus). *Pancreas* 2010;39:784-98.
 20. National Comprehensive Cancer Network (NCCN). Clinical Practice Guidelines in Oncology. Available from: http://www.nccn.org/professionals/physician_gls/f_guidelines.asp. [Last accessed on 2014 Mar 10].