

Letter to the Editor

Billiary obstruction in a metastatic tumor of the pancreas from breast cancer

DOI: 10.4103/2278-330X.202567

Dear Editor,

Primary pancreatic-malignancies are far more common than pancreatic secondaries, which constitute <10% of all pancreatic-malignancies.^[1,2] The most common mode of metastatic spread to pancreas is direct invasion from cancers of neighboring organs, followed by lymphatic and hemato-geneous dissemination as in renal-cell and lung-carcinoma.^[3,4]

Breast cancer is the most common cancer in women and the third leading cause of malignancy related death in women.^[2] The mortality in breast cancer is mainly from the distant visceral metastasis. The most common metastasis occurs in liver, lung, bone and brain; atypical organ metastasis like isolated pancreatic-metastases is extremely rare.^[2,3]

We report a rare case of pancreatic-metastasis from invasive-ductal-carcinoma (IDC) breast. To the best of our knowledge, there have been only few cases of pancreatic-metastasis from carcinoma breast reported in the literature so far.^[2-6]

A 30-year-old lady, presented with obstructive-jaundice in April 2011. She was a known case of right-sided locally-advanced-breast-cancer, diagnosed in July 2008. She received 3 cycles of neoadjuvant-chemotherapy consists of cyclophosphamide, adriamycin, 5 flourouracil chemotherapy regimen and then underwent modified radical mastectomy.

Histopathological evaluation revealed pT3, N2, IDC III, hormone-receptor-positive with allred-score (estrogen receptor [ER] 8+, progesterone receptor [PR] 3+), while Her2neu negative disease. After surgery, she underwent adjuvant treatment with 4 cycles of paclitaxel chemotherapy regimen, followed by locoregional-radiotherapy (total-dose 45 Gy) to chest wall. She completed her adjuvant-treatment by March 2009; since then started on hormone-therapy (tamoxifen) and was kept under regular follow-up.

She was asymptomatic and her disease was under control until April 2011 when she developed nausea, vomiting and rapidly progressive jaundice. On investigating, the serum(S) bilirubin levels were 34 mg/dl with predominant direct-bilirubinemia, S transaminases (serum glutamic oxaloacetic transaminase/serum glutamic pyruvic transaminase) levels were 238/100 units/liter and S alkaline phosphatase was 1440 units/l. Contrast-enhanced computed tomography (CECT) scan demonstrated an irregular hypodense mass located at the head of the pancreas with dilatation of the common-bile-duct and intrahepatic-bile-ducts;

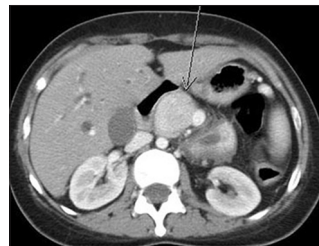

Figure 1: Prechemotherapy contrast-enhanced computed tomography scan showing, enhancing mass in the head of pancreas causing dilatation of the pancreatic duct, Common bile duct and the intra hepatic biliary tree

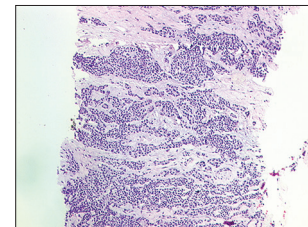


Figure 2: Metastatic carcinoma in pancreas with estrogen receptor positive tumor cells showing nuclear staining

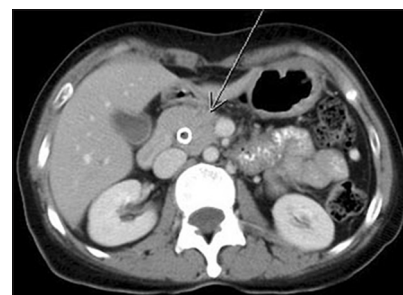


Figure 3: Post chemotherapy contrast-enhanced computed tomography scan shows complete regression of the mass with biliary stent *in situ*

no metastatic lesion was detected in the liver or anywhere else in the abdomen [Figure 1]. There were few subcentrimetric metastatic-nodules detected in the right lower-lobe and subpleural region with bronchiectatic-changes and collapse of left-lung. CA19.9 levels were within normal range.

Image-guided pancreatic-mass biopsy was carried out and histopathological assessment of the specimen revealed metastatic-adenocarcinoma cells. Further, allred-score demonstrated strong positivity for hormone-receptors however HER2neu was negative. The morphological and immunohistochemical features of pancreatic-metastasis were similar to the primary carcinoma breast [Figure 2]. The pancreatic tumor was therefore confirmed as having metastasized from breast primary. She underwent percutaneous transhepatic biliary drainage and fluoroscopic guided stenting with a metallic-stent (ELLA stent). The liver-functions normalized gradually and patient's general-condition also improved. She was started on palliative-intent chemotherapy; for the initial two cycles she was treated with single-agent carboplatin in view of poor-performance-status and deranged liver function. However, further four cycles were administered with a combination regimen of paclitaxel and carboplatin following which she is under regular follow-up. On abdominal imaging by CECT pancreatic

(Continue on page 14...)

(Letter to the editor continue from page 10...)

mass had completely regressed, and there is no evidence of ductal dilatation; CECT thorax showed some few small nodular lesions as in prior imaging [Figure 3]. She is planned for bilateral-oophorectomy, followed by aromatase-inhibitor-therapy after attaining menopausal-hormone-levels. After that she was kept under follow-up.

The vast majority of pancreatic carcinomas are primary, and among these, more than 90% are of ductal origin. However, a variety of extrapancreatic tumors may involve the pancreas secondarily and may manifest different clinicopathological-characteristics and outcomes. Renal cancer and lung cancer are the most common origin of metastasis to pancreas, followed by gastrointestinal carcinomas, lymphomas, thyroid, breast, skin, endometrium, and ovaries.^[1-3] Breast cancer accounts for 5–13% cases of all pancreatic-metastases.^[3,4] The pancreatic-metastases does not manifest clinically, and

hence most of the reported-cases are from incidentally-detected finding from autopsy-series.^[2,5]

Unlike other metastatic solid tumors that have a dismal prognosis, metastatic breast cancer (MBC) patients have relatively longer survival.^[1,3] The median survival in MBC has improved with modern chemotherapy consisting taxanes and anthracyclines.^[4,7] Therefore, except in the diffuse liver metastasis where in life expectancy is very low, aggressive palliative treatments should be considered to improve the quality of life and at times survival.

The present breast-cancer case presented with obstructive-jaundice due to pancreatic metastasis during follow-up after 2-year of disease-free-interval. Her jaundice improved after performing the biliary drainage procedure. Choledochoduodenostomy,^[2] pancreatoduodenostomy,^[8] pancreaticoduodenectomy^[9] and expanding metallic stent^[4] can palliate symptoms and are found very useful in these patients.^[4]

(Continue on page 19...)

(Letter to the editor continue from page 14...)

However, surgical procedures demands expertise and there are significant morbidity and mortality risk; hence, these should be reserved for the very selective group of cases wherein metastatic processes is confined to the pancreas and amenable to surgical resection without significant morbidity.^[1,10]

To differentiate between pancreatic primary versus secondary is a difficult task and even so when it is from an uncommon primary site. In the present case, on extensive analysis of morphology and immunohistochemistry, which showed that pancreatic-metastases was found similar to the primary breast-cancer and it expressed strong hormonal-receptor-positivity (ER and PR). The pancreatic tumor was, therefore, confirmed as having metastasized from the primary breast-cancer.

Earlier studies showed that the prognosis of patients with metastatic disease to the pancreas is usually better than that for primary pancreatic carcinoma.^[6] Although surgery is considered, a first-choice treatment in selected patients with pancreatic metastases but it is associated with significant morbidity.^[11] Moreover, the option for resection should mainly be reserved for the case of metastatic processes limited to the pancreas and amenable to surgical resection.

We conclude by stating that, when a pancreatic lesion develops in a patient with prior neoplasm, the possibility of a solitary metastasis to the pancreas should also be considered. The clinical details should be carefully analyzed, and all possible suppositions have to be included in the diagnostic process. Management needs to be based on the best available evidence regarding what care is most likely to be effective for which patients in which settings. Advanced techniques and advanced skills are mutually reinforcing, and both are essential for correct diagnosis and management!

Financial support and sponsorship

Nil.

Conflicts of interest

There are no conflicts of interest.

**Bajpai Jyoti, Chauhan Bharat, Thippeswamy Ravi,
Ramani K. Subhash¹, Patil Asawari², Gupta Sudeep**

Departments of Medical Oncology, ¹Radiodiagnosis and ²Surgical Pathology,
Tata Memorial Center, Mumbai, Maharashtra, India

Correspondence to: Dr. Jyoti Bajpai,
E-mail: dr_jyotibajpai@yahoo.co.in

References

1. Tohnosu N, Narushima K, Sunouchi K, Saito T, Shimizu T, Tanaka H, *et al*. A case of breast cancer metastatic to the tail of the pancreas. *Breast Cancer* 2006;13:225-9.
2. Mountney J, Maury AC, Jackson AM, Coleman RE, Johnson AG. Pancreatic metastases from breast cancer: An unusual cause of biliary obstruction. *Eur J Surg Oncol* 1997;23:574-6.
3. Bonapasta SA, Gregori M, Lanza R, Sangiorgi E, Menghi A, Scarpini M, *et al*. Metastasis to the pancreas from breast cancer: Difficulties in diagnosis and controversies in treatment. *Breast Care (Basel)* 2010;5:170-3.
4. Pappo I, Feigin E, Uziely B, Amir G. Biliary and pancreatic metastases of breast carcinoma: Is surgical palliation indicated? *J Surg Oncol* 1991;46:211-4.
5. Adsay NV, Andea A, Basturk O, Kilinc N, Nassar H, Cheng JD. Secondary tumors of the pancreas: An analysis of a surgical and autopsy database and review of the literature. *Virchows Arch* 2004;444:527-35.
6. Pérez Ochoa A, Sáez Hernández F, Cajigas Fernández C, Pérez de la Lastra L, Ondiviela Gracia R, García de Polavieja M. Pancreatic metastases from ductal and lobular carcinomas of the breast. *Clin Transl Oncol* 2007;9:603-5.
7. O'Shaughnessy J. Extending survival with chemotherapy in metastatic breast cancer. *Oncologist* 2005;10 Suppl 3:20-9.
8. Nomizu T, Katagata N, Matsuoka T, Suzuki S, Yabuta T, Watanabe F, *et al*. A case of breast cancer metastatic to the head of the pancreas. *Breast Cancer* 1999;6:131-34.
9. Crippa S, Bonardi C, Bovo G, Mussi C, Angelini C, Uggeri F. Pancreaticoduodenectomy for pancreatic metastases from breast carcinoma. *JOP* 2004;5:377-83.
10. Adachi T, Morimoto T, Shimizu Y, Kodera Y, Hirai T, Torii A, *et al*. A case of pancreatic metastasis of breast cancer which recurred 22 years after operation. *J Jpn Surg Assoc* 2000;61:169-72.
11. Dar FS, Mukherjee S, Bhattacharya S. Surgery for secondary tumors of the pancreas. *HPB (Oxford)* 2008;10:498-500.

This is an open access article distributed under the terms of the Creative Commons Attribution-NonCommercial-ShareAlike 3.0 License, which allows others to remix, tweak, and build upon the work non-commercially, as long as the author is credited and the new creations are licensed under the identical terms.

How to cite this article: Jyoti B, Bharat C, Ravi T, Subhash RK, Asawari P, Sudeep G. Biliary obstruction in a metastatic tumor of the pancreas from breast cancer. *South Asian J Cancer* 2017;6: 10-9.