

Asynchronous cutaneous metastases of medullary thyroid carcinoma

DOI: 10.4103/2278-330X.155707

Dear Editor,

Thyroid cancer as the most common endocrine malignancy usually appears as primary nodules within the gland but less frequently presents with other features such as metastases, which truly impoverishes the prognosis of the patient.^[1,2] Medullary thyroid carcinoma (MTC), approximately 5-10% of all thyroid cancers, is an aggressive rare tumor arising from parafollicular cells (C-cells) with a neuroendocrine origin that secrete calcitonin.^[3,4] The skin metastasis usually presents as flesh-colored nodules that are tender; they may be itchy, and can be ulcerated.^[2] These lesions can metastasize to regional lymph nodes, but may also spread hematogenously to affect liver, lungs, bones, and rarely brain and skin.^[3,5] The skin metastasis of MTC is very rare and only 16 cases reported in English literature up to date.^[1-5]

We describe here a 50-year-old woman who presented with two enlarging, flesh-colored, tender, subcutaneous nodules in the neck. In the history, MTC was diagnosed 4 years prior to presentation and thyroidectomy was performed subsequently. Two years later, radical neck dissection revealed recurrence of MTC at the local surgical site with nine reactive lymph nodes. One year after radical neck dissection, re-excision of the neck subcutaneous nodules revealed metastasis of the medullary carcinoma to skin and one lymph node. Now she presented with two right-side subcutaneous nodules of the neck. The patient underwent external-beam radiation treatment after metastasis to the lymph node and skin but she died six months after recent metastasis.

Histopathologic examination revealed a well-circumscribed tumor in dermis composed of delicate trabecules, cohesive sheets and nests consisting of small to medium-sized cells with ovoid nuclei, prominent nucleoli, and pale to eosinophilic cytoplasm [Figure 1]. Histopathologic findings were in favor of poorly-differentiated carcinoma. Immunohistochemistry shows positive reactivity to chromogranin, synaptophysin, CD56, carcinoembryonic antigen, and S-100 which is suggestive of neuroendocrine carcinoma. Positive reaction to thyroid transcription

factor (TTF)-1 and calcitonin and no reaction with thyroglobulin were consistent with metastatic MTC [Figure 2a and 2b]. Melanoma, merkel cell carcinoma, and mesothelioma were ruled out by negative reaction to HMB-45, CD20, and calretinin, respectively.

Metastasis of thyroid carcinoma to skin is extremely rare and usually occurs in the setting of disseminated malignancy. Cutaneous metastasis of MTC usually occurs in the late stage of malignancy and average length of survival after diagnosis of cutaneous metastasis is very low.^[5] Occasionally, cutaneous metastasis of MTC is the first presentation of the

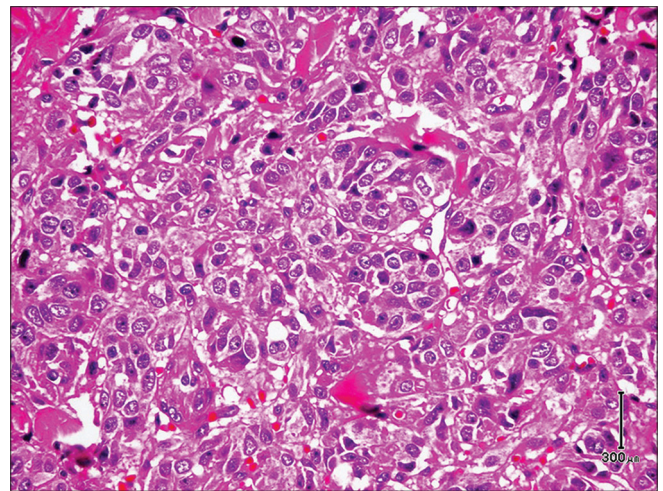


Figure 1: Poorly-differentiated carcinoma with delicate trabecules, cohesive sheets, and nests of small to medium-sized cells (H and E, original magnification x20)

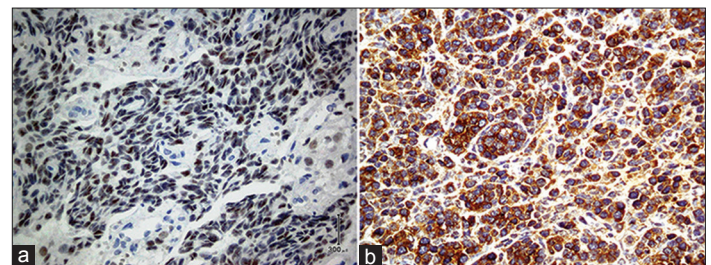


Figure 2: (a) Thyroid transcription factor-1 staining shows nuclear immunoreactivity of tumor cells (immunohistochemical staining, original magnification x20). (b) Positive immunoreactivity of tumor cells with calcitonin (immunohistochemical staining, original magnification x20)

malignancy.^[2,4] Scalp is the most common site of metastasis and the investigation of a flesh-colored skin nodule, particularly in the upper part of the body, should raise the possibility of MTC.^[2] Immunohistochemistry study is helpful in distinguishing primary from secondary malignancies. Negative reaction to HMB-45 and CK20 exclude melanoma and Merkel cell carcinoma. Immunoreaction to TTF-1 is helpful to distinguish metastatic lung and thyroid carcinoma from metastatic gastrointestinal carcinoma and mesothelioma which are negative. Mesothelioma is ruled out by negative reaction to calretinin. Immunoreactivity to thyroglobulin can exclude lung carcinoma and differentiate papillary and follicular carcinoma of thyroid from MTC which is negative.^[2] Precise diagnosis of MTC is upon positive reactivity to calcitonin and neuroendocrine markers, including chromogranin, synaptophysin, and CD56.

This asynchronous metastasis of MTC to skin is extremely rare presenting in the late stage of a disseminated malignancy. Cutaneous metastasis of MTC should be considered in any patients with flesh-colored skin nodule in upper part

of the trunk. Histologically, it should be distinguished from primary skin tumors and metastasis of lung and gastrointestinal carcinoma as well as mesothelioma by the aid of immunohistochemistry staining.

Alireza Ghanadan

Department of Dermatopathology, Razi Hospital, School of Medicine, Tehran University of Medical Sciences, Tehran, Iran

Correspondence to: Dr. Alireza Ghanadan,
E-mail: dermpath101@gmail.com

References

1. Dahl PR, Brodland DG, Goellner JR, Hay ID. Thyroid carcinoma metastatic to the skin: A cutaneous manifestation of a widely disseminated malignancy. *J Am Acad Dermatol* 1997;36:531-7.
2. Alwaheeb S, Ghazarian D, Boerner SL, Asa SL. Cutaneous manifestations of thyroid cancer: A report of four cases and review of the literature. *J Clin Pathol* 2004;57:435-8.
3. Santarpia L, El-Naggar AK, Sherman SI, Hymes SR, Gagel RF, Shaw S, *et al*. Four patients with cutaneous metastases from medullary thyroid cancer. *Thyroid* 2008;18:901-5.
4. Sanii S, Tavangar SM. Cutaneous metastasis of medullary thyroid carcinoma as the initial manifestation of an otherwise limited malignancy: A case report. *Am J Dermatopathol* 2011;33:716-8.
5. Nashed C, Sakpal SV, Cherneykin S, Chamberlain RS. Medullary thyroid carcinoma metastatic to skin. *J Cutan Pathol* 2010;37:1237-40