

### Imatinib-associated massive upper gastrointestinal hemorrhage and hepatic encephalopathy in a child with Philadelphia positive acute lymphoblastic leukemia: A case report and review of the literature

DOI: 10.4103/2278-330X.142997

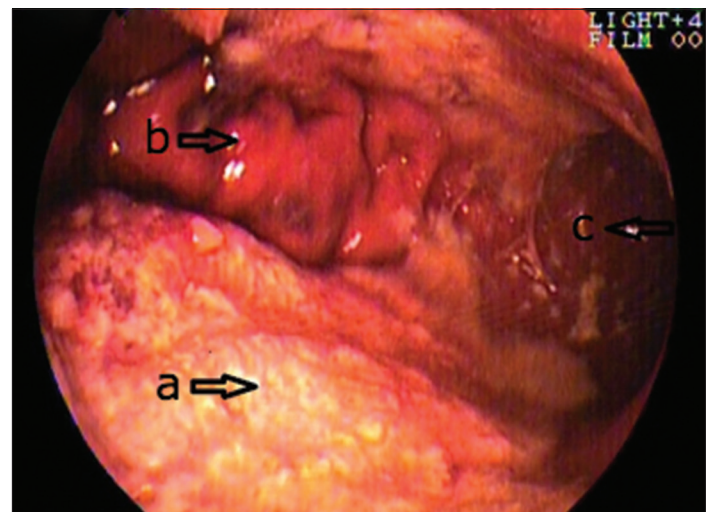
Dear Editor

The discovery of imatinib mesylate, a selective tyrosine kinase inhibitor, has revolutionized the treatment of chronic myeloid leukemia (CML), gastrointestinal stromal tumor (GIST), and Philadelphia-chromosome-positive acute lymphoblastic leukemia (Ph<sup>+</sup> ALL). This has been possible owing to its ability to target specific receptors and relatively good tolerability. Although the minor side effects of imatinib have been well-described, literature on major side effects is scarce, especially in Ph<sup>+</sup> ALL. Herein, we report the case of a child with Ph<sup>+</sup> ALL who succumbed to the serious side effects of imatinib.

A 10-year-old boy diagnosed with moderate risk B-ALL, treated as per BFM-95 protocol sustained a combined bone marrow and testicular relapse 30 months after initiation of treatment. At relapse, BCR-ABL chimeric transcript was detected. He had not received imatinib during initial therapy. The 1 week of relapse treatment included dexamethasone (6 mg/m<sup>2</sup>/day) under cover of tumor lysis prophylaxis. After 3 days of dexamethasone, imatinib (300 mg/m<sup>2</sup>) was added. He was planned to be treated with BFM REZ 2002 protocol. At admission, his physical examination was unremarkable without any signs of cutaneous or mucosal bleed. Hemogram showed hemoglobin 9.1 g/dl, total leukocyte count 1500/μl and platelet count 60,000/μl. Baseline kidney and liver function were normal. On 1 day of admission, even before the planned chemotherapy, he developed multiple episodes of upper GI hemorrhage, necessitating transfer to the intensive care unit. He received packed cells and platelet transfusions along with inotropic support, pantoprazole infusion, and antibiotics. All oral drugs including imatinib were stopped. After initial stabilization, an urgent upper GI endoscopy revealed thickened gastric folds with overlying extensive ulceration involving the entire fundus and body of the stomach, with evidence of active bleeding [Figure 1]. Biopsy was not done for risk of perforation. Coagulation profile

was normal. Over next 96 h, hematemesis gradually reduced and inotropic support was withdrawn. However, on day 3 of admission, he developed icterus with total bilirubin 5.3 mg/dl; direct bilirubin 3.2 mg/dl and SGPT 220 U/L which rapidly progressed to hepatic encephalopathy (D7 serum bilirubin 16.7 mg/dl). Prothrombin time remained normal. Viral markers (hepatitis B surface antigen and anti-hepatitis C virus) were negative, and ultrasound showed homogenous altered hepatic echotexture without any focal lesions. There was no obvious cause for hepatopathy. Despite aggressive supportive measures, his condition rapidly deteriorated, and child succumbed to GI hemorrhage and hepatic failure.

The possible causes of upper GI hemorrhage during ALL induction include steroid-induced erosive gastritis, thrombocytopenia, and coagulopathy secondary to sepsis or drug. The massive nature of hemorrhage in the presence of platelet count 60,000/μl and normal coagulation was unusual and indicated other factors. In the light of endoscopic evidence of confluent thickening of gastric mucosa, possibility of leukemic infiltration was entertained though it could not be confirmed histologically owing to child's critical condition.



**Figure 1:** Endoscopic image of stomach showing (a) extensively thickened and ulcerated mucosa of the body of the stomach; (b) normal gastric folds at lesser curvature; (c) friable mucosa at antrum

Review of literature revealed similar reports of GI hemorrhage with imatinib in patients with GIST and CML, postulated to be due to local tumor lysis and secondary bleeding.

Imatinib is generally well-tolerated in its main indications including CML, GIST, and Ph<sup>+</sup> ALL with minor adverse effects like fluid retention, nausea, vomiting, gastritis, diarrhea, myalgia, rash, fatigue etc.<sup>[1-3]</sup> GI hemorrhage is a known complication of imatinib therapy in GIST with an incidence of 3-5%.<sup>[1]</sup> It possibly occurs as a result of local tumor lysis leading to tumor necrosis and thus, rupture of vessels invading the tumor. A retrospective review of seven patients with metastatic GIST, treated on imatinib was shown to have extensive necrosis suggesting tumor lysis.<sup>[4]</sup> GI bleeding complicates 4-5% cases of CML treated on imatinib, possibly due to local irritant effect of imatinib on GI mucosa.<sup>[5]</sup> Unlike GIST and CML, life-threatening upper GI bleed has not been described in Ph<sup>+</sup> ALL previously, to the best of our knowledge. This may well be due to the fact that in the past, the drug was used only in the latter part of induction therapy, when risk of tumor lysis was minimal. Its use in early induction therapy needs to be undertaken with extreme caution.

Imatinib-induced toxic hepatitis has been described in 5.5% cases of GIST and 3-6% cases of CML.<sup>[1,6]</sup> Its manifestation ranges from anicteric hepatitis to fatal acute liver failure with a variable latency period. Although transient transaminitis and few cases of hepatic failure have been reported in Ph<sup>+</sup> ALL in children, acute fatal progressive hepatotoxicity has not been described.<sup>[6,7]</sup>

Simultaneous occurrence of massive upper GI hemorrhage and hepatic encephalopathy is uncommon during induction

therapy in ALL. Although generally imatinib has a favorable safety profile, one should remain vigilant about its rare but catastrophic side effects, particularly during early induction.

**Silky Jain, Sandeep Jain, Gauri Kapoor**

Department of Pediatric Hematology and Oncology, Rajiv Gandhi Cancer Institute and Research Centre, Delhi, India

**Correspondence to:** Dr. Gauri Kapoor,  
E-mail: kapoor.gauri@rgcirc.org

## References

1. Demetri GD, von Mehren M, Blanke CD, Van den Abbeele AD, Eisenberg B, Roberts PJ, *et al.* Efficacy and safety of imatinib mesylate in advanced gastrointestinal stromal tumors. *N Engl J Med* 2002;347:472-80.
2. Druker BJ, Talpaz M, Resta DJ, Peng B, Buchdunger E, Ford JM, *et al.* Efficacy and safety of a specific inhibitor of the BCR-ABL tyrosine kinase in chronic myeloid leukemia. *N Engl J Med* 2001;344:1031-7.
3. Druker BJ, Sawyers CL, Kantarjian H, Resta DJ, Reese SF, Ford JM, *et al.* Activity of a specific inhibitor of the BCR-ABL tyrosine kinase in the blast crisis of chronic myeloid leukemia and acute lymphoblastic leukemia with the Philadelphia chromosome. *N Engl J Med* 2001;344:1038-42.
4. Bechtold RE, Chen MY, Stanton CA, Savage PD, Levine EA. Cystic changes in hepatic and peritoneal metastases from gastrointestinal stromal tumors treated with Gleevec. *Abdom Imaging* 2003;28:808-14.
5. Deininger MW, O'Brien SG, Ford JM, Druker BJ. Practical management of patients with chronic myeloid leukemia receiving imatinib. *J Clin Oncol* 2003;21:1637-47.
6. Schultz KR, Bowman WP, Aledo A, Slayton WB, Sather H, Devidas M, *et al.* Improved early event-free survival with imatinib in Philadelphia chromosome-positive acute lymphoblastic leukemia: A Children's Oncology Group Study. *J Clin Oncol* 2009;27:5175-81.
7. Biondi A, Schrappe M, De Lorenzo P, Castor A, Lucchini G, Gandemer V, *et al.* Imatinib after induction for treatment of children and adolescents with Philadelphia-chromosome-positive acute lymphoblastic leukaemia (EsPhALL): A randomised, open-label, intergroup study. *Lancet Oncol* 2012;13:936-45.