

A rare case of nonfamilial polyposis coli with immunohistochemical observations with mucin product genes MUC2 and MUC5AC in adenoma-carcinoma progression

DOI: 10.4103/2278-330X.142994

Dear Editor,

Colorectal carcinoma has been regarded as arising mainly from polyps through multiple transition stages both in familial and nonfamilial adenomatous polyposis coli.^[1] Mucins (MUCs) are high molecular weight glycoproteins which express differently in graded neoplastic transformation of adenomatous polyps in nonfamilial polyposis coli.^[2] Alterations in MUC genes like MUC2 and MUC5AC expression has been studied recently in progression of “adenoma-carcinoma” in case of colorectal carcinoma.^[3] We had an opportunity to study altered expression of MUC2 and MUC5AC in a case of nonfamilial polyposis coli. Recent studies have indicated that expression of MUC genes and their altered products can act as predictors of malignant transformation in colorectal polyps.^[2] Some workers believe that MUC studies may be useful in understanding sensitivity to chemotherapeutic agents and prognosis of colorectal cancer.^[4]

We encountered a rare case of nonfamilial polyposis coli in a 45-year-old male. He was admitted for loss of weight and appetite since 4 months. Detailed history revealed that, there was no such case in family members. Colonoscopy revealed large twin polyps measuring 3 cm in diameter 11 cm from the anal verge. Also seen were variably sized multiple polyps carpeted over the length of colonic mucosa [Figure 1]. Multiple biopsies taken from the polyps showed hyperplastic polyp (HP), adenomatous polyp with low-grade dysplasia (LGD), and adenomatous polyp with high grade dysplasia (HGD).

Based on these investigations, he underwent total colectomy. We received colectomy specimen measuring 115 cm in length. The luminal aspect showed a large mass measuring 12 cm × 7 cm × 5 cm at ileocaecal junction and ascending colon. The mass on cut section showed gray white and mucoid areas along with hemorrhages and cyst formations. Furthermore seen were multiple polyps ranging in size from 0.5 cm to 6 cm [Figure 1]. Multiple sections from various sized polyps were subjected to histopathological (HPE) and immunohistochemical (IHC) examination, that is, MUC2 and MUC5AC. HPE study revealed spectrum of polyps ranging from HP to LGD polyp to HGD polyp. Sections from the

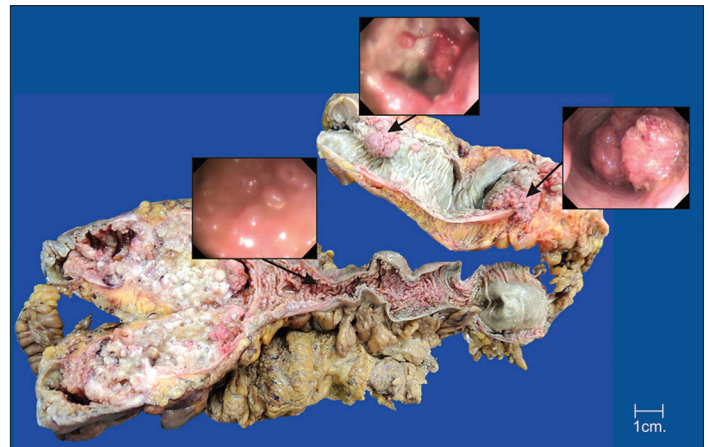


Figure 1: Total colectomy specimen measuring 115 cm in length. The luminal aspect shows large mass measuring 12 cm × 7 cm × 5 cm at ileocaecal junction and ascending colon. The mass on cut section show gray white and mucoid areas. Also seen are multiple polyps ranging in size from 0.5 cm to 6 cm carpeted over the length of colonic mucosa and their corresponding endoscopic images

large ileocaecal mass showed high grade MUC secreting adenocarcinoma (MAdCa).

For assessing immunoreactivity, we followed the scoring method described by Chinese workers.^[1] The expression of MUC2 and MUC5AC was prominently characterized by perinuclear and diffuse cytoplasmic staining. The MUC2 labeling was generally increased in the cytoplasm of columnar cells and goblet cells in HP group and the positivity was also observed in apical cytoplasm of columnar cells, especially in LGD and HGD polyps. MUC2 was negative in MAdCa. On the other hand, MUC5AC staining was absent in HP, variable in dysplastic polyps, and strongly positive in MAdCa.

MUC staining was scored in neoplastic cells of tissue containing either dysplastic epithelium or carcinoma. The range of cytoplasmic staining (0: 0-5%, 1: 6-30%, 2: 31-60%, and 3: 61-100%) and the intensity of staining (0: no stain, 1: Weak staining, 2: Intermediate staining, and 3: Strong staining) was assessed in at least eight high power fields by two observers and the average grade was taken. The final staining score was defined as the product of scores for the range and cytoplasmic staining intensity. Staining was designated as negative if the staining score was 0 or 1, intermediate for 2, 3 or 4 and high for 6-9.^[1] The findings are depicted in Table 1.

Our experience with this case indicates that abnormal expression of MUC2 and MUC5AC. It correlates well with

Table 1: Staining score of MUC2 and MUC5A with histomorphological diagnosis

Mucin type	Normal mucosa	HP	LGD	HGD	Mucinous adenocarcinoma
MUC2	High	High	High	Intermediate	Negative
MUC5AC	Negative	Negative	Intermediate	Intermediate	High

MUC=Mucin, HP=Hyperplastic polyp, LGD=Low-grade dysplasia, HGD=High-grade dysplasia, MUC=Mucins

histomorphological grades. The concordance was also noted between MUC2 and MUC5AC expression. The absent expression of MUC2 and strong expression of MUC5AC in MAdCa as observed by us has been documented by other workers also.^[5,6] The observations also highlight progression of colorectal carcinoma in nonfamilial polyposis coli confirming the adenoma-carcinoma hypothesis by extensively studying the single case. Although this pathway of tumorigenesis is widely accepted there may be other pathways associated with mutation in mismatch repair genes.^[7] We feel that all polypectomy specimens should be studied not only microscopically, but also with IHC for MUC2 and MUC5AC which may pave the way for better understanding of malignant potential in these cases, and impact therapeutic management.

**Sanjay D. Deshmukh, Siddhi Gaurish Sinai
Khandeparkar, Bageshri P. Gogate, Mrunal Kesari**

Department of Pathology, Shrimati Kashibai Navale Medical College and General Hospital, Pune, Maharashtra, India

Correspondence to: Dr. Sanjay D. Deshmukh
E-mail: drsanjay123in@yahoo.co.in

References

1. Bu XD, Li N, Tian XQ, Li L, Wang JS, Yu XJ, *et al.* Altered expression of MUC2 and MUC5AC in progression of colorectal carcinoma. *World J Gastroenterol* 2010;16:4089-94.
2. Molaei M, Mansoori BK, Mashayekhi R, Vahedi M, Pourhoseingholi MA, Fatemi SR, *et al.* Mucins in neoplastic spectrum of colorectal polyps: Can they provide predictions? *BMC Cancer* 2010;10:537.
3. Kikuchi-Yanoshita R, Konishi M, Fukunari H, Tanaka K, Miyaki M. Loss of expression of the DCC gene during progression of colorectal carcinomas in familial adenomatous polyposis and non-familial adenomatous polyposis patients. *Cancer Res* 1992;52:3801-3.
4. Negri FV, Wotherspoon A, Cunningham D, Norman AR, Chong G, Ross PJ. Mucinous histology predicts for reduced fluorouracil responsiveness and survival in advanced colorectal cancer. *Ann Oncol* 2005;16:1305-10.
5. Ajioka Y, Allison LJ, Jass JR. Significance of MUC1 and MUC2 mucin expression in colorectal cancer. *J Clin Pathol* 1996;49:560-4.
6. Perez RO, Bresciani BH, Bresciani C, Proscurshim I, Kiss D, Gama-Rodrigues J, *et al.* Mucinous colorectal adenocarcinoma: Influence of mucin expression (Muc 1, 2 and 5) on clinico-pathological features and prognosis. *Int J Colorectal Dis* 2008;23:757-65.
7. Ward R, Meagher A, Tomlinson I, O'Connor T, Norrie M, Wu R, *et al.* Microsatellite instability and the clinicopathological features of sporadic colorectal cancer. *Gut* 2001;48:821-9.