

CASE REPORT

Erlotinib eradicates brain metastases from epidermal growth factor receptor mutant non-small cell lung cancer

Siavash Jabbari, Michael Pins¹, Kimberly Kruczek², Chadi Nabhan^{2,3}

Departments of Radiation Oncology, ¹Pathology, and ²Medicine, ³Division of Hematology and Oncology, Advocate Lutheran General Hospital, Park Ridge, IL, USA

Access this article online

Website: www.avicennajmed.com

DOI: 10.4103/2231-0770.90916

Quick Response Code:



ABSTRACT

Erlotinib is active in patients with lung cancer; especially those who demonstrate a mutation in exons 18-21 in the epidermal growth factor receptor (EGFR) gene. Patients with lung cancer and brain metastases have poor prognosis as systemic chemotherapy is ineffective in treating the central nervous system (CNS) metastases due to its inability to cross the blood brain barrier. Herein, we report a case of a 61 year old female who presented with stage IV adenocarcinoma of the lung with bilateral cerebral and cerebellar CNS involvement. The patient's tumor harbored a mutation in exon 19 in the EGFR gene. Treatment with erlotinib was started as soon as the molecular studies were available with remarkable and complete radiographic response in the CNS disease, and complete resolution of the previously detected metastases. The patient did not receive any other CNS intervention and radiation was not given due to the lack of CNS symptoms.

Key words: Brain metastasis, Erlotinib, lung cancer, tarceva

INTRODUCTION

A 61-year old Hispanic non-smoker female presented with several months history of progressive shortness of breath, non-productive cough, and dyspnea on exertion. Chest radiograph demonstrated bilateral pulmonary nodules necessitating a computed tomography (CT) scan of the chest, confirming the nodular findings and showing airspace opacities [Figure 1a]. The patient underwent bronchoscopy with right middle lobe transbronchial biopsy showing well-differentiated adenocarcinoma with bronchoalveolar growth pattern [Figure 2]. All other cultures and stains including acid fast bacilli studies were negative. This patient had stage IV disease, and screening magnetic resonance imaging (MRI) of the brain further confirmed it, by demonstrating numerous bilateral cerebral and cerebellar metastases [Figures 3a and 4a]. Physical examination showed a dyspneic and hypoxic woman with bilateral basilar crackles and resting tachycardia. No focal neurologic signs were identified. Laboratory studies were unremarkable.

Given the degree of hypoxemia, the patient was hospitalized for closer observation and management. She was admitted to the intensive care unit and maintained on high-flow oxygen. Whole brain radiation therapy had been considered prior to admission, but given the marked progression of systemic symptoms as compared to CNS findings, the patient was initiated on systemic therapy with carboplatin and pemetrexed, while radiotherapy was not instituted. Sputum cultures were positive for *mycoplasma pneumonia* for which she was started on intravenous antibiotics as well. Subsequent molecular studies on the biopsy specimen revealed an exon-19 mutation in the epidermal growth factor receptor (EGFR) gene. The patient was then initiated on erlotinib (Genentech, Inc) and chemotherapy was halted. Her respiratory symptoms started to improve within 72 hours at which point she no longer required supplemental oxygen and was discharged. Repeat radiographic studies six weeks later demonstrated significant improvement in her chest disease [Figure 1b] but most importantly, a repeat MRI of the brain

Address for correspondence: Dr. Siavash Jabbari, 1700 Luther Lane, Room 1110, Park Ridge, IL 60068, E-mail: siavashjabbari@gmail.com

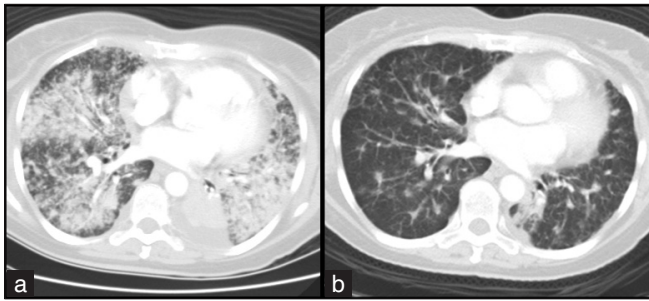


Figure 1: Computed tomography of the chest before (a) and after erlotinib (b)

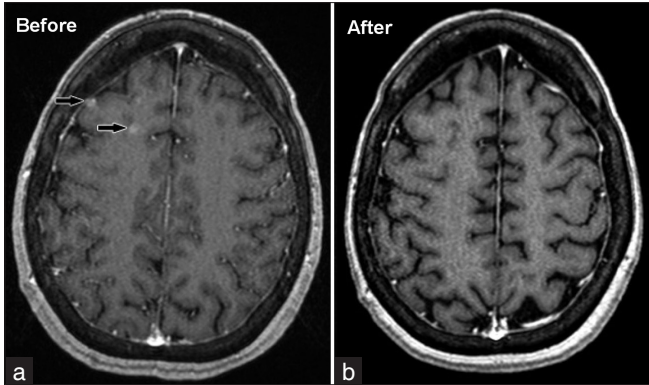


Figure 3: Magnetic Resonance Imaging of the brain before (a) and after erlotinib (b)

showed complete resolution of her previously detected CNS metastases [Figures 3b and 4b].

DISCUSSION

In this report, we have attempted to show the complete radiographic response of intracranial metastases for non-small cell lung cancer (NSCLCA) a patient receiving erlotinib without prior radiotherapy. The possibility that these parenchymal lesions were related to the mycoplasma infection cultured from the sputum and treated with antibiotics is refuted by the fact that parenchymal brain lesions do not occur as a result of respiratory mycoplasma infection.^[1,2] While this patient did receive systemic chemotherapy as well, it is unlikely that the CNS response was due to the carboplatin and pemetrexed that the patient received initially.

With the exception of select histologies, such as lymphomas and germ cell tumors, the use of conventional cytotoxic therapies to treat brain metastases in lieu of brain irradiation has historically been considered ineffective. This has in large been attributed to the “blood brain barrier” inhibiting the biodistribution of cytotoxic agents to metastatic CNS disease. Small biologic molecules, such as erlotinib, however, may in theory not be limited by such barrier. Erlotinib is an EGFR tyrosine kinase inhibitor (TKI) approved for the treatment of patients with NSCLCA.^[3]

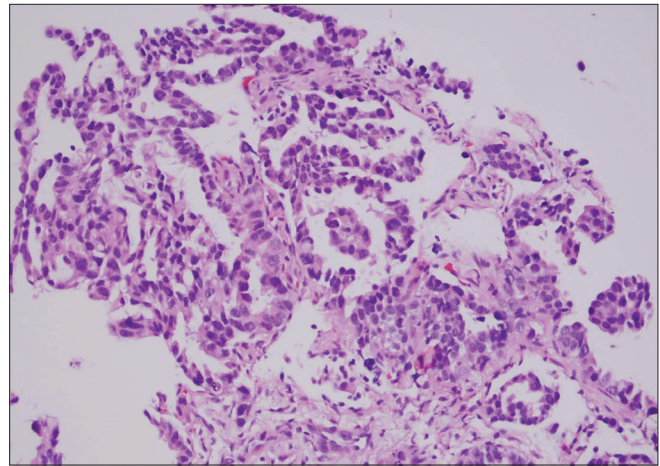


Figure 2: Histopathologic diagnosis of adenocarcinoma of the lung through transbronchial biopsy demonstrating bronchoalveolar growth pattern

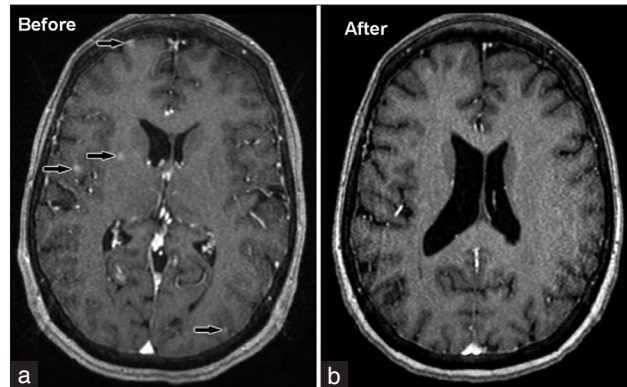


Figure 4: Magnetic Resonance Imaging of the brain (another view) before (a) and after erlotinib (b)

Recent reports have confirmed that tumors with somatic activating mutations of the tyrosine kinase domain of the EGFR gene are highly associated with sensitivity to EGFR TKIs.^[4,5] In fact, studies have suggested superiority of these agents when compared to chemotherapy as a front-line approach to patients with metastatic NSCLCA if they harbor specific mutations; specifically in exons 19 and 21.^[6] While erlotinib has modest activity in the treatment of advanced NSCLCA, data on its activity in disease involving the CNS is sparse. Lai *et al.*, reported the first case of CNS metastases responding to erlotinib in a Chinese man whose disease harbored an EGFR gene mutation on exons 18-21; however, the patient had received brain radiotherapy 4 months prior to CNS recurrence clouding the benefit of erlotinib.^[7] Fekrazad *et al.*, reported on a patient who underwent radiotherapy for CNS involvement from her metastatic NSCLCA to later receive erlotinib upon intracranial recurrence.^[8] The patient demonstrated complete resolution of the brain metastases. However, it is unclear whether such response was due to erlotinib or to delayed effects of radiotherapy given 3 months prior.^[9,10] Dhruva and Socinski reported on erlotinib having activity

in patients with leptomeningeal disease however the dose used in that case was 600 mg every 4-days for a total of 10 months as part of a clinical trial.^[11] Finally, Masago *et al.*, reported on a good, but not complete, response of CNS involvement when a patient with double somatic EGFR gene mutation received erlotinib.^[12]

The demonstrable activity of erlotinib in patients with CNS involvement has important clinical implications. Implementing this therapy as opposed to or with the delay of whole brain radiotherapy, especially in asymptomatic patients or those with minimal CNS involvement, would obviate or delay toxicity associated with radiation in patients who do not have CNS symptoms, and where delaying direct CNS treatment is considered clinically safe. The neurocognitive detriment of whole brain irradiation for treatment or prophylaxis of brain metastasis has now been confirmed in multiple phase III randomized trials employing sensitive neurocognitive testing.^[13,14] Accordingly, upfront resection and/or radiosurgery alone, with reservation of whole brain irradiation for salvage, has now been established as a standard of care for select patients with single or oligometastatic brain lesions and other favorable prognostic features. This strategy, however, is feasible only for patients with limited CNS disease, and whole brain irradiation remains the standard of care for the majority of patients with more extensive CNS involvement.^[13,15]

CONCLUSION

In conclusion, this report suggests the potential feasibility and safety of erlotinib as a therapeutic option for NSCLCA patients with asymptomatic CNS metastases who harbor exons 18-21 EGFR gene mutations, and when ablative focal CNS directed therapies are not feasible, and competing comorbidities preclude whole brain irradiation. This hypothesis generated by the report requires validation by prospective trials of appropriately selected patients.

REFERENCES

1. Candler PM, Dale RC. Three cases of central nervous system complications associated with *Mycoplasma pneumoniae*. *Pediatr*

2. Neurology 2004;31:133-8.
2. Guleria R, Nisar N, Chawla TC, Biswas NR. *Mycoplasma pneumoniae* and central nervous system complications: A review. *J Lab Clin Med* 2005;146:55-63.
3. Shepherd FA, Rodrigues Pereira J, Ciuleanu T, Tan EH, Hirsh V, Thongprasert S, *et al.*; National Cancer Institute of Canada Clinical Trials Group. Erlotinib in previously treated non-small-cell lung cancer. *N Engl J Med* 2005;353:123-32.
4. Lynch TJ, Bell DW, Sordella R, Gurubhagavatula S, Okimoto RA, Brannigan BW, *et al.* Activating mutations in the epidermal growth factor receptor underlying responsiveness of non-small-cell lung cancer to gefitinib. *N Engl J Med* 2004;350:2129-39.
5. Paez JG, Jänne PA, Lee JC, Tracy S, Greulich H, Gabriel S, *et al.* EGFR mutations in lung cancer: Correlation with clinical response to gefitinib therapy. *Science* 2004;304:1497-500.
6. Mitsudomi T, Morita S, Yatabe Y, Negoro S, Okamoto I, Tsurutani J, *et al.* West Japan Oncology Group. Gefitinib versus cisplatin plus docetaxel in patients with non-small-cell lung cancer harbouring mutations of the epidermal growth factor receptor (WJTOG3405): An open label, randomised phase 3 trial. *Lancet Oncol* 2010;11:121-8.
7. Lai CS, Boshoff C, Falzon M, Lee SM. Complete response to erlotinib treatment in brain metastases from recurrent NSCLC. *Thorax* 2006;61:91.
8. Fekrazad MH, Ravindranathan M, Jones DV Jr. Response of intracranial metastases to erlotinib therapy. *J Clin Oncol* 2007;25:5024-6.
9. Hall E, Giaccia A. *Radiobiology for the Radiologist*. 6th ed. Philadelphia: Lippincott Wilkins and Williams; 2006.
10. Kubicky C, Chan L, Tsuji S, Nakamura JL, Haas-Kogan D, Larson AD. CNS. *Handbook of Evidence-Based Radiation Oncology*. In: Her M, editor. 2nd ed. New York: Springer; 2010.
11. Dhruva N, Socinski MA. Carcinomatous meningitis in non-small-cell lung cancer: Response to high-dose erlotinib. *J Clin Oncol* 2009;27:e31-2.
12. Masago K, Togashi Y, Fukudo M, Terada T, Irisa K, Sakamori Y, *et al.* Good clinical response to Erlotinib in a non-small cell lung cancer patient harboring multiple brain metastases and a double active somatic epidermal growth factor gene mutation. *Case Rep Oncol* 2010;3:98-105.
13. Chang EL, Wefel JS, Hess KR, Allen PK, Lang FF, Kornguth DG, *et al.* Neurocognition in patients with brain metastases treated with radiosurgery or radiosurgery plus whole-brain irradiation: A randomised controlled trial. *Lancet Oncol* 2009;10:1037-44.
14. Li J, Bentzen SM, Li J, Renschler M, Mehta MP. Relationship between neurocognitive function and quality of life after whole-brain radiotherapy in patients with brain metastasis. *Int J Radiat Oncol Biol Phys* 2008;71:64-70.
15. Sneed PK, Suh JH, Goetsch SJ, Sanghavi SN, Chappell R, Buatti JM, *et al.* A multi-institutional review of radiosurgery alone vs. radiosurgery with whole brain radiotherapy as the initial management of brain metastases. *Int J Radiat Oncol Biol Phys* 2002;53:519-26.

Cite this article as: Jabbari S, Pins M, Kruczek K, Nabhan C. Erlotinib eradicates brain metastases from epidermal growth factor receptor mutant non-small cell lung cancer. *Avicenna J Med* 2011;1:52-4.

Source of Support: Nil, **Conflict of Interest:** None declared.