

## CASE REPORT

# Image-guided ureteral reconstruction using rendezvous technique for complex ureteric transection after gunshot injuries

Mohammad Arabi, Abdulaziz Mat'hami, Mohammad T. Said<sup>1</sup>, Muhammad Bulbul<sup>2</sup>, Maurice Haddad<sup>3</sup>, Aghiad Al-Kutoubi<sup>3</sup>

Department of Medical Imaging, Interventional Radiology Division, Prince Sultan Military Medical City, <sup>1</sup>Department of Urology, Prince Sultan Military Medical City, Riyadh, Kingdom of Saudi Arabia, Departments of <sup>2</sup>Urology and <sup>3</sup>Diagnostic Radiology, American University of Beirut Medical Center, Beirut, Lebanon

## Access this article online

Website: [www.avicennajmed.com](http://www.avicennajmed.com)

DOI: 10.4103/2231-0770.173581

## Quick Response Code:



## ABSTRACT

Management of complex ureteric transection poses a significant clinical challenge, particularly after gunshot injuries due to marked distortion of anatomy and associated tissue loss. We report two cases of total ureteric transection due to gunshot injury successfully repaired using fluoroscopy-guided rendezvous procedure and double J stent placement. This minimally invasive approach may offer a safe and effective technique to repair complete ureteral transection and obviate the need for complex surgical procedures.

**Key words:** Gunshot injuries, rendezvous, ureteral reconstruction, ureteric transection

## INTRODUCTION

Ureteric injuries or transections are traditionally treated by diversion nephrostomy and double J stenting prior to definitive surgical repair.<sup>[1]</sup> However, the complexity of ureteral injury dictates the treatment course, which may ultimately result in renal loss or permanent external drainage. Iatrogenic injuries are often of expected anatomic locations and associated with minimal tissue loss. Conversely, missile injuries result in significant tissue damage causing the unpredictable length of ureteric loss that makes a diagnosis, and therefore, treatment more challenging. While maintaining ureteral integrity is the mainstay for future surgical or endourologic repair, it can be sometimes difficult to pass the area of penetrating injury either antegradely or retrogradely. Here, we report two cases of successful repair of complex ureteral gunshot injuries using rendezvous technique requiring no additional surgical repair.

## CASE REPORTS

The reporting institutions do not require institutional review board approval for case reports.

**Address for correspondence:** Dr. Mohammad Arabi, Department of Medical Imaging, Prince Sultan Military Medical City, Riyadh 11159, Kingdom of Saudi Arabia.  
E-mail: [marabi2004@hotmail.com](mailto:marabi2004@hotmail.com)

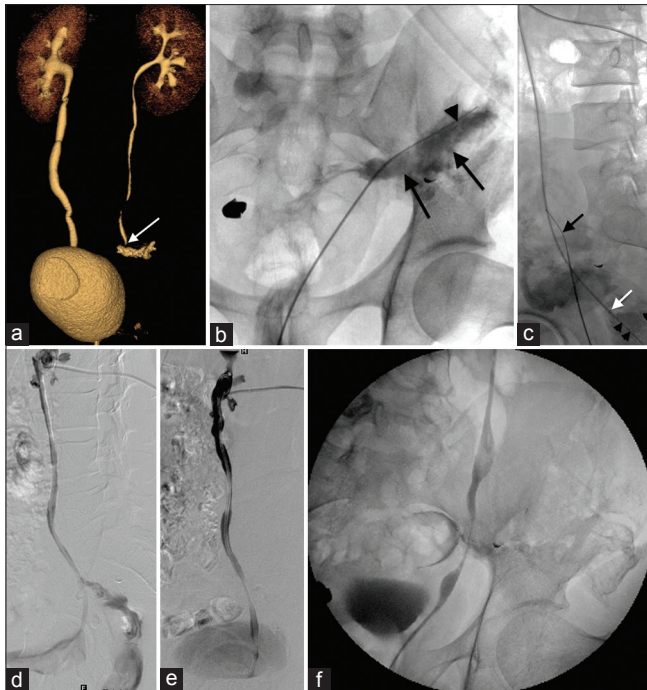
### Case 1

A 33-year-old man presented after a gunshot injury to the pelvis resulting in comminuted left pelvic fractures and open wound in the left lower quadrant. A computed tomography (CT) urography was performed due to high volume leak from the wound. This demonstrated a large collection in the left iliac fossa with evidence of urine leak from the distal left ureter [Figure 1a]. The patient was initially referred for diversion nephrostomy. However, due to the presence of the large pelvic collection, we considered attempting rendezvous technique. Cystoscopy was done, and left ureteric cannulation showed total ureteric transection of the ureter and contrast leak into the left pelvic collection [Figure 1b]. A 0.018" hydrophilic wire was introduced into the cavity, and the patient was transferred to the angiography suite. In a right decubitus position and under moderate sedation, left percutaneous nephrostomy

This is an open access article distributed under the terms of the Creative Commons Attribution-NonCommercial-ShareAlike 3.0 License, which allows others to remix, tweak, and build upon the work non-commercially, as long as the author is credited and the new creations are licensed under the identical terms.

**For reprints contact:** [reprints@medknow.com](mailto:reprints@medknow.com)

**Cite this article as:** Arabi M, Mat'hami A, Said MT, Bulbul M, Haddad M, Al-Kutoubi A. Image-guided ureteral reconstruction using rendezvous technique for complex ureteric transection after gunshot injuries. *Avicenna J Med* 2016;6:28-30.



**Figure 1:** (a) Volume rendering an image of the excretory phase of the computed tomography urography shows contrast leak at the distal ureter (arrows). (b) Retrograde ureterogram shows contrast leak from the pelvic portion of the left ureter (arrows). A guide wire (arrowheads) was introduced into the left pelvic collection. (c) Lateral image shows the antegrade transnephrostomic guidewire (arrowheads) intersecting with the retrograde ureteric wire (black arrow) in the pelvic collection. The tip of the sheath is introduced into the collection cavity (arrow). (d) Digital subtraction nephrostogram at 1-month shows partial healing of the ureter and decrease in the fistula. (e) 4-month follow-up shows complete healing of the transected ureter and resolution of the uretero-rectal fistula. (f) Retrograde urethrogram during double J stent removal at 1 year showed no leak or ureteric stricture at the site of the previous injury

access was obtained, and contrast injection confirmed total ureteric transection as well as a large uretero-rectal fistula. The length of ureteric disruption was estimated at 1.5 cm at the S2 level. A 9 Fr 35 cm sheath was introduced into the left pelvic collection and a 15 mm gooseneck snare was inserted to capture the retrograde ureteric wire, which was retrieved from the percutaneous sheath to gain a through-and-through access [Figure 1c]. An 8 Fr 26 cm double J stent was retrogradely inserted and successfully deployed. Next, an 8 Fr nephrostomy catheter was inserted for external drainage. During the following days, the urine output from the open wound markedly decreased. At 1-month follow-up, nephrostogram showed remarkable healing of the ureter with interval decrease in the uretero-rectal fistula [Figure 1d]. At 4-month follow-up, there was complete healing of the ureter and resolution of the uretero-rectal fistula [Figure 1e]. The nephrostomy tube was removed, and the double J stent was kept in place to prevent ureteric strictures. Follow-up retrograde urethrograms during double J stent removal showed at 1 year no leak or ureteric stricture at the site of the previous injury [Figure 1f].

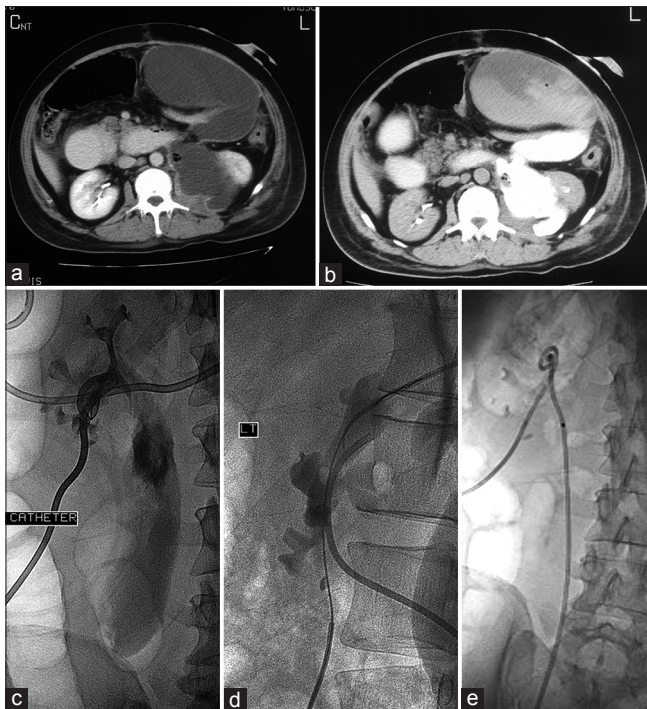
## Case 2

A 55-year-old man who sustained a gunshot injury to the abdomen presented 6 weeks following exploratory laparotomy with increasing abdominal distension. A CT scan of the abdomen revealed a large left perinephric and intraperitoneal fluid collection that showed increased density on the delayed phase due to urine leak from proximal ureteric injury [Figure 2a and b]. Initial diversion nephrostomy was done to alleviate the urine leak. Later, the patient had a cystoscopy with the retrograde placement of a wire into the collection. Through a new upper pole access, a gooseneck snare was used to capture and retrieve the retrograde wire from the collection. An 8 Fr 24 cm double J stent was inserted, and a nephrostomy tube was kept in place for external drainage [Figure 2c-e]. Later, the abdominal collection resolved completely, and the nephrostomy tube was removed. At 1-year follow-up, the double J stent was removed, and the patient required no additional interventions.

## DISCUSSION

Preservation of ureteral integrity is the cornerstone in the management of ureteric fistulas, partial or complete transections. Antegrade or retrograde approaches often succeed in establishing access across the injured ureter allowing for gradual healing after stenting and external drainage.<sup>[2,3]</sup> However, combined approach or so-called rendezvous technique may be necessary to maintain access across the transected ureter and perform antegrade or retrograde stenting. This technique entails advancing a catheter and wire through the ureteric gap to be captured from the opposite access using a snare or forceps under fluoroscopic or cystoscopic visualization.<sup>[2,4-8]</sup>

Recent reports from English literature described endoscopic realignment of ureteric injuries with rendezvous technique using the flexible antegrade scope and rigid retrograde ureteric scope.<sup>[5,6]</sup> In this report, we emphasize few technical points pertaining to the fluoroscopy-guided realignment of total ureteric transection. First, the presence of collection cavity due to urine leak facilitated capturing the retrograde ureteric wire. Therefore, we suggest performing this procedure during the initial placement of diversion nephrostomy, which may lead to the complete obliteration of the cavity and subsequently preclude snaring maneuvers. Second, the antegrade sheath should be advanced into the collection or beyond the edge of the transected ureter. This presumably prevents de-gloving of the ureter during wire retrieval from the antegrade sheath. Similarly, we recommend introducing the tapered end of the double J stent retrogradely into the transnephrostomic sheath, as this



**Figure 2:** Computed tomography scan of the abdomen in early (a) and delayed (b) phases. The late images demonstrate leakage of contrast into the retroperitoneum from the site of injury just below the pelvi-ureteric junction and communicating with a large peritoneal collection. (c) Nephrostogram demonstrates interruption of the proximal ureter with contrast leak into the perinephric collection. (d) Oblique view showing the captured wire by a gooseneck snare into the percutaneously introduced sheath from the upper pole. (e) Double J ureteric stent and nephrostomy catheter in position

may prevent antegrade intussusception of the distal portion of the pelvic ureter into the urinary bladder if the stent is introduced antegradely.

While this technique is minimally invasive and may obviate open surgical repair, it has potential complications. Ureteric intussusception during retrograde introduction of double J stent was described in a previous case reported by Pastore *et al.*<sup>[6]</sup> This was managed by introducing the stent retrogradely. Strictures at the site of ureteric injury are commonly encountered due to the extra-anatomical passage of the stent and intense surrounding fibroblastic

reaction. Nevertheless, these strictures can be managed by ureteroplasty and endoureterotomy.<sup>[6]</sup>

Fluoroscopy-guided realignment using rendezvous technique may offer an alternative approach to salvage the integrity of the ureter and avoid open surgical repair after complex gunshot injuries. More evidence is still required to validate the safety and effectiveness of this technique, particularly in the long-term.

#### Financial support and sponsorship

Nil.

#### Conflicts of interest

There are no conflicts of interest.

#### REFERENCES

1. al-Ali M, Haddad LF. The late treatment of 63 overlooked or complicated ureteral missile injuries: The promise of nephrostomy and role of autotransplantation. *J Urol* 1996;156:1918-21.
2. de Baere T, Roche A, Lagrange C, Denys A, Court B, Isapoff J, *et al.* Combined percutaneous antegrade and cystoscopic retrograde approach in the treatment of distal ureteric fistulae. *Cardiovasc Intervent Radiol* 1995;18:349-52.
3. Lang EK. Antegrade ureteral stenting for dehiscence, strictures, and fistulae. *AJ R Am J Roentgenol* 1984;143:795-801.
4. Gray RJ, Intriere L, Dolmatch BL, Edson M, Fischer J. Combined retrograde-antegrade ureteral stent passage: Salvage procedure for a ureteral leak. *J Vasc Interv Radiol* 1992;3:557-8.
5. Liu C, Zhang X, Xue D, Liu Y, Wang P. Endoscopic realignment in the management of complete transected ureter. *Int Urol Nephrol* 2014;46:335-40.
6. Pastore AL, Palleschi G, Silvestri L, Leto A, Autieri D, Ripoli A, *et al.* Endoscopic rendezvous procedure for ureteral iatrogenic detachment: Report of a case series with long-term outcomes. *J Endourol* 2015;29:415-20.
7. Postoak D, Simon JM, Monga M, Ferral H, Thomas R. Combined percutaneous antegrade and cystoscopic retrograde ureteral stent placement: An alternative technique in cases of ureteral discontinuity. *Urology* 1997;50:113-6.
8. Yates DR, Mehta SS, Spencer PA, Parys BT. Combined antegrade and retrograde endoscopic retroperitoneal bypass of ureteric strictures: A modification of the 'rendezvous' procedure. *BJU Int* 2010;105:992-7.