

CASE REPORT

Tenofovir induced lichenoid drug eruption

Mrinal Gupta, Heena Gupta, Anish Gupta¹

Sudhaa Skin Centre, ¹Acharya Shri Chander College of Medical Sciences, Jammu, Jammu and Kashmir, India

Access this article online

Website: www.avicennajmed.com

DOI: 10.4103/2231-0770.160250

Quick Response Code:



ABSTRACT

Cutaneous adverse reactions are a common complication of anti-retroviral therapy. Tenofovir is a newer anti-retroviral drug belonging to the nucleotide reverse transcriptase inhibitor group. Systemic adverse effects like nausea, vomiting, diarrhea, hepatotoxicity and renal toxicity are common with tenofovir but cutaneous adverse effects are rare. Lichenoid drug eruptions are a common adverse effect seen with a large variety of drugs including antimalarials, antihypertensives, nonsteroidal anti-inflammatory drugs and diuretics. Lichenoid drug eruption is a rare cutaneous adverse effect of tenofovir with only a single case reported till date. Here, we report a case of tenofovir induced lichenoid drug eruption in a 54-year-old human immunodeficiency virus affected male who presented with generalized lichenoid eruption after 6 weeks of initiation of tenofovir and complete clearance on cessation of the drug.

Key words: Cutaneous adverse drug reaction, lichenoid drug eruption, tenofovir

INTRODUCTION

Lichenoid drug eruptions are a common adverse effect seen with inhalation, contact or systemic administration of large variety of drugs including antimalarials, antihypertensives, nonsteroidal anti-inflammatory drugs (NSAIDs), diuretics and gold salts.^[1] Tenofovir is a newer anti-retroviral drug belonging to the nucleotide reverse transcriptase inhibitor group. Systemic adverse effects like nausea, vomiting, hepatotoxicity, renal toxicity are common with tenofovir but cutaneous adverse effects are rarely reported. Lichenoid drug eruption is a rare cutaneous adverse effect of tenofovir with only a single case reported till date.^[2] Herein we report a case of generalized lichenoid drug eruption in a 54-year-old human immunodeficiency virus (HIV) affected male after initiation of tenofovir, which resolved after cessation of the drug.

CASE REPORT

A 54-year-old male, a known case of HIV infection for the last 2 years, presented to us with a 2 weeks history of generalized itchy skin eruption. On evaluating the available records of the patients, it was found that patient had a CD4 count of 326 cells/mm³ and the patient was being managed on a regimen of zidovudine, lamivudine and nevirapine for

the last 8 months but 8 weeks back was shifted to a tenofovir, lamivudine and nevirapine regimen in view of the decreasing haemoglobin levels. Another drug history of the patient included a proton pump inhibitor that he had been taking intermittently for the last 2 years and oral anti-histamines for the eruption. After 6 weeks of initiation of tenofovir, the patient started developing itchy papular eruption that started over the trunk but gradually over the next 3 weeks became generalized and involved the extremities also. On examination, there was a lichenoid eruption involving the trunk and extremities but the face, palms and soles and the mucosae were relatively spared [Figure 1]. There was no associated lymphadenopathy, and the systemic examination was also normal. Laboratory investigations revealed haemoglobin 8 mg/dl and eosinophilia but no lymphopenia or atypical lymphocytes were seen on peripheral blood smear. Liver and renal function tests were within normal limits, as were the chest X-rays and electrocardiography. Skin biopsy was performed which revealed epidermal hyperplasia, focal hypergranulosis, hydropic degeneration of the basement membrane zone and lichenoid lymphocytic infiltrate in the papillary dermis [Figure 2].

A diagnosis of lichenoid drug eruption secondary to tenofovir was made and the patient was started on oral

Address for correspondence: Dr. Mrinal Gupta, Sudhaa Skin Centre, Tawi Vihar, Sidhra - 180 019, Jammu, Jammu and Kashmir, India.
E-mail: drmrinalgupta@yahoo.com

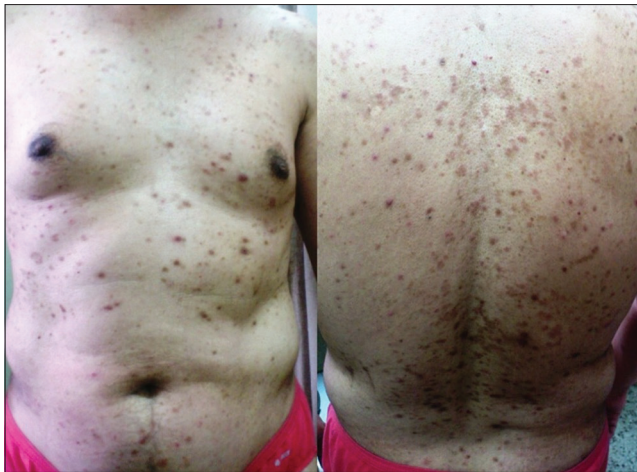

Figure 1: Lichenoid eruption involving the trunk

corticosteroids at a dose of 30 mg/day of prednisolone along with topical corticosteroids (mometasone furoate 0.1% cream twice daily), emollients and oral anti-histamines. Tenofovir was replaced by zidovudine while lamivudine and nevirapine were continued, and the patient was kept under follow-up. After 1-week of cessation of tenofovir and initiation of oral steroids, the lesions had subsided, so the oral steroids were gradually tapered off over the next 3 weeks. At 4 weeks' follow-up, the lesions had cleared completely and only residual hyperpigmentation was left. Re-challenge test was advised but was refused by the patient in view of the generalized nature of eruption.

Discontinuation of tenofovir led to gradual improvement in pigmentation and there was no recurrence of the lichenoid eruption during an 8 months follow-up period.

Causality assessment was carried out using the Naranjo's scale and the World Health Organization-Uppsala Monitoring Centre Criteria after which we came to a conclusion that tenofovir was the "probable" (Naranjo's score 5) cause of this adverse drug reaction.^[3,4]

DISCUSSION

Lichenoid drug eruptions are a common cutaneous adverse effect usually associated with gold, antimalarials, thiazides, sulfonyleurea, heavy metals, anti-tubercular drugs, NSAIDs and phenothiazines etc.^[1] The pathogenesis of lichenoid drug eruptions is thought to be T-cell mediated autoimmune damage to basal keratinocytes that are altered by the drug. Resolution of the rash occurs once these altered keratinocytes are cleared.^[5] Lichenoid drug eruptions usually occur in the elderly with a latent period ranging from a few weeks to a few months. Although the morphology of lichenoid drug eruption resembles lichen planus but certain

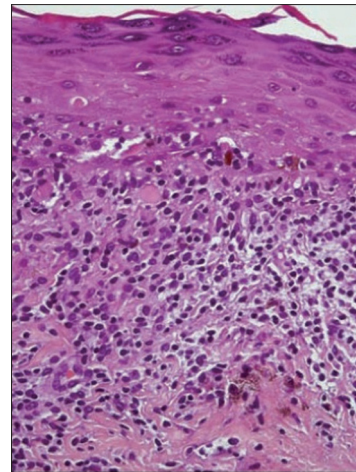


Figure 2: Histopathology showing focal hypergranulosis, hydropic degeneration of the basement membrane zone and lichenoid lymphocytic infiltrate in the papillary dermis

features like sparing of mucosae and nails, the absence of Wickham's striae, photodistribution and a temporal association with drug intake help to differentiate the two. Histologically, all the features of lichen planus can be seen in lichenoid drug eruptions, but some findings are more common in lichenoid drug eruptions that include eosinophilia, focal parakeratosis, colloid bodies at the dermoepidermal junction and exocytosis of lymphoid cells into the upper epidermal layers.^[6,7] Cessation of the causative drug remains the mainstay of the treatment for lichenoid drug eruption. Mild cases may be managed by topical corticosteroids and systemic anti-histamines while in severe cases, administration of systemic corticosteroids may be required.

Tenofovir is a novel nucleotide reverse transcriptase inhibitor which is commonly used as a part of anti-retroviral therapy and is usually used as first line drug in treatment naïve patients. It has a half-life of 14–17 h and is administered in a single daily dose of 300 mg. It is a relatively safe drug, but adverse effects include gastrointestinal disturbance, hepatotoxicity, renal toxicity, pancreatitis, Fanconi's anemia and diabetes insipidus have been reported. Cutaneous adverse effects to tenofovir have been rarely reported with only a few reports of maculopapular rash, urticaria, vesiculo-pustular lesions and tenofovir hypersensitivity syndrome.^[8,9] Lichenoid drug eruption is a rarely described cutaneous adverse effect of tenofovir with only a single case reported till date.^[2]

CONCLUSION

Based on the time–event relationship, morphology, distribution and histopathological findings and the

rapid response on withdrawal of the drug, we conclude that our patient developed a lichenoid drug eruption to tenofovir. As the use of this drug for patients with HIV is increasing, clinicians should be aware of the possibility of lichenoid drug eruption occurring as a rare adverse effect.

REFERENCES

1. Breathnach S. Drug reactions. In: Burns T, Breathnach S, Cox N, Griffiths C, editors. Rook's Textbook of Dermatology. 8th ed., Vol. 4. Oxford: Blackwell Science; 2010. p. 73.1-177.
2. Woolley IJ, Veitch AJ, Harangozo CS, Moyle M, Korman TM. Lichenoid drug eruption to tenofovir in an HIV/hepatitis B virus co-infected patient. *AIDS* 2004;18:1857-8.
3. Naranjo CA, Busto U, Sellers EM, Sandor P, Ruiz I, Roberts EA, *et al.* A method for estimating the probability of adverse drug reactions. *Clin Pharmacol Ther* 1981;30:239-45.
4. The Use of the WHO-UMC System for Standardized Case Causality Assessment [monograph on the Internet]. Uppsala: The Uppsala Monitoring Centre; 2005. Available from: who-umc.org/Graphics/24734.pdf.
5. Majmudar V, Al-Dulaimi H, Dodd H. Lichenoid drug eruption secondary to treatment with nicorandil? *Clin Exp Dermatol* 2008;33:193-4.
6. Cruz MJ, Duarte AF, Baudrier T, Cunha AP, Barreto F, Azevedo F. Lichenoid drug eruption induced by misoprostol. *Contact Dermatitis* 2009;61:240-2.
7. Van den Haute V, Antoine JL, Lachapelle JM. Histopathological discriminant criteria between lichenoid drug eruption and idiopathic lichen planus: Retrospective study on selected samples. *Dermatologica* 1989;179:10-3.
8. Lockhart SM, Rathbun RC, Stephens JR, Baker DL, Drevets DA, Greenfield RA, *et al.* Cutaneous reactions with tenofovir disoproxil fumarate: A report of nine cases. *AIDS* 2007;21:1370-3.
9. Verma R, Vasudevan B, Shankar S, Pragasam V, Suwal B, Venugopal R. First reported case of tenofovir-induced photoallergic reaction. *Indian J Pharmacol* 2012;44:651-3.

Cite this article as: Gupta M, Gupta H, Gupta A. Tenofovir induced lichenoid drug eruption. *Avicenna J Med* 2015;5:95-7.

Source of Support: Nil, **Conflict of Interest:** None declared.

New features on the journal's website

Optimized content for mobile and hand-held devices

HTML pages have been optimized for mobile and other hand-held devices (such as iPad, Kindle, iPod) for faster browsing speed.

Click on [**Mobile Full text**] from Table of Contents page.

This is simple HTML version for faster download on mobiles (if viewed on desktop, it will be automatically redirected to full HTML version)

E-Pub for hand-held devices

EPUB is an open e-book standard recommended by The International Digital Publishing Forum which is designed for reflowable content i.e. the text display can be optimized for a particular display device.


Click on [**EPub**] from Table of Contents page.

There are various e-Pub readers such as for Windows: Digital Editions, OS X: Calibre/Bookworm, iPhone/iPod Touch/iPad: Stanza, and Linux: Calibre/Bookworm.

E-Book for desktop

One can also see the entire issue as printed here in a 'flip book' version on desktops.

Links are available from Current Issue as well as Archives pages.

Click on  View as eBook