

CASE REPORT

Dual Rupture of Non-coronary Sinus of Valsalva Into the Right Heart Chambers

Mahmoud Houmsse

Department of Internal Medicine, Division of Cardiovascular Medicine, The Richard M. Ross Heart Hospital, The Ohio State University Medical Center, Columbus, Ohio, USA

Corresponding author: Mahmoud Houmsse Email: mahmoud.houmsse@osumc.edu

Published: 01 December 2009

Ibnosina Journal of Medicine and Biomedical Sciences 2009, 1(3):97-100

Received: 13 September 2009

Accepted: 02 October 2009

This article is available from: <http://www.ijmbs.org>

This is an Open Access article distributed under the terms of the Creative Commons Attribution 3.0 License

which permits unrestricted use, distribution, and reproduction in any medium, provided the original work is properly cited.

Abstract

Rupture of the non-coronary sinus of Valsalva is a well recognized complication of aortic valve endocarditis. It may result in a hemodynamically significant left to right shunt and biventricular heart failure. We report here the case of a 27-year-old who presented with fever, worsening respiratory distress, chest pain and hemoptysis. The trans-thoracic echocardiography (TTE) revealed aortic valve endocarditis with severe aortic valve regurgitation and dual rupture of the non-coronary sinus of Valsalva into the right heart chambers.

Key words: aortic aneurysm, rupture, Sinus of Valsalva, murmur, vegetation

Introduction

Sinus of Valsalva aneurysms (SOVA) are rare heart anomalies (1-15). SOVA can be either acquired or congenital, most commonly involving the right or non-coronary sinuses. The congenital aneurysms are more common. Causes of acquired aneurysms are usually conditions affecting the aortic wall, which include infections, trauma, or connective tissue disorders. Incidental findings of unruptured aneurysms have

been reported in diagnostic studies (1).

Rupture of the sinus of valsalva (RSOV) is an uncommon condition with a variety of manifestations ranging from an asymptomatic murmur to cardiogenic shock (1, 2, 3, and 15). Rupture of sinus of valsalva is an uncommon complication of infective endocarditis. Early and accurate diagnosis of this complication depends on clinical evaluation including a detailed history and meticulous physical examination, in particular identification of a continuous murmur. Since the standard treatment of the rupture of the sinus of valsalva with hemodynamic instability is surgical intervention, it is important to make the diagnosis as early as possible. Therefore earlier and more accurate diagnosis is a crucial determinant of patient prognosis and outcome.

Case Report

A 27-year-old man developed malaria (*falciparum*) despite malaria prophylaxis during his a trip to West Africa. He was admitted to a local hospital and given intravenous anti-malarial therapy. He was then followed with oral artesunate "anti malarial drug." He felt ill three days after his return from Africa, with a combination of symptoms including worsening shortness of breath, anterior chest pain radiating

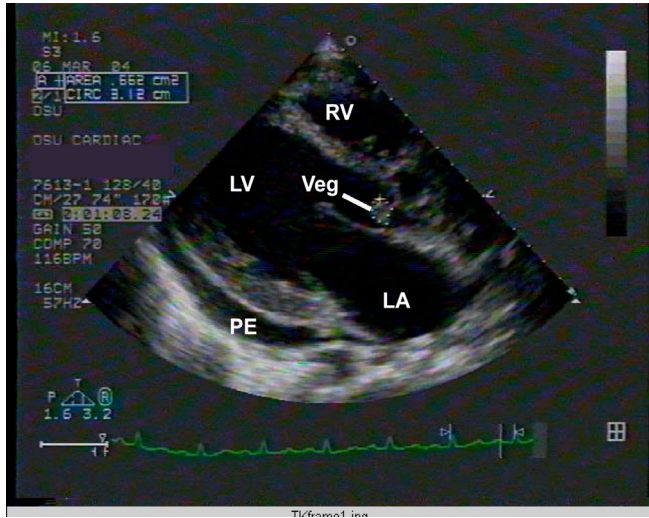


Figure 1: Echocardiographic parasternal long axis view, showing 1.1x1.3 cm vegetation on the non-coronary coronary cusp (NCC). Please note the moderate effusion. (PE: pericardial effusion, LV: left ventricle, LA: left atrium, Veg: vegetation attached to the right coronary cusp of the aortic valve). Notice the normal sinus rhythm on the electrocardiogram.

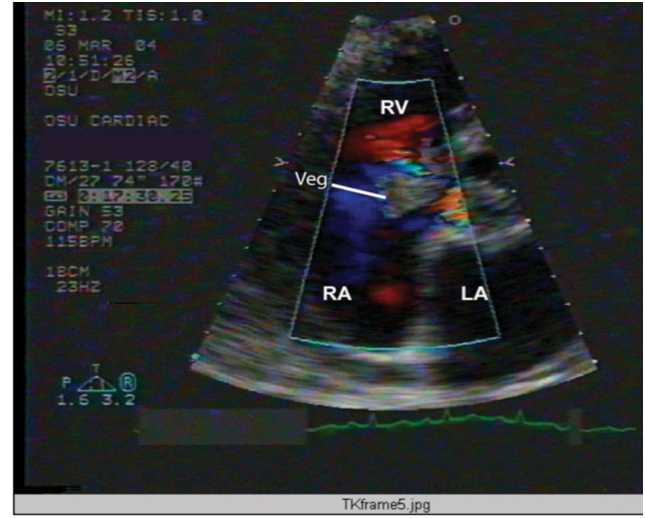


Figure 3: Color Doppler of the echocardiographic parasternal short axis view (as shown in figure 2), showing the two communications between the sinus of Valsalva with the right atrium and ventricle via the dual rupture. Notice the vegetation attached to the base of the septal leaflet of the tricuspid valve, which is bordered with the dual rupture. [Veg: vegetation (thick line), RA: right atrium, RV: right ventricle, LA: left atrium, Aov: Aortic valve]

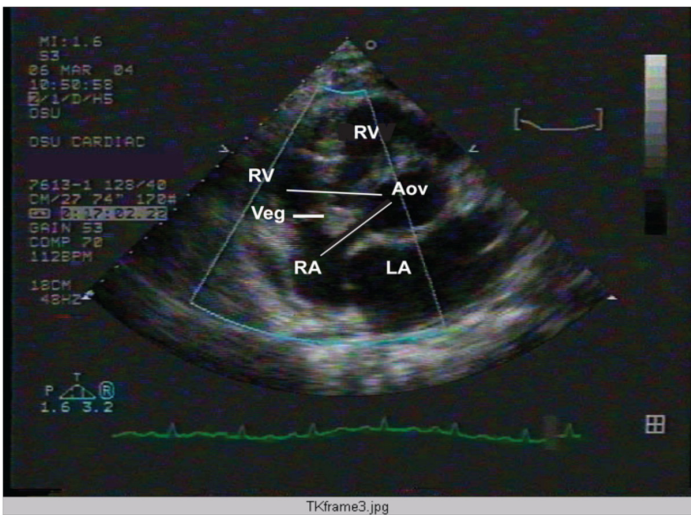


Figure 2: Echocardiographic parasternal short axis view showing a 2x2 cm vegetation, attached to the base of the septal leaflet of the tricuspid valve. [Veg: vegetation (thick line), RA: right atrium, RV: right ventricle, LA: left atrium, Aov: Aortic valve). Notice the two communications between the NCC of Aortic valve and right atrium as well as right ventricle (thin lines). Notice the vegetation attached to the base of the septal leaflet of the tricuspid valve, which is bordered with the dual rupture

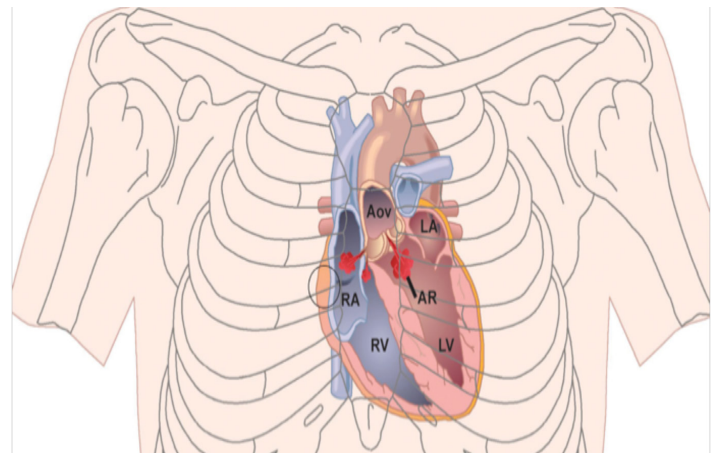


Figure 4: Topographic illustration of the rupture of the sinus of Valsalva to the RV & RA depicted on the thoracic cage. The circle over the right 3rd intercostal space is the area where the continuous murmur is best heard (circle). (LA: left atrium, RA: right atrium, RV: right ventricle, LV: left ventricle, Aov: Aortic valve, AR: Aortic regurgitation)

to the back, palpitations, fevers, poor exercise tolerance, cough, hemoptysis, malaise, nausea, vomiting, myalgias, and headaches. He presented to a local hospital where he received intravenous ceftriaxone, Toradol and IV fluids. He was then transferred to the Infectious Disease Service

at The Ohio State University Medical Center for possible Malaria recurrence or other unusual infectious process. On arrival to the hospital, he was hypoxic with room air pO₂ of 45 mmHg. He was promptly transferred to the Medical Intensive Care Unit (MICU). His dyspnea and

chest pain worsened. In addition, he became apprehensive and fatigued. He denied intravenous drug use, homosexual contact, or unprotected sex. A former smoker, he had quit a month before this. He admitted to alcohol consumption in the past. His family history is positive for asthma and heart disease. His physical exam showed a temperature of 97.3 F, pulse of 120 beat per minute, respiratory rate of 37 breaths per minute, blood pressure of 120/50, and oxygen saturation of 98% on 100% supplemental oxygen. Fundoscopic examination was normal, without any sign of embolic disease. Respiratory effort was moderately labored. Lungs had bilateral crackles in the bases, but these were fairly mild and partially cleared with coughing. He was tachycardic on cardiac exam with a positive heart murmur. It was difficult to determine whether it was a systolic or diastolic murmur with or without a pericardial rub, or both. Diffuse tattoos were noted all over the upper extremities and chest, without splinter hemorrhages in the nail beds.

His EKG showed sinus tachycardia with ST elevation in V2 only. Chest x-ray showed cardiomegaly with a bottle-shaped heart, and atelectasis in both bases. The transaminases and LDH were elevated. Hemoglobin was low at 9; white blood count was elevated at 17,000, with a normal platelet count. The working diagnosis was pulmonary embolism, pericarditis, or recurrent malaria, and infective endocarditis or drug-induced lupus related to the anti-malarial treatment. The echocardiogram showed an enlarged left ventricle (LV) with preserved systolic function (left ventricular ejection fraction 56%); 1.1x1.3 cm vegetation on the non-coronary cusp (NCC) of the aortic valve resulting in severe acute valvular regurgitation; ruptured sinus of valsalva aneurysm of right coronary cusp (RCC) communicating with right atrium (RA) and right ventricle (RV); 2x2 cm vegetation at the base of the septal tricuspid valve leaflet; moderate pericardial effusion; moderate tricuspid valve regurgitation (TR) with TR velocity of 3.5 m/sec and estimated right ventricular systolic pressure of 59 mm/Hg.

He was started empirically on antibiotics, then cardiology, cardiothoracic surgery, and infectious disease consultations were emergently obtained. Thirty-six hours later he underwent aortic root replacement with # 26mm Hancock homograft and re-implantation of the left and right coronaries, debridement of LV outflow tract, RA, RV, and TV; removal of the septal leaflet of TV with pericardial bovine patch of the sinus of valsalva aneurysm of the RCC, repair of the TV with # 36 mm ring. Post procedure, transesophageal echocardiogram (TEE) confirmed no aortic regurgitation (AR), or communication of the sinus of valsalva of RCC and RA or RV.

His vegetation of the tricuspid valve and aortic valve culture revealed polymicrobial organisms of gram-negative rods and gram-positive cocci. Initial as well as later blood cultures continued to be negative for fungus, bacteria, or acid-fast bacilli. His collagen vascular serologies were also negative. His post-operative course was complicated with hypotension requiring intra-aortic counter-pulsation balloon and vasopressor support; acute renal failure secondary to acute tubular necrosis secondary to sepsis; hypotension and a possible embolic event to the renal artery distribution; methacillin resistant staphylococcal aureus (MRSA) pneumonia; failure to wean off ventilator support; and temporary then permanent pacemaker insertion secondary to intermittent complete heart block.

His overall condition slowly improved. The rest of his hospital stay was uneventful. He was discharged to a rehabilitation facility where his condition much improved and subsequently the patient was discharged to home.

Discussion:

Our patient had complicated infective endocarditis with severe acute aortic regurgitation, moderate tricuspid regurgitation, dual RSOV of the right coronary cusp (RCC) to the RA and RV in addition to pericardial effusion. His clinical status and hemodynamics had worsened. The cardiac exam could not confirm a continuous murmur necessary to diagnose the RSOV. Recognition of a continuous murmur will alert the clinician to possible RSOV in the right clinical scenario as in infectious endocarditis. In the absence of this, clinicians are encouraged to utilize transthoracic echocardiogram as an important tool to establish the diagnosis and to rule out the other causes of a continuous murmur.

The clinical presentation of RSOV varies from asymptomatic rupture with continuous murmur to cardiogenic shock. A continuous murmur of ROSV is best heard at the upper right sternal border since the sinus of the right coronary cusp is the common site to rupture (Figure 4). Shah, et al, reported in his ten year retrospective study (1985-95) of 18 patients that 45% of the patients with ROSV presented with an asymptomatic murmur, 20% with acute chest pain, 20% with mild heart failure, 10% with severe heart failure, and 10% with cardiogenic shock (1, 2, 3, 4, 15).

Shah, et al, also revealed that echocardiography has an accuracy of 100% in diagnosing RSOVs since 1990 due to enhanced echocardiographic technical study (15). As noticed in the literature, the accuracy level using transthoracic echocardiogram to diagnose the rupture of the sinus of valsalva and other endocarditis complications is very accurate. Rupture of the right aneurysmal coronary

cuspid (RCC) made up 80-90% while those of the non-coronary cusp (NCC) made up the remainder. Rupture of the left coronary cusp (LCC) is extremely rare (1, 2, 3, and 15). Clinical analysis of RSOV in some studies reveals that the proportion of ruptured aneurysms originating from the RCC and NCC were 80% and 20% respectively, that 70% of aneurysms of SOV ruptured into RV, and 30% into RA (1). Transcatheter device closure of RSOV has been reported in multiple publications (2, 3, 5, 6,) including post coronary artery bypass grafts (CABG) (7) and even aortic valve replacements (AVR) (11). Using advance 3-D echocardiography helped to achieved better transcatheter closure of RSOV (13). In our case, transcatheter closure was not an option due to dual and nearby ruptures as well as the presence of bacterial vegetation and aortic regurgitation. Dual RSOV into RV and RA is rare, and when complicated by endocarditis or hemodynamic compromise, it requires expedient surgical repair for any chance of survival and recovery.

References:

- Feldman DN, Roman MJ. Aneurysm of Sinuses of Valsalva. *Cardiology*. 2006;106:73-81
- Kerker PG. Rupture sinus of Valsalva aneurysm: Yet another hole to plug! *Ann Pediatr Card*. 2009;2:83-4
- Cullen S, Somerville J, Redington A. Transcatheter closure of ruptured aneurysm of sinus of Valsalva. *Br Heart J*. 1994;71:479-80.
- Chu SH, Hung CR, How SS, Chang H, Wang SS, Tsai CH, et al. Ruptured aneurysms of the sinus of Valsalva in Oriental patients. *J Thorac Cardiovasc Surg*. 1990; 99:288-98.
- Arora R, Trehan V, Rangasetty UM, Mukhopadhyay S, Thakur AK, Kalra GS. Transcatheter closure of ruptured sinus of Valsalva aneurysm. *J Interv Cardiol*. 2004; 17:53-8.
- Sen S, Chattopadhyay A, Ray M, Bandopadhyay B. Transcatheter device closure of ruptured sinus of Valsalva: Immediate results and short term follow up. *Ann Pediatr Card*. 2009;2:79-82.
- Kerker P, Suvarna T, Burkule N, Panda R. Transcatheter closure of ruptured sinus of Valsalva aneurysm using the Amplatzer duct occluder in a critically ill post-CABG patient. *J Invasive Cardiol*. 2007;19:E169-71.
- Cui W, van Bergen AH, Patel D, Javois AJ, Roberson DA. Transcatheter closure of ruptured sinus of Valsalva aneurysm and secundum atrial septal defect with limited inferior rim. *Echocardiography*. 2008;25:208-13.
- Fedson S, Jolly N, Lang RM, Hijazi ZM. Percutaneous closure of a ruptured sinus of Valsalva aneurysm using the Amplatzer duct occluder. *Catheter Cardiovasc Interv*. 2003; 58:406-11.
- Cullen S, Vogel M, Deanfield JE, Redington AN. Rupture of aneurysm of the right sinus of Valsalva into the right ventricular outflow tract: Treatment with Amplatzer atrial septal occluder. *Circulation* 2002;105:E1-2.
- Schaeffler R, Sarikouch S, Peuster M. Transcatheter closure of a ruptured sinus of Valsalva aneurysm (RSVA) after aortic valve replacement using the Amplatzer muscular VSD Occluder. *Clin Res Cardiol* . 2007;96:904-6. Epub 2007 Sep 10.
- Rao PS, Bromberg BI, Jureidini SB, Fiore AC. Transcatheter occlusion of ruptured sinus of Valsalva aneurysm: Innovative use of available technology. *Catheter Cardiovasc Interv*. 2003;58:130-4.
- Jean WH, Kang TJ, Liu CM, Chang CW, Tsai SK, Wang JK. Transcatheter occlusion of ruptured sinus of Valsalva aneurysm guided by three-dimensional transesophageal echocardiography. *J Formos Med Assoc*. 2004;103:948-51.
- Murashita T, Kubota T, Kamikubo Y, Shiiya N, Yasuda K. Long-term results of aortic valve regurgitation after repair of ruptured sinus of Valsalva aneurysm. *Ann Thorac Surg*. 2002;73:1466-71.
- Shah RP. Ten- year review of ruptured sinus of Valsalva: Clinico-pathological and echo-Doppler features. *Singapore Med J*. 2001;42(10):473-6.