

CASE REPORT

Rhinocerebral Mucormycosis Complicated by Massive Cerebral Hemorrhage

Fauzia Rashid, Fatheya Faradallah Al Awadi, AlaaEldin M Bashier, Badr A. Gaffar, Rashid Mustafa

Division of Endocrinology, Department of Medicine, Dubai Hospital, Dubai, United Arab Emirates.

Corresponding author: Dr. AlaaEldin Bashier Email: alaaeldin11@gmail.com

Published: 30 September 2012

Ibnosina J Med BS 2012,4(5):192-197

Received: 24 April 2012

Accepted: 27 July 2012

This article is available from: <http://www.ijmbs.org>

This is an Open Access article distributed under the terms of the Creative Commons Attribution 3.0 License, which permits unrestricted use, distribution, and reproduction in any medium, provided the original work is properly cited.

Abstract

Rhinocerebral mucormycosis is a rare but usually fatal infection caused by fungi from the order Mucorales. These fungi has strong predilection for growth into arteries, lymphatics and nerves and this is the reason for their rapid spread to adjacent tissues with accompanying tissue ischemia and infarction due to vascular occlusion after a fibrin reaction and mucor thrombus. We describe a 54 year old Thai national male with poorly controlled type 2 diabetes, ischemic heart disease, hypertension and renal impairment who presented to the emergency department with fever, vomiting and painful left eye swelling, which progressed rapidly leading to complete ophthalmoplegia and vision loss. The diagnosis of mucormycosis was confirmed later and was the patient was started on Amphotericin B therapy. Despite stable clinical course, he suddenly developed a fatal intracerebral hemorrhage and died within 24 hours of the bleed. We wonder weather patients with cerebral fungal infection should perhaps have an early

neurosurgical intervention to rule out the presence of mycotic aneurysm; particularly that many cases of fatal cerebral bleed have been reported in association with Rhinocerebral mucormycosis.

Key words: Rhinocerebral mucormycosis; Diabetes, Cerebral Hemorrhage, Fungal infection.

Introduction

Mucormycosis is the diagnosis used for infection caused by fungi of the order Mucorales (1-4). Mucoraceae may produce severe disease in susceptible individuals, notably patients with diabetes especially in the setting of ketoacidosis, renal failure and malignancy. Rhino-cerebral mucormycosis, the most common form of mucormycosis, is potentially lethal fungal infection characterised by rapid progression and high mortality (5). The disease process begins in the nose, sinuses, or palate. From the sinuses infection can rapidly spread to adjacent tissues or to the orbit and the

brain so early diagnosis and aggressive approach toward management are required to combat this infection. We are not aware of any data on such disease in the Arabian Gulf region, hence this case report and focused review.

Case History

A 54 years old man native of Thailand presented to the emergency department with low grade fever, fatigue, generalized body ache and painful left eye swelling. On the day of admission the patient complained of decreased vision from left eye. On examination, he was conscious, oriented with erythema around the left orbit and chemosis and swelling of the eye. His visual perception was limited to only light with complete left side ophthalmoplegia. His left pupil was dilated with no afferent or efferent light reflex. His right eye was completely normal at that time. No visible nasal discharge or palatal pathology. Our first impression was orbital cellulitis with associated cavernous sinus thrombosis. We asked for ophthalmology advice and obtained an MRI orbit. The ophthalmologist diagnosed him with central retinal artery occlusion, and MRI and MRV showed left sided proptosis with bulky extra-ocular muscles with stranding of the periorbital fat planes. The MRV showed a filling defect in the left transverse sinus there was no evidence of cavernous sinus thrombosis (Figures 1 and 2). A paranasal sinus CT scan showed bilateral maxillary and ethmoidal sinusitis (Figure 3). Three days after admission patient developed a black necrotic patch over his palate (see figure

4). The ENT surgeon found a blackish discharge visible in inferior turbinate from which he took a biopsy. The histopathology confirmed the diagnosis of Mucormycosis (figure 5). The Patient was started on Amphotericin B infusion with closed monitoring of renal function. He made a significant clinical improvement. His fever subsided as well his eye swelling, pain. The ecchymosis started improving, his appetite and general condition got better. On 4th day of treatment patient suddenly became unconscious urgent CT scan done which revealed a big cerebral hemorrhage with midline shift (Figure 6). He was started on supportive care including mannitol infusion neurosurgical team called but he was beyond any surgical intervention, he died within 24 hours of that event.

Discussion

Mucormycosis is almost always seen in patients with immunodeficient states, hemochromatosis, and following major trauma (6). Diabetes mellitus was found to be the underlying medical problem in about 70 % of patients with mucor, and the second most common predisposing factor is underlying renal disease (7). There are no data on the exact prevalence of mucormycosis in the Middle East and North Africa region, but most of the reports on invasive fungal infection have come from Sudan (8). Almost all the reports from Tunisia, Saudi, Iran and Turkey showed association with immune deficiency states, diabetes and major trauma. Einollahi et al. reported a prevalence of invasive fungal

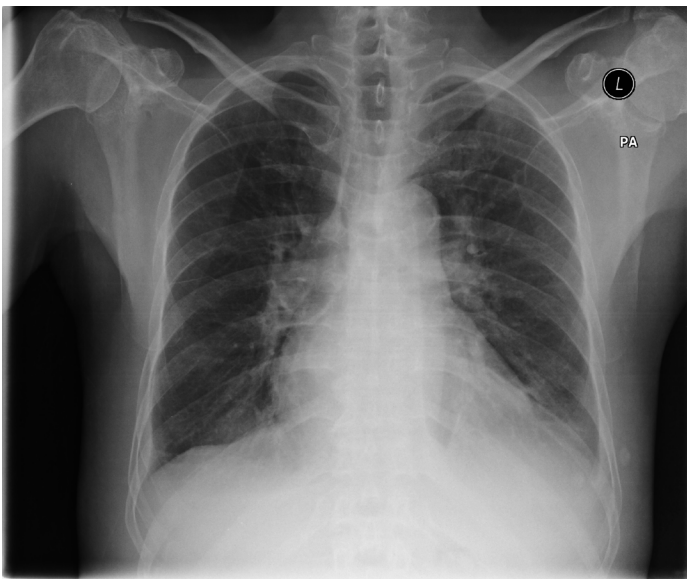


Figure 1. Norma PA Chest X-ray on admission.

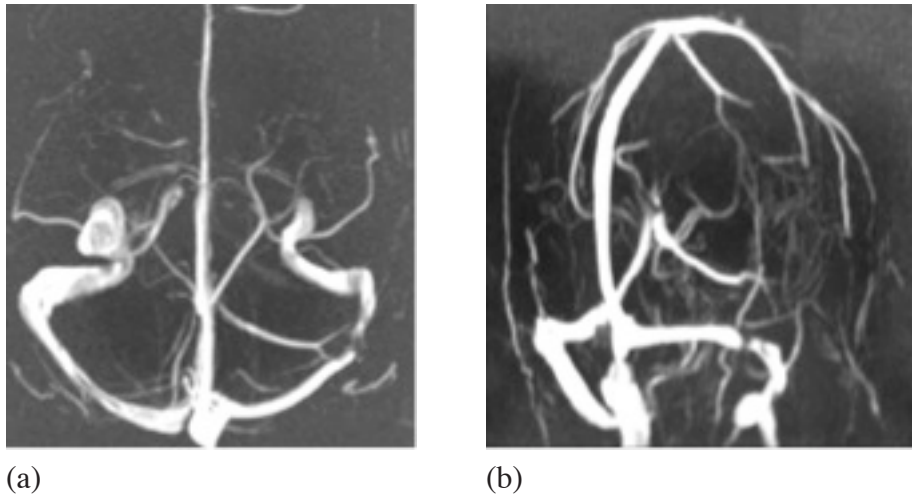


Figure 2. Fig 2 a & b: MR Venogram showing a filling defect in the left transverse sinus corresponding to the area of bleed.

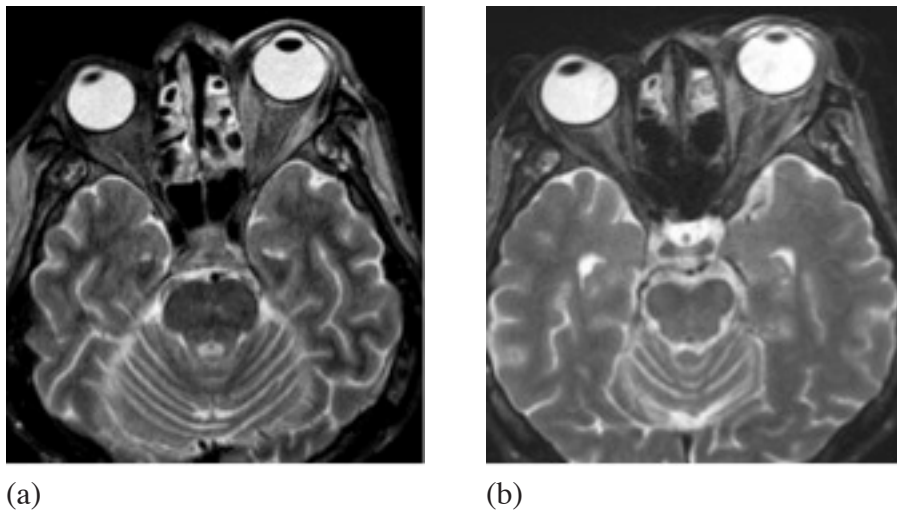


Figure 3. a & b: TSE T2 WI showing left sided proptosis. Note bilateral ethmoidal sinusitis.

infection in renal transplant recipients to be 0.87% (21 out of 2410 renal transplant recipients), mucor mycosis was the most common cause of nvasive fungal infection as it affected of them 11 patients out of 21 transplant recipients (9).

Elinav et al showed that mucormycosis might affect people without previous medical conditions, in their report they described a 78-year-old woman with mucormycosis and no known risk factor; more over review of all English-language publications on mucor involving any site and found 72 more cases. The proportion of patients with mucor without risk factors was found to be 9.1% (6).

Of interest are the reports from Lebanon and Israel that has

shown a seasonal variation in incidence of mucormycosis. In a series of 16 cases seen in a referral hospital in Beirut in the period between 1981-1999, the onset of symptoms has occurred in summer and autumn in 15 out of 16 patients ($p=0.007$) (10). Shpitzer et al. have evaluated the seasonal occurrence of rhino-cerebral mucormycosis in 36 patients from two of Israel's largest medical centres. 58% presented between the months of August and December with a peak 36% in the month of September (11). These findings would suggest the seasonal variations and probably studies to evaluate the atmospheric concentration of mucorales spores in Mediterranean region.

Mucor mycosis may involve different organs. Most of the

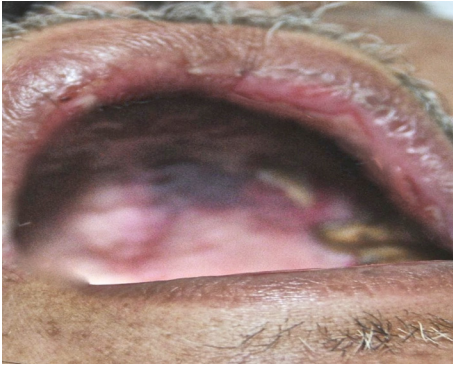


Figure 4. The view of the palate showing the blackish discoloration suggestive of mucor infection.

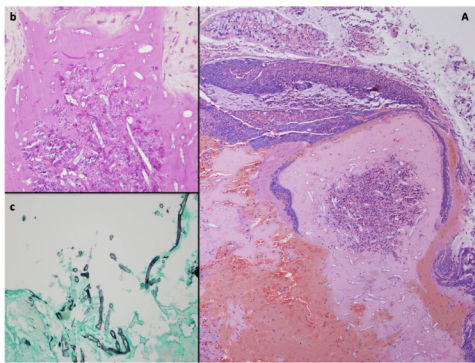


Figure 5. A) A piece of the nasal mucosal tissue with slightly sloughed surface respiratory epithelium and underlying inflamed stromal tissue with granulation tissue which is invaded by broad fungal hyphae (Hematoxylin and Eosin stain, original magnification x100). B) Insets b) and c) show the characteristic broad non-septate right angle branching fungal hyphae (Periodic Acid Schiff (PAS) and Grocott Methenamine Silver (GMS) special stains, respectively, original magnification x400).

reports on mucor have shown typical involvement of the sinuses, skin, lungs, and bone. Al-Rikabi et al. has reported a case of invasive mucormycosis in a benign gastric ulcer. Gastric involvement is more common in patients receiving H₂-receptor blockers (12).

The most common manifestation of this infection is rhinocerebral form which typically present with unilateral headache or facial pain, eye irritation with lacrimation, visual difficulties, nasal congestion, rhinorrhea or epistaxis. on physical examination there may be a purulent nasal discharge with black necrotic material. Black necrotic ulcers can be visible through palate or nasal turbinate. The orbital findings are common in these patients because of ischemic necrosis of orbital cranial nerves from fungal invasion of the orbital blood vessels. The infection can then spread intracranially by two main routes. The first is through the ethmoid sinus and the cribriform plate to frontal lobe

.the second is through the orbital apex directly under the cavernous sinus. In the process these patients can develop the characteristic orbital apex syndrome of ophthalmoplegia which can lead to cavernous sinus thrombosis, internal carotid artery thrombosis, massive stroke, coma and death (13).

The fungal invasion of blood vessels causes a purulent arteritis and thrombosis with resultant ischemia and infarction of tissues. This vasculopathy by mucor has resulted in fatal strokes with different clinical presentation in many reported cases including acute subdural hematoma and massive intracerebral hemorrhage (14), sudden onset parieto-occipital hematoma with later pathological confirmation of invasion of blood vessel wall by mucor in a diabetic patient (15), bilateral basal ganglia bleed (16) and subarachnoid hemorrhage as a result of rupture of mycotic aneurysm (17).

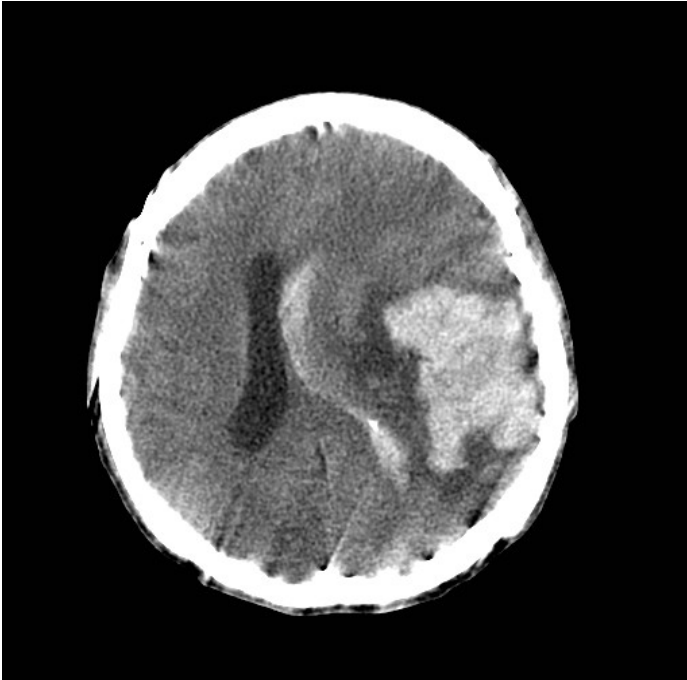


Figure 6. Non-contrast CT scan Brain showing intraparenchymal bleed in the left parieto-occipital region, with perifocal edema, mass effect and midline shift to the right. Extension of the bleed into the ipsilateral ventricle seen.

Einollahi et al. retrospectively collected all kidney transplant recipients in the period between 1990-2010, rhino-cerebral was the commonest form of mucor mycosis as it affected 13 out of 39 transplant recipients, followed by pulmonary (N=7). They reported an over all mortality rates of 52%, with better outcomes in the rhino-cerebral compared to pulmonary (30.8% vs. 100% respectively). Pulmonary infection was linked to the use of use of azathioprine compared to Mycophenolate Mofetil ($p=0.006$) (18).

As for our patient despite he was not considered a suitable candidate for surgical debridement of necrotic tissue because of his underlying heart and renal dysfunction, he made a good clinical progress on medical therapy by amphotericin but the sudden vascular event most likely as a vasculopathic complication of mucor, proved fatal for him. Other investigational treatment approach includes placement of cottonoid pledgets soaked in amphotericin B solution in the nasal cavity. Followed by long-term antifungal therapy. Saedi et al have tested this approach, in thirty patients with rhinocerebral mucormycosis. The overall survival rate was 60 per cent (18 cases); survival rates in the diabetic and malignancy groups were 70.58 and 40 per cent, respectively. The authors have concluded that

this may constitute acceptable management for selected patients, with less morbidity than conventional treatment (19).

In conclusion, mucormycosis is classically described as an acute fulminating infection with a violent and often catastrophic course unless recognised early and managed with aggressive surgical and medical treatment. Intracerebral hemorrhage is a rare but catastrophic outcome of rhinocerebral mucormycosis that may result from mycotic aneurysms. So along with other tomographic investigations, there is a need of early angiographic detection of aneurysm to prevent these aneurysmal rupture by prior embolisation.

References

1. Rinaldi MG. Zygomycosis: Infect Dis Clin North Am. 1989;3(1):19-41.
2. Koçak R, Tetiker T, Koçak M, Baslamisli F, Zorludemir S, Gonlusen G. Fluconazole in the treatment of three cases of mucormycosis. Eur J Clin Microbiol Infect Dis. 1995;14:559-61.
3. Selcen D, Seçmeer G, Aysun S, Kanra G, Onerci M, Gokoz A. et al. Mucormycosis In a diabetic child and its treatment with fluconazole: A case report. Turkish J Pdr. 1995;37:165-8.

4. Maury S, Lebianc T, Feuilhade M, Molina JM, Schaison G. Successful treatment of disseminated mucormycosis with liposomal amphotericin B and surgery in a child with leukemia. *Clin Infect Dis*. 1998;26:200–2.
5. Swartz JC. Rhinocerebral mucormycosis: three case reports and subject review, *J Emerg Med* 1985;3:11-19.
6. Elinav H, Zimhony O, Cohen MJ, Marcovich AL, Bnenson S. Rhinocerebral mucormycosis in patients without predisposing medical conditions: a review of literature. *Clin Microbiol Infect* 2009 Jul;15(7):693-7.
7. Morduchowicz G, Shmueli D, Shapira Z, Cohen SL, Yussmin A, Block CS, et al. Rhinocerebral mucormycosis in renal transplant recipients :Report of three cases and review of the literature. *Rev Infect Dis* 1986;8:441-6.
8. Deshazo RD. Syndromes of invasive fungal sinusitis. *Med mycol*. 2009;47 suppl 1:S309-14.
9. Einollahi B, Lessan-pezeski M, Pourfarziani V, Nemati E, Nafar M, Pour-Reza-Gholi F, Hassan Ghadayani M, Samadian F, Ahmadpoor P, Aslani J. Invasive fungal infections following renal transplantation: a review of 2410 recipients. *Ann Transplant*. 2008;13(4):55-8.
10. Al-Ajam MR, Bizri AR, Mokhbat J, Weedon J, Lutwick L. Mucormycosis in Eastern Mediterranean: a seasonal disease. *Epidiol Infect*. 2006;134(2):341-6.
11. Shpitzer T, Keller N, Wolf M, Goldschmied-Reouen A, Bahar I, Kronenberg J, Feinmesser R, Talmi YP. Seasonal Variations in rhino-cerebral Mucor infection. *Ann Oto Rhinol Laryngol*. 2005;114(9):695-8.
12. Al-Rikabi AC, Al-Dohayan AD, Al-Boukai AA. Invasive mucormycosis in a benign gastric ulcer. *Saudi Med J*. 2000;21(3):287-90.
13. Anaissie EJ, Shakhani AH. Rhinocerebral mucormycosis with internal carotid occlusion: Report of two cases and review of the literature. *Laryngoscope* 1985;95:1107-13.
14. Ho KL. Acute subdural hematoma and intracerebral hemorrhage: rare complication of Rhinocerebral mucormycosis. *Arch Otolaryngol* 1979;105(5):279-81.
15. Oliveira V, Costa A. Cerebral hematoma caused by mucormycosis. *Rev Neurol* 2001;33(10):951-53.
16. Ashok V. Bilateral basal ganglionic hemorrhage: *Arch Neurol* 2006;63:464.
17. Peterus T, Thajeb T, Dai D. Fatal strokes in patients with rhinocerebral mucormycosis and associated vasculopathy . *Scand. J. Infect. Dis*. 2004; 36(9):643-8.
18. Einollahi B, Lessan-pezeski M, Aslani J, Nemati E, Rostami Z, Hosseini MJ, Ghadiani MH et al. two decades of experience in mucormycosis after kidney transplantation. *Ann Transplant* 2011;16(3):44-8.
19. Saedi B, Sadeghi M, Seilani P. endoscopic management of rhinocerebral mucormycosis with topical and intravenous amphotericin B. *J Laryngol Otol*. 2011;125(8):807-10.