

CASE REPORT

Primary Central Nervous System Lymphoma in Acquired Immunodeficiency Syndrome Patient

Rajaie A. Namas, Jegede Olugbemiga, Imran Shafique, Wihib Gebregeorgis, Saqib Hasan, Mohamad El Mortada, Gurkan Ege*, Ghassan Bachuwa

Department of Internal Medicine, Hurley Medical Center, Michigan State University, Flint, MI 48503

*Department of Radiology, Michigan State University, Flint, MI 48503

Corresponding author: Dr. Rajaie A. Namas Email: rnamas1@hurleymc.com

Published: 04 April 2012

Ibnosina J Med BS 2012,4(2):53-59

Received: 09 October 2011

Accepted: 08 February 2012

This article is available from: <http://www.ijmbs.org>

This is an Open Access article distributed under the terms of the Creative Commons Attribution 3.0 License which permits unrestricted use, distribution, and reproduction in any medium, provided the original work is properly cited.

Abstract

Primary central nervous system lymphoma (PCNSL) is a rare form of non-Hodgkins lymphoma of the central nervous system and eye. It is over 1000 times greater in HIV positive than in non-HIV populations. The decline in its incidence since the introduction of the highly active anti-retroviral therapy (HAART) suggests an association of this tumor with severe and prolonged immunosuppression. Clinical presentation results from neurological deficits related to the site of the tumor. Systemic B symptoms are also common. The detection of EBV DNA from the CSF, by nested PCR, is a highly sensitive and specific for HIV-related PCNSL. We present the case of a 31-year-old African American man with medical history significant for AIDS who presented with one-month history of lack of energy and somnolence. CSF appearance was normal. MRI suggested primary CNS lymphomas or toxoplasmosis. CSF EBV DNA by PCR was found to be positive. The clinical presentation of PCNSL is similar to that of toxoplasmosis

encephalitis in patients diagnosed with HIV. The initial differentiation between the two pathologies on presentation is important since treatment differs and early treatment has been shown to reduce mortality.

Key words: CNS lymphoma; AIDS; HIV; Primary CNS lymphoma

Abbreviations

HIV (Human immunodeficiency virus), AIDS (Acquired immune deficiency syndrome), WBC (White blood cells), PCR (polymerase chain reaction), Highly Active Antiretroviral Therapy (HAART), Primary central nervous system lymphomas (PCNSLs), central nervous system (CNS), Body Mass Index (BMI), Trimethoprim-sulfamethoxazole (TMP/SMX), Herpes Simplex Virus (HSV), Cytomegalovirus (CMV), Whole-brain radiation therapy (WBRT), EBV (Epstein-Bar Virus)

Introduction

Primary central nervous system lymphoma (PCNSL), an aggressive, malignant high grade B cell neoplasm, is a rare form of non-Hodgkins lymphoma of the central nervous system and eye, and accounts for 1% of all intracranial tumors and 4-7% of primary brain tumors. PCNSL accounts for 15% of HIV-associated lymphomas. Its reported incidence in HIV population is over 1000 times greater than in the non-HIV population (1). There has been a decline in its incidence since highly active anti-retroviral therapy (HAART) introduction (2), which would confirm the strong association of this tumor with severe and prolonged immunosuppression. Clinical presentation results from neurological deficits related to the site of the tumor, with mental state disturbance and seizures more common than in non-HIV PCNSL. Systemic B symptoms are also common (3). The detection of EBV DNA from the CSF by nested PCR is an extremely sensitive (100%) and specific (98.4%) diagnostic investigation for HIV-related PCNSL (4). The positive predictive value of CSF PCR for EBV for establishing the diagnosis of PCNSL was only 29% and specificity, 79.1% (5).

In recent years, the management of human immunodeficiency virus (HIV) positive individuals has been based on highly active antiretroviral therapy (HAART) comprising a combination of nucleoside analogue reverse transcriptase inhibitors and at least one protease inhibitor and/or one non-nucleoside analogue reverse transcriptase inhibitor (6-8). Introduction of HAART in the mid-1990s, has been accompanied by a reduction in the frequency of many of the secondary events caused by HIV infection and has led to a marked decline in the incidence of most AIDS-associated illnesses (9).

Primary central nervous system lymphomas (PCNSLs) are extranodal malignant lymphomas arising within the brain, eyes, leptomeninges, or spinal cord in the absence of systemic lymphoma at the time of diagnosis (10). It is an aggressive, malignant high grade B cell neoplasm and is a rare form of non-Hodgkins lymphoma which accounts for 1% of all intracranial tumors (11) and 4-7% of primary brain tumors.

Detection of EBV DNA in cerebrospinal fluid (CSF) by polymerase chain reaction (PCR) has been demonstrated to be a good marker of PCNSL

Case History

A 31-year-old African American man living in Flint, Michigan with medical history significant for AIDS presented to Emergency Department (ED) in June of 2010

with one month history of lack of energy and somnolence. He was brought to the ED by his father who was concerned about his altered behavior of sleeping all day and being withdrawn. Review of other systems elicited generalized weakness, easy fatigability, memory lapses and depressed mood. He denied any weight loss, fever, photophobia, headaches, slurring of speech, upper and lower extremity weakness, loss of consciousness or seizure activity

The patient was diagnosed with HIV/AIDS in November 2004 when he developed pneumocystis jirovecii pneumonia. His absolute CD4 count at that time was 20 with an HIV viral load of 180,000 copies/ml. He was started on highly active anti-retroviral therapy (HAART) and trimethoprim /sulfamethoxazole daily. He was compliant with his medications till 2005 when his absolute CD4 count increased to 260. He then stopped taking all medications and was lost to follow-up and did not seek medical advice. He did not smoke cigarettes or drink alcohol. He denied use of recreational drugs. He was working as a college instructor weeks before this admission. He reported being heterosexual.

On physical examination, the patient appeared somnolent, lying in bed with his eyes closed. He was oriented to time, place and person. His vital signs on arrival to the ED were: blood pressure: 121/49 mmHg, respiratory rate: 16 breaths pm, pulse: 99 beats pm, temperature: 38°C, oxygen saturation of 97% in room air. His weight was 90kg and BMI: 27.5kg/m².

Ocular examination showed pupils were equally reactive to light and accommodation with intact extra ocular movements. No visual field defects or nystagmus were elicited. No lymphadenopathy was noted. Pseudofolliculitis barbae was noticed in beard area. Rest of the physical exam was essentially normal.

Laboratory findings on admission showed WBC of 1.9 X1000, Neutrophil Abs 1.2%, neutrophils 58%, lymphocytes 28%, Monocytes 11%, Bands 3%, Segments 45%. Hgb 16.1 g/dl, hct 48.4%, MCV 82.9 fl, Plt 166 X1000. Lymphocyte studies showed a CD4 percent < 4% and CD4 absolute < 5.

Lumbar puncture was performed and CSF appearance was clear, colorless with WBC count 6/cumm, Mono 50%, Poly 50%, and RBC count 37. CSF smear was negative and the protein and glucose concentration was normal. Toxoplasmosis serology was pending.

CT scan of the head with and without contrast was normal. MRI brain showed an area of signal abnormality with enhancement in the region of the anterior corpus

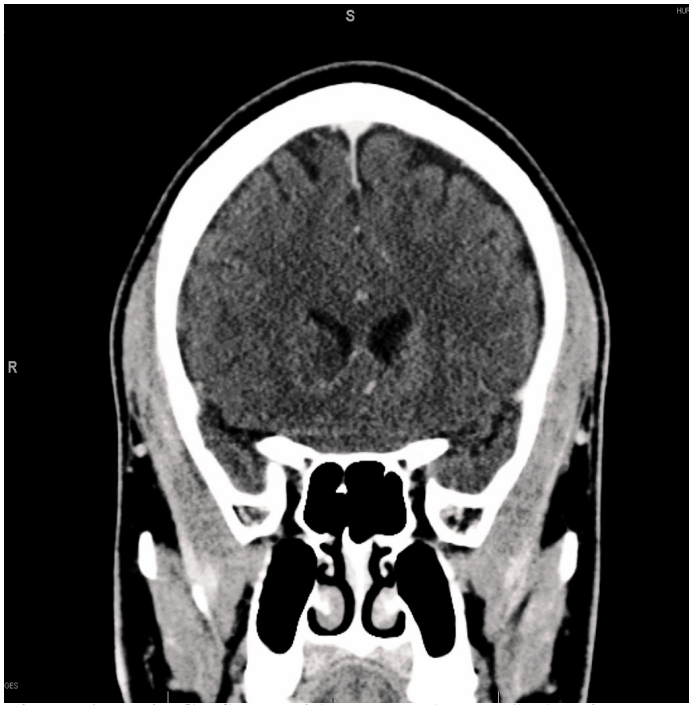

Figure 1. Brain CT-Scan with contrast (coronal) showing mass-like heterogeneous enhancement in the right caudate nucleus with mild extension to the periventricular white matter.

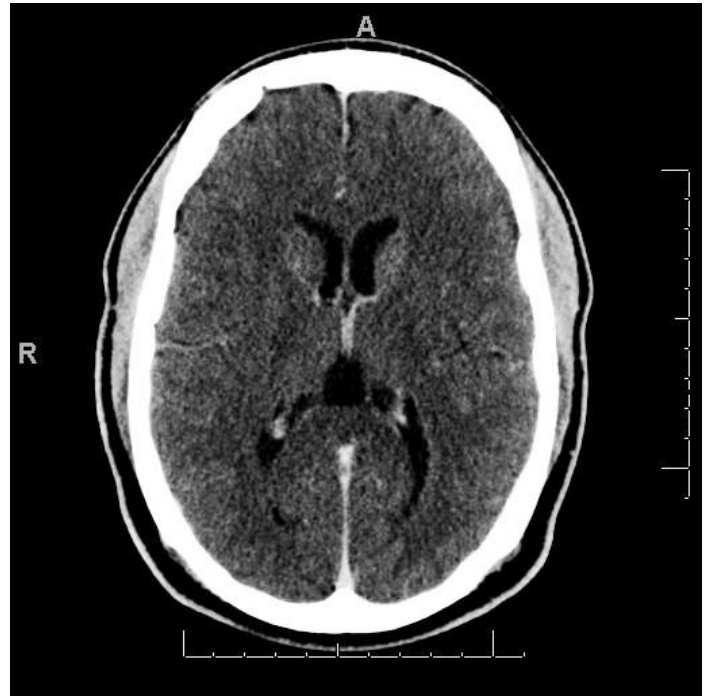


Figure 2. Brain CT-Scan with contrast showing mass-like heterogeneous enhancement in the right caudate nucleus.

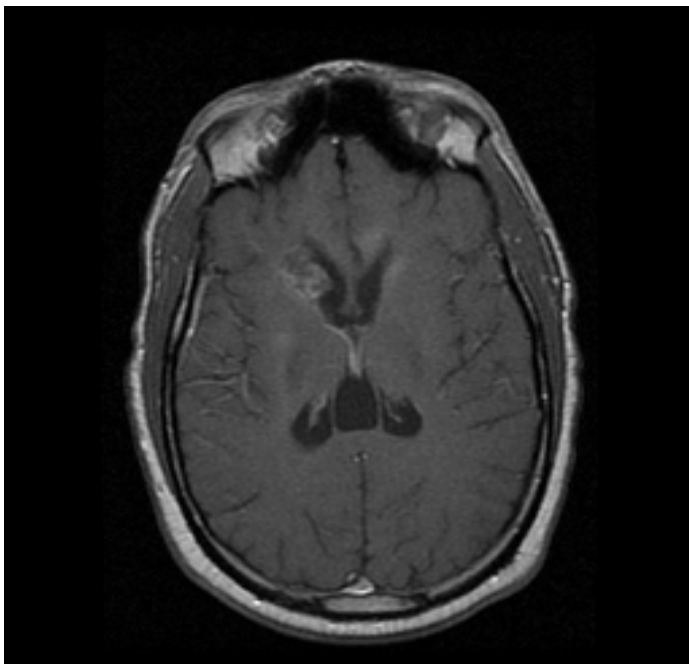


Figure 3. Brain MRI (T1 axial image post gadolinium) showing mass-like heterogeneous enhancement involving the right caudate nucleus.

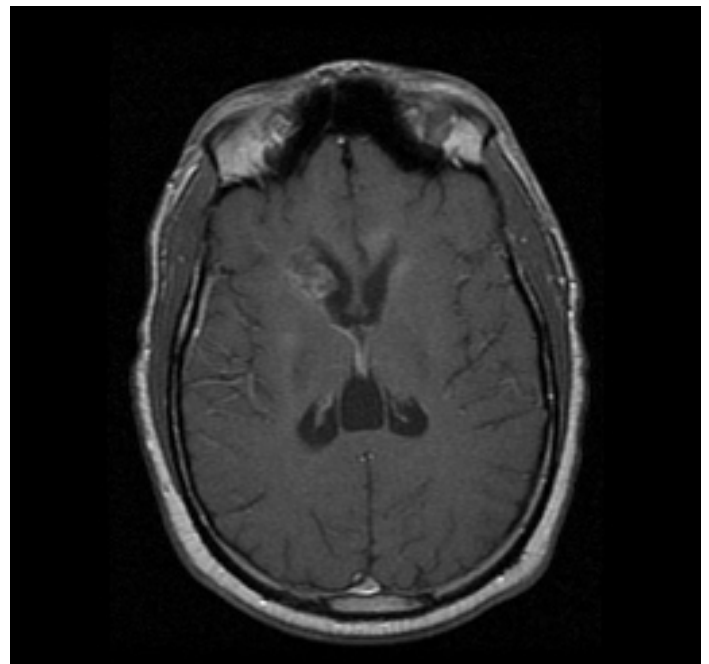


Figure 4. Brain MRI (T1 axial image post gadolinium) showing heterogeneous enhancement involving the right caudate nucleus and the genu of the corpus callosum with extension to periventricular white matter. Also, a linear enhancement is seen along ependymal lining of the right lateral ventricle.

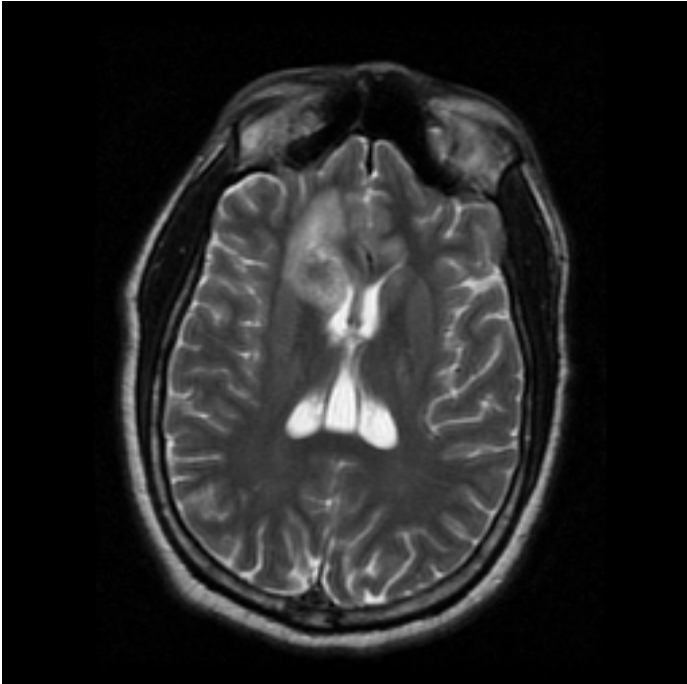


Figure 5. Brain MRI (T2 axial image) showing mass-like abnormal signal changes in right caudate nucleus, the right genu of the corpus callosum and periventricular white matter.

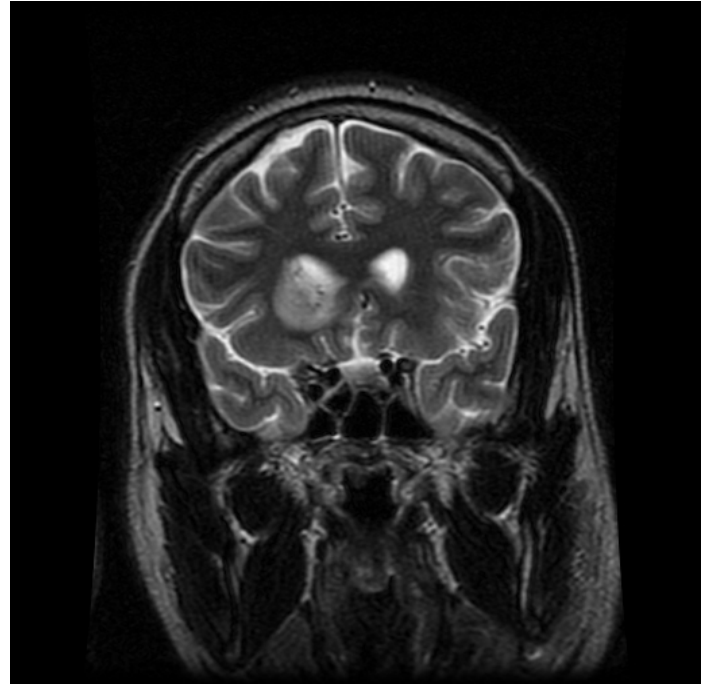


Figure 6. Brain MRI (T2 coronal image) showing a mass-like abnormal signal changes in the right caudate nucleus with extension to adjacent periventricular white matter .

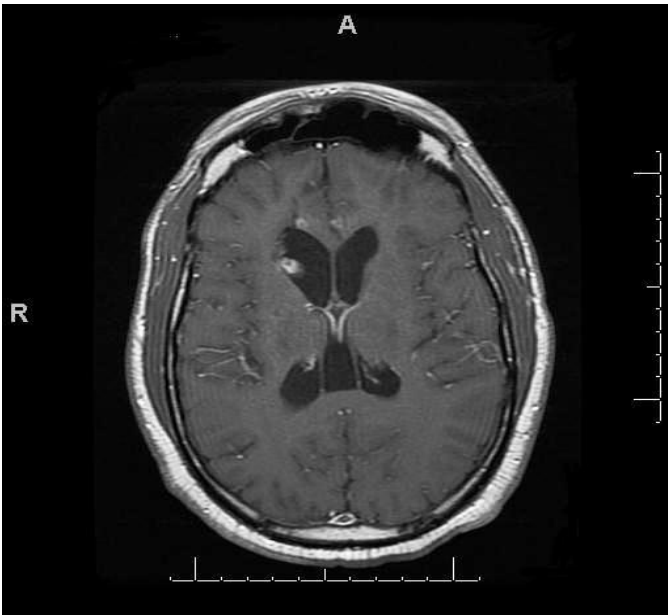


Figure 7. Brain MRI Post treatment with WBRT (T1 axial image post gadolinium) showing small foci of heterogeneous enhancement involving the right caudate nucleus and the right genu of the corpus callosum. In comparison to prior study, significant improvement is seen.

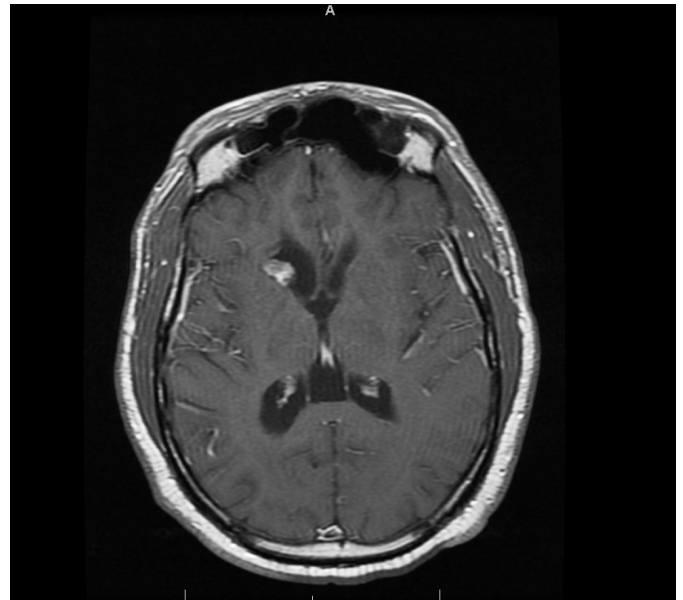


Figure 8. Brain MRI Post treatment with WBRT (T1 axial image post gadolinium) showing mass-like heterogeneous enhancement involving the right caudate nucleus. Previously seen a linear enhancement along ependymal lining of the right lateral ventricle is no longer available on post treatment image .

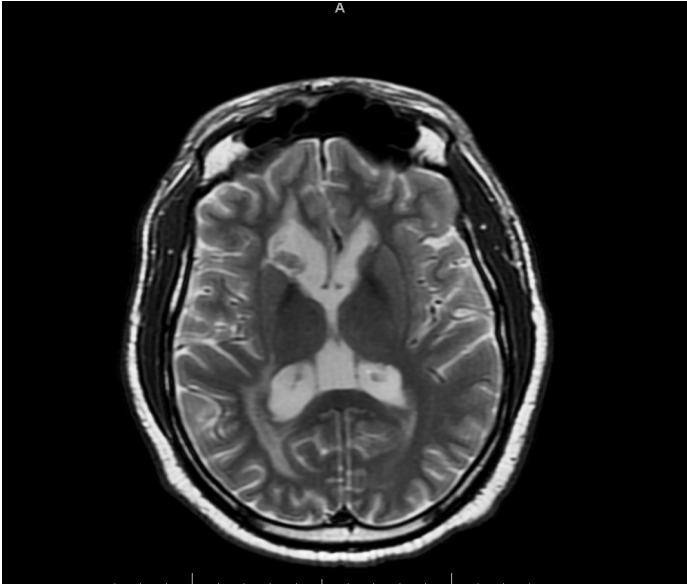


Figure 9. Brain MRI Post treatment with WBRT (T2 axial image) showing abnormal signal changes in right caudate nucleus, the right genu of the corpus callosum and periventricular white matter, which are significantly improved since prior study and smaller in size. Additionally, mild dilatation of the right frontal horn is noted.

collosum, right side more prominent than the left and in the region of the right greater than the left caudate nucleus with intraventricular extension of enhancement along the ependymal lining. Findings suggested PCNSL versus toxoplasmosis. These lesions were inaccessible for stereotactic brain biopsy (Per neurosurgery the lesions were in the basal ganglia in addition the patient and family refused the procedure). Patient was empirically started on pyrimethamine and sulfadiazine pending toxoplasma serology. He was also given weekly azithromycin for mycobacterium avium complex prophylaxis. A thallium-201 single-photon emission computed tomography (^{201}Tl SPECT) scan may be useful in distinguishing between lymphoma and toxoplasmosis in this case. Increased ^{201}Tl uptake co-localizing with the lesion on MRI is highly specific for primary CNS lymphoma¹². It was not done in this patient because EBV DNA by PCR was found to be positive.

Treatments for toxoplasmosis was stopped after IGM and IGG antibodies were reported to be negative. Cryptococcal antigen in serum was negative as well. CSF cryptococcal antigen was negative and VDRL was non-reactive. Urine histoplasma antigen was negative. CSF cytology was negative and cultures were negative with no fungal elements seen. CSF was tested for HSV and CMV by PCR

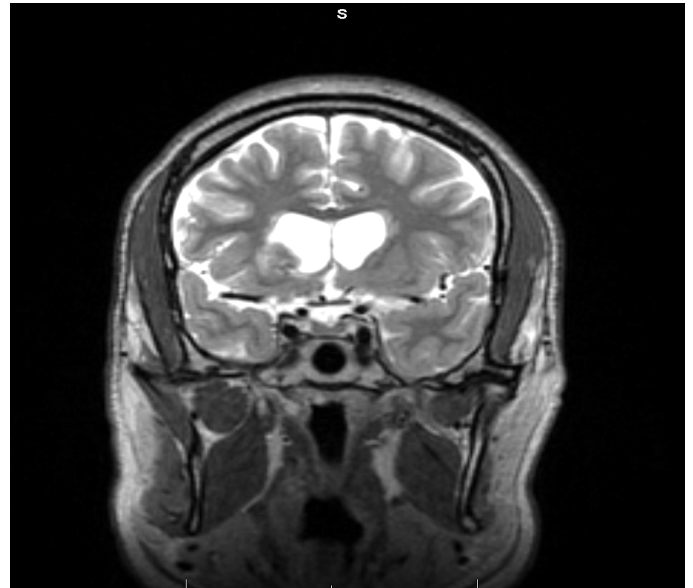


Figure 10. Brain MRI Post treatment with WBRT (T2 coronal image) showing abnormal signal changes in right caudate nucleus and periventricular white matter are markedly improved after the treatment.

which was found to be negative .CSF EBV DNA by PCR was found to be positive. Patient was evaluated by medical and radiation oncology.

CT scan of chest, abdomen and pelvis done as part of metastatic workup did not showed enlarged lymph nodes in the mediastinum, hila, abdomen and pelvis. MRI of the cervical, thoracic and lumbar spine showed the bone marrow signal to be normal with no evidence of metastasis. Doppler Ultrasound of the scrotum and testicles was unremarkable. Patient was started on tenofovir, emtricitabine and efavirenz as well as whole-brain radiation therapy (WBRT). Patient had subsequent follow-up as an outpatient after receiving 15 cycles of radiotherapy after 1 month of being discharged from the hospital. He stated that he was feeling better and denied any neurological complaints. He was compliant with tenofovir, emtricitabine and efavirenz, Azithromycin 1200mg PO weekly and TMP/SMX PO. He had an intact memory, and was oriented to time, place and person. Vital signs within normal range. His weight was 100kg. Vision and hearing were intact. Neurological examination was noted to be normal. HIV-1 RNA viral load was undetectable and absolute CD4 count was 44.

Patient was doing well at 3 month follow-up after he had finished 25 sessions of WBRT.

Discussion

PCNSL occurs in patients who have advanced AIDS with CD4 lymphocyte counts below 50/mm³ (9,13). Since the introduction of HAART, PCNSL has also been reported in individuals with CD4+ T cell counts over 200/ μ l or even over 500/ μ l.

The clinical presentation of PCNSL is similar to that of toxoplasmosis encephalitis in patients with HIV. The initial differentiation between the two pathologies is important since treatment differs and early treatment has been shown to reduce mortality. Staging is not indicated in patients with PCNSL as almost always this disorder remains confined to the central nervous system, but within the space may spread to all compartments including the leptomeninges, spinal cord and eyes. The tumor appears on MRI as a unique contrast-enhancing lesion in the majority of immunocompetent patients. WBRT is recommended based on the microscopically diffuse nature of PCNSL (10).

PCNSL is a highly radiosensitive and chemosensitive infiltrative tumor, and surgery is therefore restricted to diagnostic biopsy. Stereotactic brain biopsy is the most appropriate method for diagnosis of PCNSL. In this case we had the opportunity to use CSF PCR assay for EBV which is a useful non invasive means for diagnosis of PCNSL (14).

The standard first line therapy for AIDS- related PCNSL is WBRT and corticosteroids which achieves complete response in 20-50% of patients (15).

Despite a high rate of response, WBRT alone provides limited survival benefit in PCNSL patients, with median overall survival (OS) duration of 10–18 months and a 5-year survival rate less than 5% (16). The only phase II trial, conducted by the Radiation Therapy Oncology Group (RTOG), which delivered a total dose of 40 Gy with an additional 20-Gy boost to contrast-enhancing lesions, reported an 11.6-month OS time (17). These disappointing results have led to the use of chemotherapy in combination with whole-brain radiotherapy. In the last decade multiple phase II studies have shown that addition of high-dose methotrexate (MTX)-based chemotherapy to WBRT results in a substantially longer survival time than with WBRT alone (median survival time, 2– 4 years; 5-year survival rate, 20%– 40%) (18-20) and are associated with a radiographic response in more than 50% of patients (21). While the overall response rate reported in these studies is encouraging, still high frequency of treatment-related toxic effects is a significant concern.

This patient was on WBRT with corticosteroids. Patient

was offered high-dose methotrexate (MTX)-based chemotherapy but he refused to receive the treatment.

In conclusion PCNSL is an important cause of intracranial mass lesion in AIDS. Its clinical and radiological presentation is similar to toxoplasmosis. CSF for EBV DNA is positive in most patients with PCNSL. Cranial radiation helps prevent further neurological deterioration and methotrexate may be used as part of the management. All patients should be started on HAART, which leads to immune recovery and improved survival (22).

References

1. Flinn IW, Ambinder RF. AIDS primary central nervous system lymphoma. *Curr Opin Oncol* 1996;8:373-6.
2. Besson C, Goubar A, Gabarre J, Rozenbaum W, Pialoux G, Châtelet FP, *et al.* Changes in AIDS-related lymphoma since the era of highly active antiretroviral therapy. *Blood* 2001;98:2339-44.
3. Racz LE, Patel P, Feun L, Restrepo A, Raub WA, Jr., Cassileth PA. Natural history and prognostic factors for survival in patients with acquired immune deficiency syndrome (AIDS)-related primary central nervous system lymphoma (PCNSL). *Crit Rev Oncog* 1998;9:199-208.
4. Al-Shahi R, Bower M, Nelson MR, Gazzard BG. Cerebrospinal fluid Epstein-Barr virus detection preceding HIV-associated primary central nervous system lymphoma by 17 months. *J Neurol* 2000;247:471-2.
5. Ivers LC, Kim AY, Sax PE. Predictive value of polymerase chain reaction of cerebrospinal fluid for detection of Epstein-Barr virus to establish the diagnosis of HIV-related primary central nervous system lymphoma. *Clin Infect Dis* 2004;38:1629-32.
6. Schmidt-Westhausen AM, Pripke F, Bergmann FJ, Reichart PA. Decline in the rate of oral opportunistic infections following introduction of highly active antiretroviral therapy. *J Oral Pathol Med* 2000;29:336-41.
7. Gerald L.Mandell MD MACP, John E.Bennett MD, and Raphael Dolin MD. Mandell, Douglas, and Bennett's Principles & Practice of Infectious Diseases. Expert Consult Premium Edition - Enhanced Online Features and Print (Two Volume Set). 2011.
8. <http://www.aidsinfo.nih.gov/>
9. Grulich AE, Li Y, McDonald AM, Correll PK, Law

- MG, Kaldor JM. Decreasing rates of Kaposi's sarcoma and non-Hodgkin's lymphoma in the era of potent combination anti-retroviral therapy. *AIDS* 2001;15:629-33.
10. Sierra Del RM, Rousseau A, Soussain C, Ricard D, Hoang-Xuan K. Primary CNS lymphoma in immunocompetent patients. *Oncologist* 2009;14(5):526-39.
 11. Shah GD, DeAngelis LM. Treatment of primary central nervous system lymphoma. *Hematol Oncol Clin North Am* 2005;19:611-27, v.
 12. Miller RF, Hall-Craggs MA, Costa DC, N S Brink, F Scaravilli, S B Lucas, *et al.* Magnetic resonance imaging, thallium-201 SPET scanning, and laboratory analyses for discrimination of cerebral lymphoma and toxoplasmosis in AIDS. *Sex Transm Infect* 1998;74:258-64.
 13. Deangelis LM. Primary central nervous system lymphoma: coming or going? *Blood* 2009;113:4483-4.
 14. Cinque P, Brytting M, Vago L, Castagna A, Parravicini C, Zanchetta N, *et al.* Epstein-Barr virus DNA in cerebrospinal fluid from patients with AIDS-related primary lymphoma of the central nervous system. *Lancet* 1993;342:398-401.
 15. Hull AE. Does ARV therapy reduce incidence of non-Hodgkin lymphoma? *HIV Clin* 2009;21:6-8.
 16. Bessell EM, Hoang-Xuan K, Ferreri AJ, Reni M. Primary central nervous system lymphoma: biological aspects and controversies in management. *Eur J Cancer* 2007;43:1141-52.
 17. Nelson DF, Martz KL, Bonner H, Nelson JS, Newall J, Kerman HD, *et al.* Non-Hodgkin's lymphoma of the brain: can high dose, large volume radiation therapy improve survival? Report on a prospective trial by the Radiation Therapy Oncology Group (RTOG): RTOG 8315. *Int J Radiat Oncol Biol Phys* 1992;23:9-17.
 18. Gabbai AA, Hochberg FH, Linggood RM, Bashir R, Hottleman K. High-dose methotrexate for non-AIDS primary central nervous system lymphoma. Report of 13 cases. *J Neurosurg* 1989;70:190-4.
 19. Deangelis LM, Yahalom J, Thaler HT, Kher U. Combined modality therapy for primary CNS lymphoma. *J Clin Oncol* 1992;10:635-43.
 20. Glass J, Shustik C, Hochberg FH, Cher L, Gruber ML. Therapy of primary central nervous system lymphoma with pre-irradiation methotrexate, cyclophosphamide, doxorubicin, vincristine, and dexamethasone (MCHOD). *J Neurooncol* 1996;30:257-65.
 21. Ferreri AJ, Abrey LE, Blay JY, Jean-Yves Blay, Bettina Borisch, Jacob Hochman, *et al.* Summary statement on primary central nervous system lymphomas from the Eighth International Conference on Malignant Lymphoma, Lugano, Switzerland, June 12 to 15, 2002. *J Clin Oncol* 2003;21:2407-14.
 22. Skiest DJ, Crosby C. Survival is prolonged by highly active antiretroviral therapy in AIDS patients with primary central nervous system lymphoma. *AIDS* 2003;17:1787-93.