

CASE REPORT

Osteolysis of the Hips in a Patient with Long Term Rheumatoid Arthritis

Rajaie Namas^{1,2}, Harpreet Sagar², Ghassan Bachuwa¹, Frank Vasey²

¹Department of Internal Medicine, Hurley Medical Center, Michigan State University, Flint, Michigan, United States

²Division of Rheumatology, Wayne State University, Detroit, Michigan, United states.

Corresponding author: Dr Rajaie Namas Email: rnamas@med.wayne.edu

Published: 01 March 2013

Ibnosina J Med BS 2013,5(2):93-98

Received: 23 August 2012

Accepted: 31 August 2012

This article is available from: <http://www.ijmbs.org>

This is an Open Access article distributed under the terms of the Creative Commons Attribution 3.0 License, which permits unrestricted use, distribution, and reproduction in any medium, provided the original work is properly cited.

Abstract

Case presentation: A fifty four year old African American female with history of rheumatoid arthritis (RA) presented to the emergency room with signs and symptoms of community acquired pneumonia. Patient was diagnosed with RA 30 years ago and was treated initially with non-steroidal anti-inflammatory drugs (NSAIDs), corticosteroids and gold injections for 3 months since then she didn't receive any disease modifying anti rheumatic drugs (DMARD) or corticosteroids. On examination, she was wheelchair bound with multiple joint deformities: ulnar deviation, swan neck deformities, without any signs of active synovitis. Rheumatoid nodules were absent. She had severe limitation of passive and active movement of the hip joints bilaterally. Images of the pelvis showed resorption of the femoral (1). Marked subchondral sclerosis was noted in the acetabulum. CT scan of the pelvis was done to rule out subcapital femoral neck fracture. It demonstrated advanced degenerative changes in both hip

joints with partial resorption of both femoral heads worse on the left, no fracture was noted. **Conclusion:** Osteolysis is a complication of long term untreated RA that is rarely seen in adults with RA and is more common in JRA.

Key words: Rheumatoid Arthritis, Tempomandibular Joint, Osteolysis, Hip joint

Abbreviations: Rheumatoid Arthritis (RA), DMARD (disease modifying anti rheumatic drugs), NSAID (Non-Steroidal anti-inflammatory drugs), Full Range of Motion (FROM), Tempomandibular Joint (TMJ)

Introduction

Rheumatoid arthritis is a common inflammatory arthritis, affecting 0.8 percent of the adult population worldwide. Unknown autoantigens trigger the inflammatory process that results in hypertrophic and hyperplastic synovium called Pannus. Prevalence in the United States is estimated

1% of the population with an incidence in women twice that in men (1). Onset usually occurs between 30 to 50 years of age. It most commonly affects small joints of the body especially MCP and PIP of the hand in a symmetrical fashion. Different hip joint pathologies are described in RA including osteoarthritis, avascular necrosis (AVN) secondary to long term steroids which accounts for about 35 percent of cases of non-traumatic AVN, stress fractures, osteoporosis, osteonecrosis and septic arthritis, which are described on x-ray as joint space narrowing may be accompanied by osteopenia, cyst formation and rarely femoral head collapse (2). Untreated RA can lead to irreversible hip joint damage or destruction resulting in deformities. This is more reported in juvenile rheumatoid arthritis (JRA) in contrast to adult rheumatoid arthritis. Hip disease develops in 30 to 50% of children with JRA, but only 5-15% of patients with adult RA.

Case history

A 54-year-old African American female with a 30

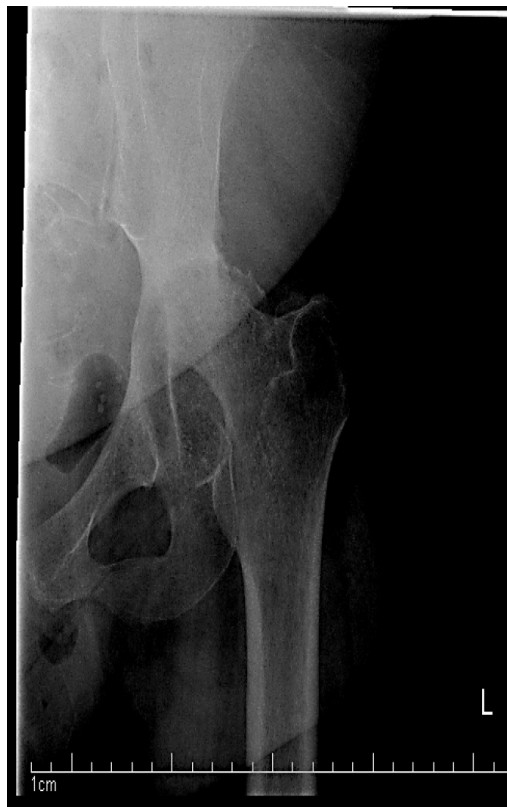

Figure 1B. Single AP view Xray of the left hip: Nonvisualization of the left femoral head which represent resorption of the femoral neck.

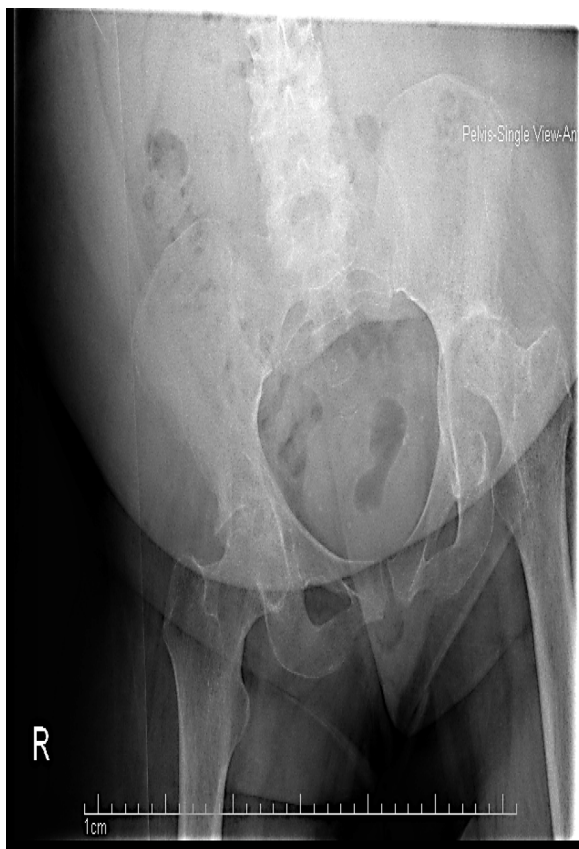

Figure 1A. Single AP view Xray of the pelvis showing non visualization of the right and left femoral head attributed to resorption of the femoral neck. Marked subcondral sclerosis in the acetabulum bilaterally.

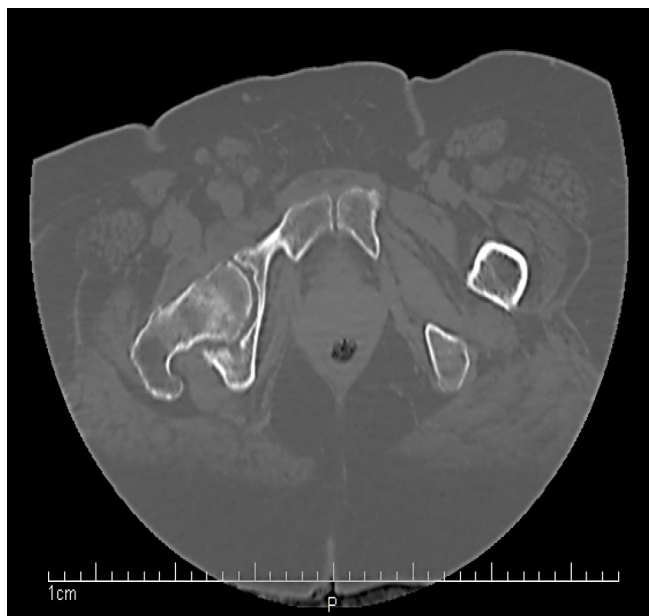

Figure 2A. Axial CT scan of the pelvis without contrast: advanced degenerative changes in both hip joints with partial resorption of both femoral heads worse on the left. No fracture was noted

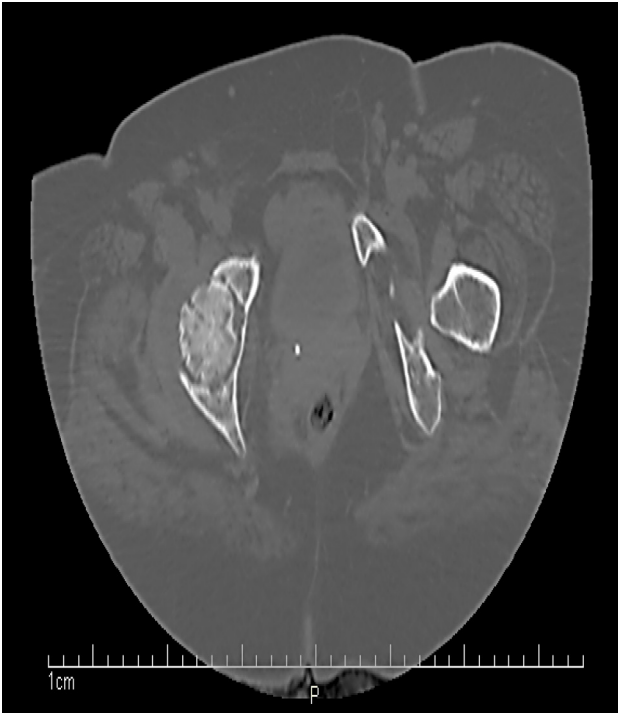

Figure 2B. Axial CT scan of the pelvis without contrast: resorption of both femoral heads with advanced degenerative changes in the form of subchondral sclerosis and subchondral cyst formation in both acetabular and femoral head suggestive of advanced degenerative changes

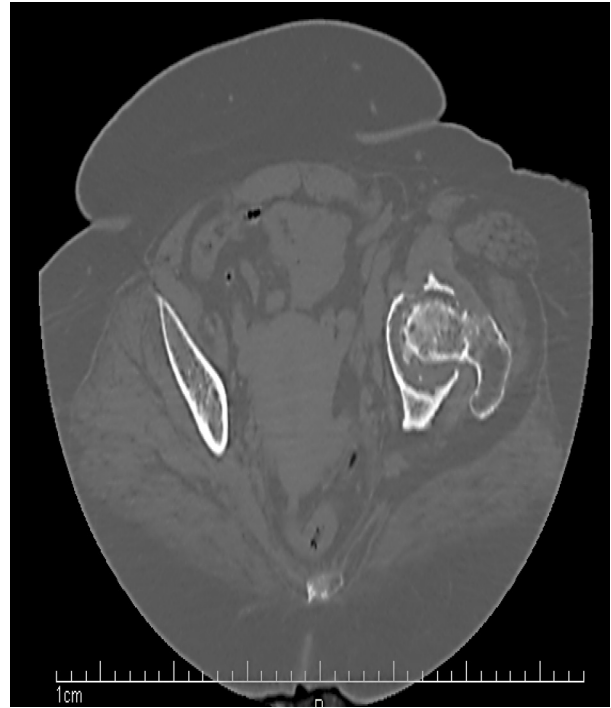


Figure 2D. Axial CT scan of the pelvis without contrast: resorption of the right femoral head with advanced degenerative changes

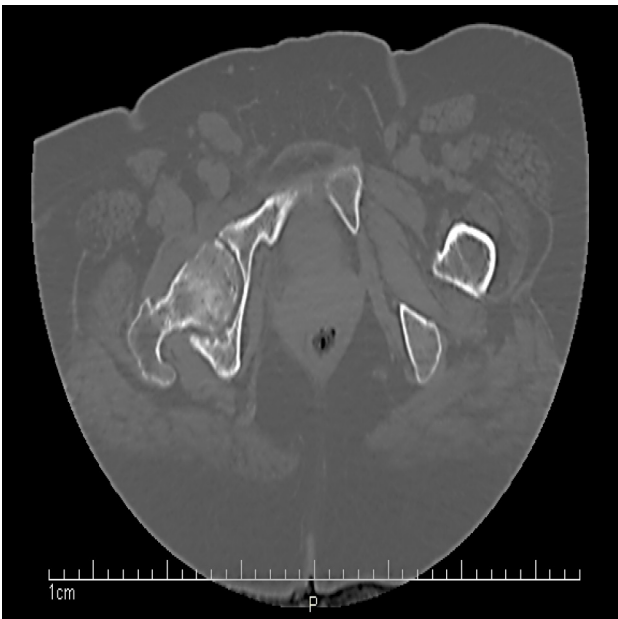


Figure 2C. Axial CT scan of the pelvis without contrast: resorption of the left femoral head with advanced degenerative changes

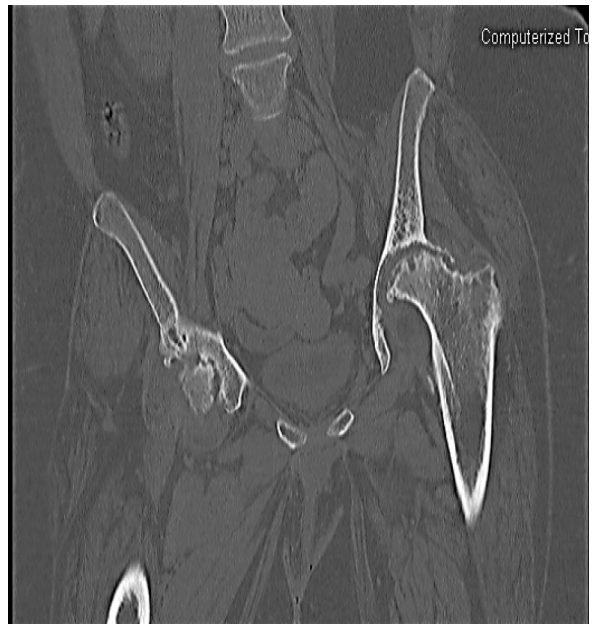

Figure 3A. Coronal CT scan of the pelvis without contrast: advanced degenerative changes in both hip joints with partial resorption of both femoral heads worse on the left, no fracture was noted

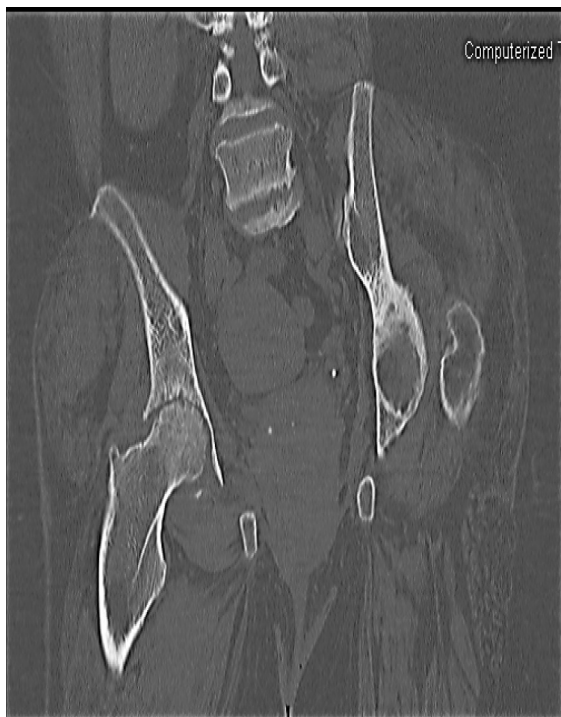

Fig. 3 B Coronal CT scan of the pelvis without contrast: advanced degenerative changes in both hip joints with partial resorption of right femoral head

years history of seropositive rheumatoid arthritis (RA), hypertension and congestive heart failure (systolic dysfunction with an ejection fraction [EF] of 25-30%) presented to the emergency department (ED) with community acquired pneumonia. Rheumatology service was consulted for untreated RA. Patient had been treated for RA with non-steroidal anti-inflammatory drugs (NSAIDs), prednisone 20mg daily and gold injections for 3 months about 30 years ago. Since then she stopped taking any medications other than over the counter NSAID. She was complaining of aching pain in the hands and hips when trying to move. Patient reported no history of recent trauma or use of DMARD (disease modifying anti rheumatic drugs) or corticosteroid. She has been a wheel chair-bound for the last 14 years due to severe limitation of joint movements and chronic aching pain in the hips and knee bilaterally that started to worsen progressively in the 4-5 years prior to being in wheel chair. She had morning stiffness of over 30 minutes. Patient denies any fever, chest pain, or skin rash.

On physical examination, the patient appeared to have difficulty in moving in bed. Her vital signs were stable with blood pressure: 113/72mmHg, respiratory rate: 16 breaths pm, pulse: 87 beats pm, temperature: 37.1°C, oxygen saturation of 97% on room air and BMI: 29 kg/m².

Table 1. Details of the musculoskeletal examination.	
Joint/Part	Physical Findings
Cervical Spine	Normal flexion 45, Rotation 70, lateral bending 40, Extension 45 passively and actively. Full range of motion (FROM) of tempo mandibular joint (TMJ) with no tenderness or crepitus.
Shoulders	Deltoid muscle atrophy. Limitation of flexion and extension (<90), external rotation and internal rotation(40), adduction:20, abduction: <90.
Elbows	No synovitis or rheumatoid nodules. Limitation of flexion and extension with mild flexion deformity bilaterally
Wrists	Caput ulnae, Limitation of flexion and extension (<90), No active synovitis
Hands	Subluxation of MCP joints, ulnar deviation and swan neck deformity was observed. Muscular atrophy. Decreased grip strength. No active synovitis
Hip Joints	External rotation 25, lateral rotation 40, flexion 60, extension 0, adduction 5, abduction 15. Pain on range of motion elicited
Knee	Flexion deformity 30 bilaterally.
Ankles and Feet	No synovitis, hallux valgus deformity, and subluxation of MTP joints.
Extremities	Trace bilateral lower extremity edema

She was oriented to time, place and person. No abnormalities were noted on examining the head, eye, ear, nose and throat exam. No lymphadenopathy was noted. No nail changes were present. Pulmonary examination showed decreased air entry bilaterally in the lower zones of the lungs with coarse crepitation on the right lung base. The detailed musculoskeletal examination's findings are given in Table 1. Rest of the physical examination was essentially normal. Laboratory findings on admission showed an erythrocyte sedimentation rate: 50 mm/hr, CRP: 3mg/l, Positive Rheumatoid factor 126 IU/ml (normal is less than 6IU/ml), Positive Anticyclic citrullinated peptide antibody 364 EU (normal is less than 20 EU). Chest X-Ray showed right lower lobe infiltrate with left base atelectasis. Single AP view X-Ray of the pelvis and two views of the left hip in neutral and frog-leg position were performed (Figure 1. A and B). The left femoral head appears to be resorbed on the single AP view pelvis. However, there is a bone density noted posterior to the left femoral neck on two views of the left hip, which could represent subcapital femoral neck fracture with posterior displacement of the femoral head out of the acetabular socket. There is marked subchondral sclerosis in the acetabulum noted. There are also degenerative changes noted in the right hip in the form of subchondral sclerosis with subchondral cyst formation in the right femoral head. CT scan of the pelvis without contrast done (Figure 2). There is no fracture or dislocation. There was partial resorption of both femoral heads with advanced degenerative changes in the form of subchondral sclerosis and subchondral cyst formation in both acetabular and femoral head suggestive of advanced degenerative changes. However, both femoral necks and intertrochanteric regions including proximal femurs are unremarkable. There is no hip bone fracture. There is also degenerative change in the lower lumbar spine in the form of facet joint hypertrophy. There is marked osteopenia and muscle atrophy with fat replacement is noted in both lower limbs at the proximal aspect.

Discussion

We described a case of bilateral femoral hip resorption in untreated RA. This disease is characterized by chronic inflammation and destructive changes of the joints if untreated and ultimately resulting in physical disability (1). DMARDs have been shown to reduce inflammation and slow the progression of joint damage and early initiation of DMARD in recent-onset RA was shown to be associated with a better disease outcome after 2 years (3). Van Aken and colleagues (4) have shown the beneficial effect of early DMARD treatment on the radiological progression of joint

damage.

Radiographically differential diagnosis include entities such as primary osteonecrosis with secondary osteoarthritis, osteolytic process secondary to rheumatoid arthritis, rapidly progressive hip disease, neuropathic arthropathy, septic arthritis, massive articular osteolysis or vanishing bone disease "Gorham's disease". In most cases, combination of clinical history and radiographic findings are important for reaching a diagnosis.

Chronic osteolytic process secondary to JRA starts with osteoporosis followed by burrowing and inward protrusion of the acetabulum, and collapse and flattening of the femoral heads. This eventually leads to total disappearance of the femoral heads (5-7).

Vanishing bone disease or massive articular osteolysis "Gorham's disease" is a rare disorder characterized by proliferation of vascular channels and an increased osteoclastic activity that cause massive destruction of bone matrix which is replaced by thin walled vessels and fibrous tissue (8). The etiology of the disease remains unclear. It can occur spontaneously, following trauma (9) as well as with and without concurrent RA.

Rapidly progressive hip disease, also known as rapidly destructive coxarthrosis, is a rare syndrome of unknown etiology and distinct from ischemic necrosis of the femoral head, resulting in rapid deterioration of both the femoral and acetabular aspects of the hip joint with disappearance of the femoral head (10). Yoshino K et al reported three patients with acute destruction of the hip joints and they speculated that highly inflammatory coxarthrosis might cause an osteoporotic change in the hip joint and lead to rapid resorption of the femoral head. They noted that subcapital insufficiency fracture due to osteoporotic change might be a preliminary event in the development of rapidly destructive coxarthrosis in active RA (11). In contrast, a retrospective case series by Batra S et al reviewed 115 patients with primary osteoarthritis of the hip and 18 patients out of 115 met the criteria of rapidly destructive coxarthrosis. Analysis of the data showed that none of these 18 cases had evidence of rheumatoid arthritis (12).

Our patient was evaluated by orthopedics and was admitted as an inpatient for rehabilitation. She was not a good candidate for hip arthroplasty due to contracture deformities in the hip and knees bilaterally and was started on methotrexate 7.5mg/week.

Osteolysis of the hip joint is a complication of untreated RA that is rarely seen in the modern era of highly advanced approaches to the treatment of adult RA. Rapid destruction of the hip joints has been described, often in the setting of steroid use and also in the setting of rheumatoid arthritis, refractory to DMARD therapy (11). Additionally it was reported and studied in JRA.

In the present case, the rate of resorption of the femoral heads is unknown and in the absence of other factors like recent steroid use, trauma, infection, it is likely that long term untreated RA has resulted in the observed resorption of the femoral heads.

This case serves to emphasize the fact that treatment of RA should not be ignored and RA patients with hip pain should be reevaluated for imaging studies if their pain worsens or changes in character.

References

1. Firestein GS: Etiology and pathogenesis of rheumatoid arthritis. In: Firestein GS, Budd RC, Harris ED Jr., McInnes Iain B., Ruddy Shaun, Sargent JS, Editors. Kelley's Textbook of Rheumatology. 8th edition. Philadelphia: Elsevier Saunders; 2009.
2. Devane P and Horne G. The adult hip In: Stuart L. Weinstein and Joseph A. Buckwalter (Editors): Turek's Orthopaedics: Principles and Their Application. Lippincott Williams & Wilkins; 2005; p 519-574.
3. Lard LR, Visser H, Speyer I, vander Horst-Bruinsma IE, Zwinderman AH, Breedveld FC, Hazes JM. Early versus delayed treatment in patients with recent-onset rheumatoid arthritis: comparison of two cohorts who received different treatment strategies. *Am J Med* 2001;111:446-51.
4. Van Aken J, Lard LR, le Cessie S, Hazes JM, Breedveld FC, Huizinga TW. Radiological outcome after four years of early versus delayed treatment strategy in patients with recent onset rheumatoid arthritis. *Ann Rheum Dis* 2004;63:274-9.
5. Mbuyi-Muamba JM, Dequeker J, Burssens A: Case report: massive osteolysis in a case of rheumatoid arthritis: clinical, histologic and biochemical findings. *Metab Bone Dis Relat Res*; 1983-1984;5(3):101-5.
6. Kennedy WR, Johnston AD, Becker A. Massive articular osteolysis in rheumatoid arthritis, treated by total hip replacement. A Case report and review of literature. *Clin Orthop Relat Res*. 1973; 90:161-73.
7. Gerster JC, Anani P, de Goumoens P, Pellation M. Lytic lesions of the femoral neck in rheumatoid arthritis simulating pigmented villonodular synovitis or malignancy. *Clin Rheumatol*. 1982; 1(1):30-4.
8. Patel DV. Gorham's disease or massive osteolysis. *Clin Med Res*. 2005;3(2):65-74.
9. Ko HJ, In Y, Park KS, Cho CS, Kim HY. Vanished humeral head in a patient with rheumatoid arthritis: a case of Gorham's disease. *Rheumatol Int*. 2010;30(4):569-70.
10. Khanna AJ, Domb BG, Moshirfar A, Wenz JF Sr. Rapidly destructive osteoarthropathy of the hip. *Am J Orthop (Belle Mead NJ)*. 2004; 33(5):243-7.
11. Yoshino K, Momohara S, Ikari K, Kawamura K, Mochizuki T, Iwamoto T, Niki Y, Saitou S, Tomatsu T. Acute destruction of the hip joints and rapid resorption of femoral head in patients with rheumatoid arthritis. *Mod Rheumatol*. 2006; 16(6):395-400.
12. Batra S, Batra M, McMurtrie A, Sinha AK. Rapidly destructive osteoarthritis of the hip joint: a case series. *J Orthop Surg Res*. 2008;3:3.