

## CASE REPORT

## Gaucher Disease Presenting with Atypical Skin Pigmentation in an Arab Patient

Husni Salman Hateeti

Department of Haematology, Sheikh Khalifa Medical City, Abu Dhabi, United Arab Emirates

Corresponding author: Dr. Husni S. Hateeti      Email: hosnihatiti@hotmail.com

Published: 29 April 2016

Ibnosina J Med BS 2016;8(2):54-57

Received: 18 March 2015

Accepted: 04 March 2016

This article is available from: <http://www.ijmbs.org>

This is an Open Access article distributed under the terms of the Creative Commons Attribution 3.0 License, which permits unrestricted use, distribution, and reproduction in any medium, provided the original work is properly cited.

### Abstract

Gaucher disease (GD) is the most prevalent lysosomal storage disease resulting in accumulation of glucoceramide in lysosomes of the reticuloendothelial system. There are three clinical types of GD; the most common of which is type 1. The clinical spectrum is variable with patients developing anemia, evidence of hypersplenism and pathological fractures that are due to bone involvement, nevertheless, many have a normal life span. A case of typical type 1 GD but with atypical skin pigmentation in a Palestinian patient with strong family history of skin hyperpigmentation and hypersplenism is reported

**Key words:** Gaucher Disease, Lysosomal storage disease, Glucoceramide.

### Introduction

Gaucher disease (GD) is the most prevalent lysosomal storage disease (1). It affects one in 100000 of general population and about one in 1000 of Ashkenazi Jews (1). GD is due to a deficiency of a glucocerebrosidase, a specialized lysosomal acid B-glucosidase (2). This results in accumulation of glucoceramide in lysosomes of the reticuloendothelial system, particularly the liver, bone marrow and spleen. There are three clinical types of GD; the most common is type 1 which presents in adult life with an insidious onset of hepatosplenomegaly and patients have a characteristic pigmentation on the exposed parts, particularly the forehead and hands. The clinical spectrum is variable with patients developing anemia, evidence of hypersplenism and pathological fractures that are due to bone involvement, nevertheless, many have a normal life span (3). A case of typical type 1 GD but with atypical skin pigmentation in Palestinian patient with strong family history of skin hyperpigmentation and hypersplenism is

presented.

### Case report

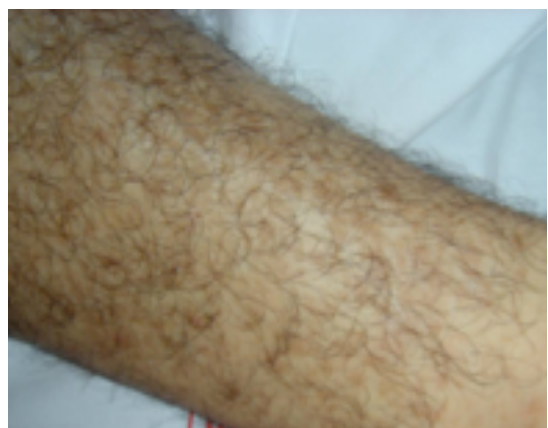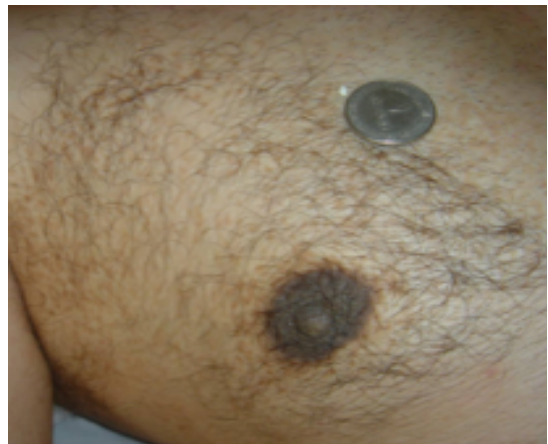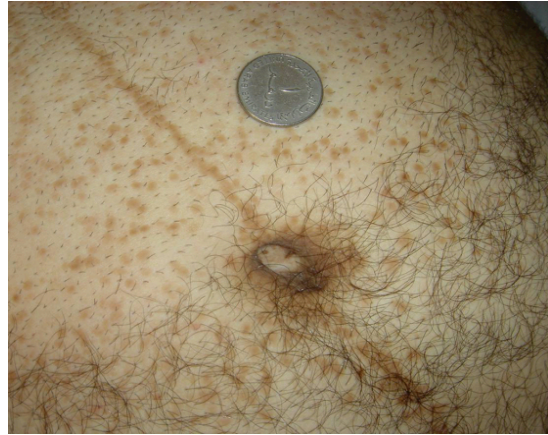A 40 years old Palestinian man was on diet and lost 8 kg over two months. He presented to the primary health care centre with generalized fatigue and giddiness, full blood count revealed severe neutropenia and thrombocytopenia so he was referred to our haematology clinic at Sheikh Khalifa Medical City (SKMC), Abu Dhabi, UAE for further investigations. His past medical history included undiagnosed splenomegaly for the previous 6 years, congenital pigmentation on unexposed skin, arterial hypertension for one year and *H. pylori*-positive peptic ulcer disease. He has six brothers and three sisters. One brother and one sister aged 34 and 43 respectively had splenomegaly, neutropenia, thrombocytopenia and *H. pylori*-positive peptic ulcer disease but no skin pigmentation. Maternal grandfather, mother, all six aunts, brother and one sister aged 21 and 29 years respectively with same skin pigmentations. Father, uncle and paternal grandfather died of malignant disease, colon, brain and liver respectively in the sixth decade of life.

### Physical examination

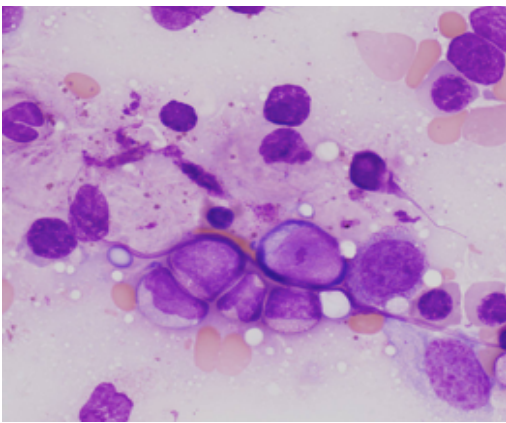
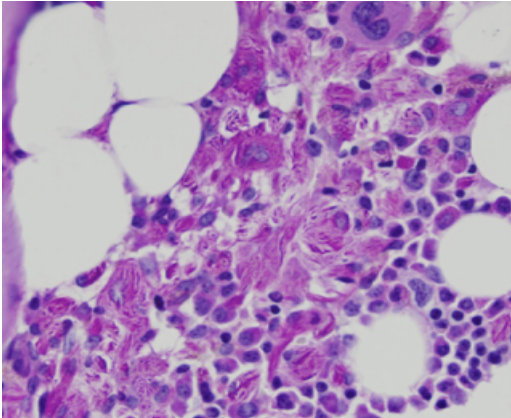
On physical examination he looked well but pale and not jaundiced. Vitals were stable. Body weight was 85 kg; Height was 180 cm. Skin examination revealed hyperpigmented maculae's; about 2x3 mm diameter, round to oval in shape which were distributed on the chest, abdomen, axilla, buttocks and ankles. These gathered around the mid line, nipples, axilla and umbilicus (Figure 1A-1C). Abdominal examination revealed a palpable spleen at 5 cm below costal margin. Rest of the physical examination was unremarkable.

### Laboratory results

Haemoglobin: 120 g, Hematocrit: 0.375, platlet count: 90, white blood count: 1.1, absolute neutrophils count was 0.05 and erythrocyte sedimentation rate was 29 in the first hour. Peripheral smear showed mild polychromasia, ovalocytes, and occasional dacrocytes. Total serum cholesterol was 1.7 mmol/l, serum triglycerides was 2.65 mmol/l, HDL cholesterol was 0.112 mmol/l and LDL cholesterol was 0.42 mmol/l. Serum electrolytes, liver function tests, coagulation profile were all within the normal limit. Angiotensin converting enzymes were elevated (111 UECA; normal range for adult 12-68 UECA). Total acidic phosphate 11.3 U/L (normal range for this age group is 2.1 -6.5). Bone



**Figure 1.** Skin lesions as seen in the upper chest, around umbilicus and legs.



**Figure 2.** Bone marrow histology demonstrating storage disease suggesting GD involving bone marrow

marrow histology reports: storage disease in favor of GD involving bone marrow (Figures 2A, 2B). Bone marrow flow cytometry showed no evidence of hematolymphoid malignancy. Beta-glucosidase in leukocytes was 0.02 (expected values 0.08-0.35)

### Discussion

We describe a unique case of type one gaucher disease in Palestinian male with atypical skin hyperpigmentation or in other way reversed distribution of the skin hyperpigmentation in GD. The characteristic Cutaneous manifestation of GD include gray, brown pigmentation of the forehead, hands, and

periorbital regions, a malar flush and pingueculae; which is a yellow-brown deposits occurs in the lateral sclera, a condition reflecting elastosis or breakdown of the collagen fiber in the sclera rather than deposits of Gaucher cell at the site (4). The malar flush is often present in patients with early onset severe GD and the attendant manifestations of liver infiltration include palmar erythema and spider angiomas. Ten of his family members have the same skin hyperpigmentations; mother, six maternal aunts, maternal grandfather, one sister, and one brother, none of them known to have enlarged spleen or hypersplenism features. One brother and one sister have hypersplenism and that brother was complaining of bone pain so recently he was found to have GD with bone involvement. No convincing explanation for the clinical variability of GD that extends to affect sibs with shared genotypes or even affected twin pairs has been advanced. Unknown environmental factors appear to be critical for disease expression.

Little information is available about the frequency of GD in non-Jewish population so here we have two brothers with GD and if we can assume the other family member who has the same skin manifestation or splenomegaly then we have twelve family members with GD. There were few reports describe an unusual clinical syndrome of GD in consanguineous Palestinian patients from an extended family (4). This disorder in association with mild neuropathic manifestations and is compatible with survival to the third decade, non-progressive oculomotor apraxia was the original presenting finding, slight to moderate enlargement of the spleen as noted also in this syndrome the heart is characteristically affected with progressive thickening and classification of mitral and aortic valve causing significant mitral valve regurgitation, mild aortic insufficiency or severe aortic stenosis requiring surgery (5).

Patient with GD usually notice long standing fatigue independent of the symptoms of anemia, this appear to be associated with abnormal energy metabolism (6) and may be a manifestation of the persistent acute phase response characteristic of established GD. Symptoms of GD are usually declared as a result of splenic enlargement; either obvious visceromegaly is noticed or the individual present with the consequence of hypersplenism; anemia, bleeding tendency due to thrombocytopenia and sometimes recurrent bacterial infection related to neutropenia (7).

Retrospective enquiry in patient at the time of diagnosis

frequently reveals a history of bone but our patient denied any history of bone pain but at the same time he mentioned a history of bone pain in his brother who also has splenomegally and after identification of our patient he was investigated and diagnosed with GD involving bones. Occasionally GD comes to light because of skeletal disease, usually with an episodes of a vascular necrosis affecting the hip, proximal humerus or associated with painful compression fractures of necrotic vertebrae.

### References

1. Linari S, Castaman G. Clinical manifestations and management of Gaucher disease. *Clin Cases Miner Bone Metab* 2015;12(2):157-64.
2. Chu FC, Rodrigues MM, Cogan DG, Barranger JA. The pathology of pingueculae in Gaucher's disease. *Ophthalmic Paediatr Genet* 1984;4(1):7-11.
3. Kolodny EH, Ullman MD, Mankin HJ, Raghavan SS, Topol J, Sullivan JL. Phenotypic manifestations of Gaucher disease: clinical features in 48 biochemically verified type 1 patients and comment on type 2 patients. *Prog Clin Biol Res* 1982;95:33-6.
4. Matoth Y, Fried K. Chronic Gaucher's disease; clinical observations on 34 patients. *Isr J Med Sci* 1965;1(4):521-30.
5. Uyama E1, Takahashi K, Owada M, Okamura R, Naito M, Tsuji S, et al. Hydrocephalus, corneal opacities, deafness, valvular heart disease, deformed toes and leptomeningeal fibrous thickening in adult siblings: a new syndrome associated with beta-glucocerebrosidase deficiency and a mosaic population of storage cells. *Acta Neurol Scand* 1992;86(4):407-20.
6. Barton DJ, Ludman MD, Benkov K, Grabowski GA, LeLeiko NS. Resting energy expenditure in Gaucher's disease type 1: effect of Gaucher's cell burden on energy requirements. *Metabolism*. 1989;38:1238-43.
7. Zimran A, Kay A & Gelbart TGD. Clinical laboratory, radiological and genetic features of 53 patients, *Medicine (Baltimore)* 71:337-5(1992)

### Editors

Salem Beshyah, Abu Dhabi  
Elmahdi Elkhammas, Columbus, Ohio, USA.

### Reviewers

Wanis Ibrahim, Doha, Qatar.  
Farhana Bin Lootah, Abu Dhabi, UAE