

Pneumocephalus after surgical evacuation of chronic subdural hematoma: Is it a serious complication?

Zidan Ihab

Department of Neurosurgery, Faculty of medicine, Alexandria University, Alexandria, Egypt

ABSTRACT

Background: Pneumocephalus is commonly encountered after surgical evacuation of chronic subdural hematoma (CSDH). This study was done to study the incidence, clinical presentation, and management of patients who developed pneumocephalus after surgical evacuation of CSDH.

Materials and Methods: This prospective study was carried out on consecutive 50 patients who had received surgical treatment for CSDH. All the patients included were followed-up postoperatively with regular clinical and computed tomography (CT) examinations immediately postoperatively, before discharge, and 2 months after surgery. Pneumocephalus was classified into simple and tension, based upon the clinical and radiological criteria. The neurologic grading system of Markwalder *et al*/was used to evaluate the surgical results.

Results: The immediate postoperative CT scan showed pneumocephalus in 22 patients (44%). Tension pneumocephalus was found in two patients who did not require any further surgery. There was statistically significant increase in the incidence of pneumocephalus (immediate and postoperative) in the patients aged over 60 years as well as those presenting with a midline shift more than 5 mm in their CT scan. With regard to the 22 cases of pneumocephalus, good postoperative results were found in 16 patients (73%), while bad results were found in 6 patients (27%). No statistically significant difference in the outcome between patients who had pneumocephalus after surgery and those who had not.

Conclusion: Pneumocephalus after surgical evacuation of CSDH is a common finding in the immediate CT scan as well as at time of discharge. Tension pneumocephalus may not require surgical intervention and simple aspiration of air using a syringe may be sufficient.

Key words: Chronic subdural hematoma, simple pneumocephalus, surgical evacuation, tension pneumocephalus

Introduction

Chronic subdural hematomas (CSDH) are usually encountered in the elderly, particularly after minor head injury. The annual reported incidence of CSDH is approximately 0.001–0.002%.^[1] CSDH is a common neurosurgical problem that is still associated with significant morbidity and mortality.^[2] Pneumocephalus is

defined as the presence of air within any of the intracranial compartments. CSCHs are commonly associated with cerebral atrophy and the associated increase in potential space in the subdural area. This factor helps air collection after surgery.^[3] Two types of pneumocephalus exist; simple and tension types. In clinical practice, it is of significant importance to differentiate simple from tension pneumocephalus. Simple pneumocephalus is typically asymptomatic and requires no treatment. Tension pneumocephalus refers to air collection under pressure compared with the outside atmospheric pressure, when, in most circumstances, a valve mechanism allows air to enter the skull but prevents it from escaping, thus creating a pressure differential.^[4-6] Clinical presentation includes headaches, nausea and vomiting, seizures, hemiparesis, dizziness, and depressed neurological status. Tension pneumocephalus usually requires an emergent management.^[4]

The aim of this work was to study the incidence, clinical presentation, and management of patients who developed

Access this article online

Quick Response Code:



Website:

www.asianjns.org

DOI:

10.4103/1793-5482.98647

Address for correspondence:

Dr. Zidan Ihab, Faculty of Medicine, Alexandria University, Champillion st, Elazaritta, 21131, Alexandria, Egypt.
E-mail: zidanihab@yahoo.fr

pneumocephalus after surgical evacuation of chronic subdural hematoma.

Materials and Methods

This prospective study was carried out on consecutive 50 patients who had received surgical treatment for chronic subdural hematomas. This study was done in Alexandria hospitals over a period of three years starting from April 2008 to April 2011. The male to female ratio was 1.3 to 1 (28 male and 22 female) and their ages ranged from 33 till 91 years with mean age of 63.9 years.

With regard to the clinical presentation, headache was the most common presentation found in 16 patients (32%), followed by neurological deficit in 14 patients (28%), cognitive disturbances in 7 patients (14%). Other presentations for chronic subdural hematoma in the present study included; disturbed sensorium in five patients, ataxia in five patients, and seizures in three patients.

In all cases, computed tomography (CT scan) was performed to evaluate the location and size of CSDH as well as the degree of midline shift if present. The hematoma was on the right in 21 cases, on the left in 20 cases, and bilateral in 9 cases.

Surgery was performed under general anesthesia in 36 patients and under local anesthesia in 14 patients. The surgical procedure included burr-hole craniotomy (single or double) in 42 patients and craniotomy flap in eight patients (depending on hematoma type). Surgical evacuation of the subdural collection was done by dural and hematoma membrane incision followed by repeated saline irrigation and drainage in all the cases. Postoperative, the patients were nursed in a flat position and drains were removed after 2–5 days. Drainage time depended on the amount of subdural fluid observed in the drains.

All patients underwent sequential CT scans immediately postoperatively, before discharge, and 2 months after surgery. Generally, CT scan was done to quantify the decrease in the hematoma thickness, and presence or absence of pneumocephalus. More frequent repeat CT scans were obtained if the patients showed unexpected neurological deterioration. The average stay in the Department of Neurosurgery was 6.2 days, ranging from 3 to 29 days.

The neurological grading system of Markwalder *et al.*^[7] on admission and at discharge was used to evaluate the surgical results [Table 1]. Good pre- and post-operative results were considered in patients graded 0–2 and bad pre- and post-operative results in patients graded 3–4.

Statistical analysis

Data were analyzed using Statistical Package for the Social Sciences (SPSS) software package version 18.0 (SPSS, Chicago,

Table 1: The neurological grading system of Markwalder *et al.*

| Grade | |
|-------|---|
| 0 | No neurological deficits |
| 1 | Patient alert and oriented, mild symptoms such as headache; absent or mild neurological deficits such as reflex asymmetry |
| 2 | Patient drowsy or disoriented with variable neurological deficits such as hemiparesis |
| 3 | Patient stuporous but responding appropriately to noxious stimuli; severe focal signs such as hemiplegia |
| 4 | Patient comatose with absent motor response to painful stimuli; decerebrate or decorticate posturing |

IL, USA). Qualitative data was expressed in frequency and percentage. Qualitative data was analyzed using Fisher exact test to compare different groups. Odds Ratio was calculated to predict the risk factor. p value was assumed to be significant at ≤ 0.05 .

Results

Post-operative morbidity

Among the 50 cases operated for surgical evacuation of CSDH; we had recurrence in 9 cases, wound infection in 4 cases, medical complications (pneumonia and deep vein thrombosis) in 4 cases, epilepsy in 3 patients, subdural empyema and intracerebral hemorrhage in two cases each.

Immediate postoperative pneumocephalus

With regard to the presence of pneumocephalus in the immediate postoperative CT scan; pneumocephalus was observed in 22 patients (44% of the cases) [Figures 1-5]; simple pneumocephalus in 20 patients (40%) [Figures 1, 3-5]; and tension pneumocephalus in two patients (4%) [Figure 2]. The most common age population in which pneumocephalus was observed between 60-80 years detected in 14 patients (64% of cases of pneumocephalus), followed by age group more than 80 years in five patients (23% of cases of pneumocephalus), and lastly age group between 40-60 years in three patients (13% of cases of pneumocephalus) [Table 2]. Midline shift more than 5 mm was found in 12 patients, while in the other 10 patients, there was no midline shift or it was less than 5 mm [Table 3].

There was statistically significant increase in the incidence of immediate postoperative pneumocephalus in the patients aged over 60 years as well as those presenting with a midline shift more than 5 mm in their CT scan.

All cases of simple pneumocephalus did not show any neurological deterioration and did not require any specific treatment. We had two cases of tension pneumocephalus; the first case was a female patient aged 60 years with a right frontoparietal CSDH presented with left hemiparesis. The patient showed improvement postoperative followed by progressive disturbance in the conscious level and follow-up CT revealed tension pneumocephalus. Simple aspiration

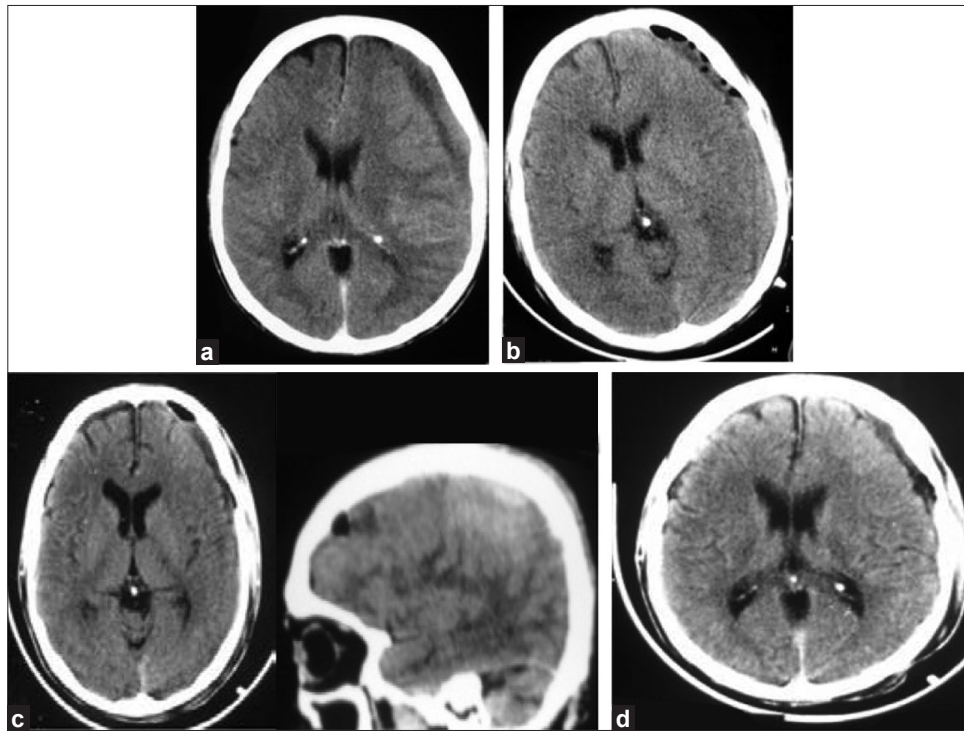


Figure 1: (a) CT scan (axial view) showing left frontal CSDH in a 50-year-old male patient; (b) Immediate postoperative CT scan (axial view) following burr-hole craniotomy showing left frontal pneumocephalus; (c) Follow-up CT scan (axial and sagittal views) before discharge showing nearly complete resolution of pneumocephalus; (d) Follow-up CT scan (axial view) after 2 months showing complete resolution of pneumocephalus

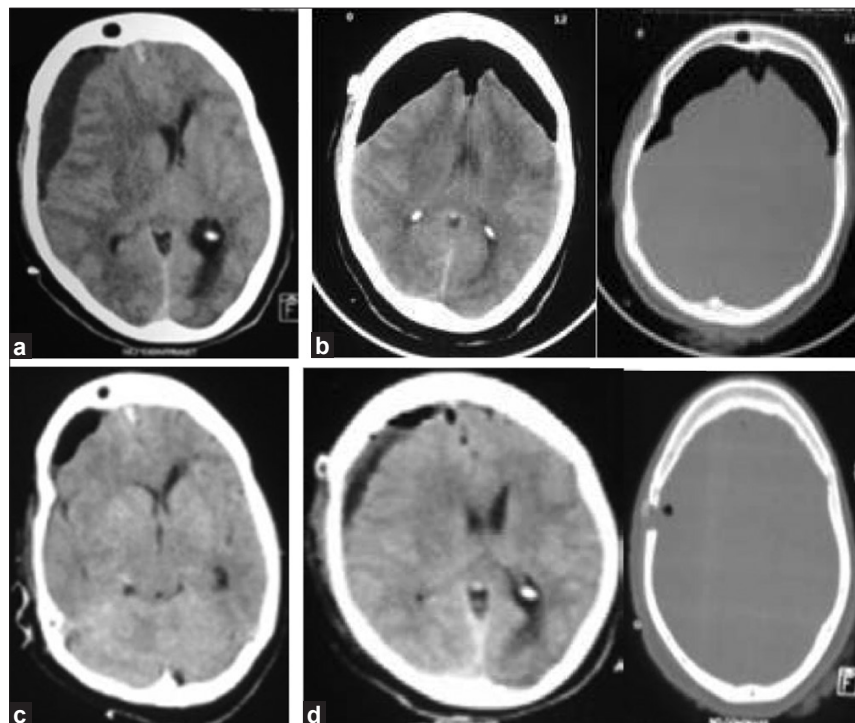


Figure 2: (a) CT scan (axial view) showing right frontoparietal CSDH with midline shift more than 5 mm in a 60-year-old female patient; (b) Immediate postoperative CT scan (axial view; soft tissue and bone window) following burr-hole craniotomy showing Mount Fuji sign signifying tension pneumocephalus; (c) Follow-up CT scan (axial view) after simple aspiration of air through the skin incision showing marked diminution of pneumocephalus; (d) Follow-up CT scan (axial view; soft tissue and bone window) before discharge showing nearly complete resolution of pneumocephalus

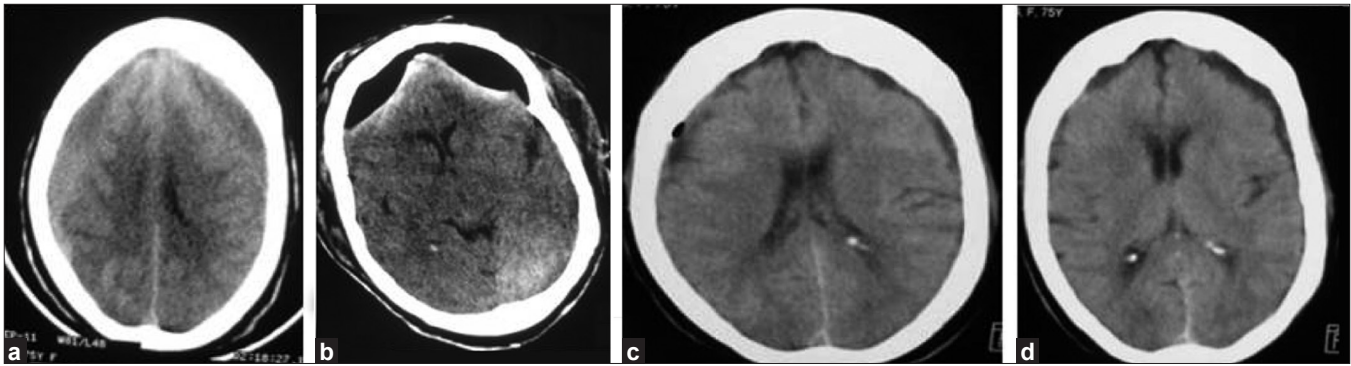


Figure 3: (a) CT scan (axial view) showing bilateral frontopareital CSDH in a 73-year-old female patient; (b) Immediate postoperative CT scan (axial view) following burr-hole craniotomy showing bifrontal pneumocephalus “Peaking sign”; (c) Follow-up CT scan (axial view) before discharge showing nearly complete resolution of pneumocephalus; (d) Follow-up CT scan (axial view) after 2 months showing complete resolution of pneumocephalus

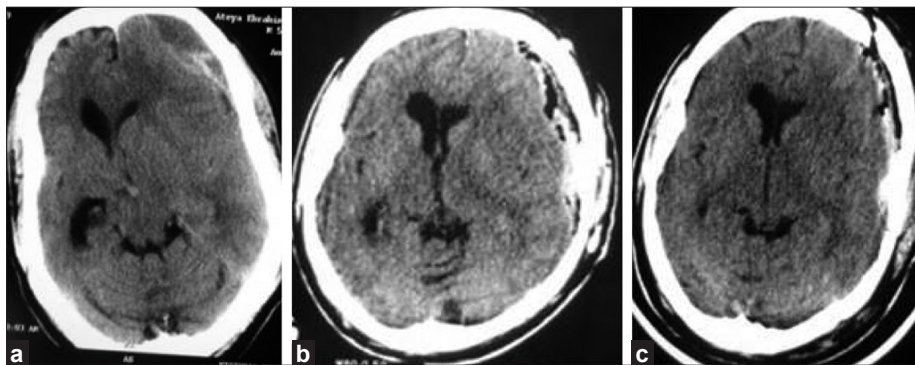


Figure 4: (a) CT scan (axial view) showing left frontal CSDH with midline shift in a 85-year-old male patient; (b) Immediate post-operative CT scan (axial view) following craniotomy flap showing left frontal pneumocephalus; (c) Follow-up CT scan (axial view) before discharge showing near complete resolution of pneumocephalus

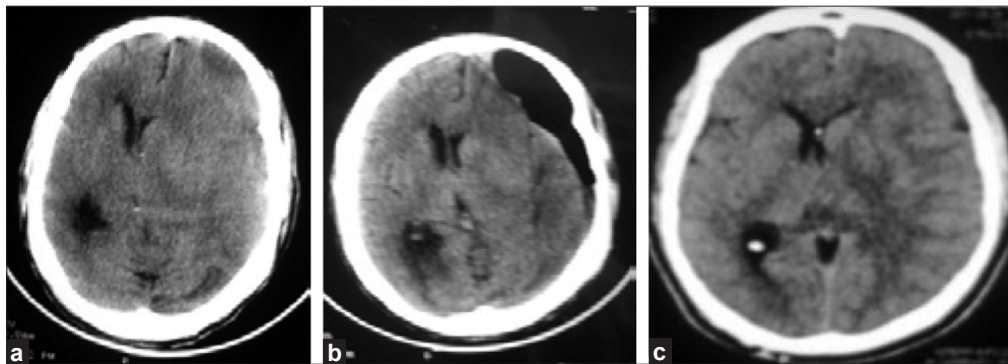


Figure 5: (a) CT scan (axial view) showing left frontopareital CSDH with midline shift in a 71-year-old female patient; (b) Immediate post-operative CT scan (axial view) following burr-hole craniotomy showing left frontopareital pneumocephalus; (c) Follow-up CT scan (axial view) before discharge showing complete resolution of pneumocephalus

of air through the skin incision using a syringe was tried and the patient showed a favorable outcome within hours after aspiration. The follow-up CT scan of this patient at discharge showed a marked diminution of the air collection with total resolution after two months. The second case of tension pneumocephalus was a 62-year-old male patient, presenting with headache due to a right frontopareital CSDH. After surgery, the patient was still complaining from severe persistent headache associated with vomiting. The follow-up

CT scan showed signs of tension pneumocephalus, and the patient was managed conservatively. The treatment consisted of nursing in a flat position, administration of fluids, and supplemental breathing of 100% O₂. The patient responded well to treatment and follow-up CT scans showed marked diminution in the volume of air.

Pneumocephalus at time of discharge

Postoperative CT scan performed at discharge showed

the presence of pneumocephalus in 32% of the cases (16 patients) compared with 44% (22 patients) in the immediate follow-up [Table 2]. The most common age population in which pneumocephalus was observed was between 60-80 years detected in 11 patients (69% of cases of pneumocephalus), followed by age group more than 80 years in three patients (19% of cases of pneumocephalus), and lastly age group between 40-60 years in two patients (12% of cases of pneumocephalus) [Table 2]. Midline shift more than 5 mm was found in 12 patients, while in the other 4 patients, there was no midline shift or it was less than 5 mm [Table 3]. There was statistically significant increase in the incidence of pneumocephalus at discharge in the patients aged over 60 years as well as those with a midline shift more than 5 mm in the CT scan. The relation between the midline shift and the pneumocephalus at discharge was more significant than with immediate postoperative pneumocephalus.

Pneumocephalus at 2 months follow-up

CT scan performed 2 months after discharge did not show any cases of pneumocephalus in the present series.

Pneumocephalus and recurrence

In the present study, recurrence of CSDH was observed in 9 patients (18%). Pneumocephalus was a common finding in recurrent cases found in seven patients out of nine.

Post-operative surgical results

According to the preoperative neurologic grading system of Markwalder *et al*; we had 17 patients (34%) grade 1, 20 patients (40%) grade 2, 9 patients (18%) grade 3, and 4 patients (8%) grade 4. Postoperative grading with the same system a time of discharge showed 20 patients (40%) with grade 0, 14 patients (28%) grade 1, 6 patients (12%) grade 2, 5 patients (10%) grade 3, and 5 patients (10%) grade 4 [Table 4]. Good post-operative results were considered in patients graded 0–2 and had been found in 40 patients (80%), while bad post-operative results considered in patients graded 3–4 were found in 10 patients (20%) [Table 5]. Four cases (8%) died within the hospital; two of them were grade 4 before surgery and the other two were grade 3.

With regard to the 22 cases who had shown pneumocephalus; preoperatively we had 8 cases (36%) grade 1, 5 (23%) cases grade

Table 2: Pneumocephalus (immediate and post-operative) in relation to the age

| | Immediate | | | | At discharge | | | |
|-------------|---------------------|--------------------|------------------------|------|---------------------|------|------------------------|------|
| | With pneumocephalus | | Without pneumocephalus | | With pneumocephalus | | Without pneumocephalus | |
| | No. | % | No. | % | No. | % | No. | % |
| Age | | | | | | | | |
| <60 | 3 | 13.6 | 13 | 46.4 | 2 | 12.5 | 16 | 47.1 |
| ≥60 | 19 | 86.4 | 15 | 53.6 | 14 | 87.5 | 18 | 52.9 |
| FEp | | 0.017* | | | 0.026* | | | |
| OR (95% CI) | | 5.48* (1.32–22.85) | | | 6.22* (1.22–31.68) | | | |

FEp: P value for Fisher Exact test; *Statistically significant at $P \leq 0.05$

Table 3: Pneumocephalus (immediate and post-operative) in relation to the midline shift

| | Immediate | | | | At discharge | | | |
|---------------|---------------------|-------------------|------------------------|------|---------------------|------|------------------------|------|
| | With pneumocephalus | | Without pneumocephalus | | With pneumocephalus | | Without pneumocephalus | |
| | No. | % | No. | % | No. | % | No. | % |
| Midline shift | | | | | | | | |
| <5 | 10 | 45.5 | 25 | 89.3 | 4 | 25.0 | 31 | 91.2 |
| >5 | 12 | 54.5 | 3 | 10.7 | 12 | 75.0 | 3 | 8.8 |
| FEp | | 0.001* | | | <0.0001* | | | |
| OR (95% CI) | | 10.0 (2.32–43.16) | | | 31.0* (6.02–159.58) | | | |

FEp: P value for fisher exact test; *Statistically significant at $P \leq 0.05$

Table 4: Pre- and post-operative clinical grades according to the neurologic grading system of Markwalder *et al*.

| Clinical grade | Pre-operative | | Total | Post-operative | | Total |
|----------------|---------------------|------------------------|-------|---------------------|------------------------|-------|
| | With pneumocephalus | Without pneumocephalus | | With pneumocephalus | Without pneumocephalus | |
| Grade 0 | 0 | 0 | 0 | 6 | 14 | 20 |
| Grade 1 | 8 | 9 | 17 | 6 | 8 | 14 |
| Grade 2 | 5 | 15 | 20 | 4 | 2 | 6 |
| Grade 3 | 5 | 4 | 9 | 2 | 3 | 5 |
| Grade 4 | 4 | 0 | 4 | 4 | 1 | 5 |

Table 5: Post-operative results according to the neurologic grading system of Markwalder *et al.*

| | With pneumocephalus | | Without pneumocephalus | |
|----------------------|---------------------|--------------------|------------------------|------|
| | No. | % | No. | % |
| Postoperative result | | | | |
| Good (0-2) | 16 | 72.7 | 24 | 85.7 |
| Bad (3-4) | 6 | 27.3 | 4 | 14.3 |
| FEp | | 0.302 | | |
| OR (95% CI) | | 2.25 (0.55 – 9.26) | | |

FEp: P value for fisher exact test

2, 5 cases (23%) grade 3 and 4 cases (18%) grade 4 [Table 4]. Postoperatively, good results were found in 16 patients (73%), bad results in 6 patients (27%) [Table 5]. The two cases of tension pneumocephalus showed good postoperative results. Three patients with pneumocephalus died, two of them were grade 3 preoperative, and one patient was grade 4.

With regard to the 28 cases without pneumocephalus; preoperatively we had 9 cases (32%) grade 1, 15 (54%) cases grade 2, and 4 cases (14%) grade 3 [Table 4]. Postoperatively, good results were found in 24 patients (86%), bad results in 4 patients (14%) [Table 5]. One patient died postoperatively, and he was grade 3 preoperatively. No statistically significant difference in the outcome between patients who had pneumocephalus after surgery and those who had not.

Discussion

Chronic subdural hematoma (CSDH) represents one of the most frequent types of intracranial hemorrhage with a favorable prognosis when treated adequately.^[8] Pneumocephalus is commonly encountered after surgical evacuation of CSDH.^[4] Although simple pneumocephalus is typically asymptomatic, pneumocephalus of sufficient volume has been implicated in postoperative neurological insults.^[6] The latter refers to tension pneumocephalus which is a collection under pressure compared with the outside atmospheric pressure, when, in most circumstances, a valve mechanism allows air to enter the skull, but prevents it from escaping, thus creating a pressure differential.^[4] This makes a clear differentiation of simple pneumocephalus from tension pneumocephalus a very important issue as management of tension type is usually a surgical emergency unlike simple pneumocephalus which can be managed conservatively.^[4]

Incidence of immediate post-operative pneumocephalus

In the present series, surgical evacuation of CSDH was performed in 50 patients. The incidence of pneumocephalus in the immediate postoperative CT scan was found to be 44%. This was similar to what had been reported by Zakaraia *et al.*^[9] who reported a 40% incidence of pneumocephalus in a series of 40 patients treated with the burr hole craniotomy with

irrigation with drainage. A lower incidence of pneumocephalus had been reported by Miele *et al.*^[3] who operated 44 patients for CSDH using twist drill craniostomy with closed system drainage and found pneumocephalus in 6 patients (14%). Miele *et al.*^[3] did not use irrigation in their series and this can explain their lower incidence of pneumocephalus.

Incidence of pneumocephalus at time of discharge

The incidence of pneumocephalus in the CT scan performed at discharge in the present study was found to be 32%. This was in accordance with what was reported by Reasoner *et al.*^[10] who stated a gradual reduction of pneumocephalus in the follow-up CT scans.

Incidence of pneumocephalus at 2 months follow-up

In the present series, CT scan performed 2 months after surgery showed no cases of pneumocephalus. Similarly, Rychlicki *et al.*^[11] studied 65 patients with CSDH who underwent twist drill craniostomy and short lasting continuous drainage. They found full recovery with this in 63 cases with no pneumocephalus.

Mechanism, incidence, and clinical presentation of tension pneumocephalus

It is known that tension pneumocephalus can arise as a complication of burr-hole evacuation of chronic subdural hematoma. It is thought to be due to air entering the subarachnoid space through the tear of the inner membrane and the arachnoid membrane.^[12] The commonly proposed mechanism for the development of tension pneumocephalus is the ball valve mechanism. According to this, hypothesis air enters the intracranial cavity through a defect whenever the extra cranial pressure exceeds the intra cranial pressure (e.g. while sneezing or coughing). After the air has entered the intracranial cavity, the raised intracranial pressure forces the brain parenchyma under pressure to block the entry site. Thereby effectively trapping the intracranial air.^[13,14] As little as 25 ml of air is sufficient to cause tension pneumocephalus. Even partial replacement of fluid by air may cause neurological deterioration because the vulnerability of the brain to subdural air is quite variable from patient-to-patient and may actually involve more complex mechanisms rather than just physical compression.^[15]

Tension pneumocephalus was present in two cases (4%) among the 22 cases of pneumocephalus diagnosed in our series. This was consistent with what was reported in the literature^[16-18] which stated a range from 0 to 16% for this specific complication after surgical evacuation of CSDH.

In the present series, simple pneumocephalus was asymptomatic while the presentations of tension pneumocephalus included; severe headache, persistent

vomiting, and disturbed conscious level. Other presentations had been reported by Schirmer *et al.*^[4] and Standefer *et al.*^[6] who stated seizures, dizziness, hemiparesis, lethargy, and abducent nerve palsy as signs of tension pneumocephalus. Intracranial hypertension with downward herniation, air embolism, and cardiac arrest can be rarely associated with tension pneumocephalus.^[19,20]

Diagnosis of tension pneumocephalus

In the present series, pneumocephalus was classified into simple and tension based upon the clinical and radiological criteria. Mount Fuji sign seen on the CT scan as well as progressive neurological deterioration were the main specific signs to differentiate simple from tension pneumocephalus. Mount Fuji sign seen on the CT occurs when the subdural air separates and compresses the frontal lobes, creating a widened interhemispheric space between the tips of the frontal lobes that mimics the silhouette of Mount Fuji. The characteristic separation of the tips of the frontal lobes indicates that the tension of the air exceeds the surface tension of the CSF between the frontal lobes.^[14,21,22] Mount Fuji sign alone is not considered a diagnostic for tension pneumocephalus in the present study as it was present in four cases; only two of them were associated with neurological deficit and diagnosed as tension pneumocephalus while the other two cases were asymptomatic. Similarly, Sandeep *et al.*^[23] proposed that Mount Fuji sign does not always signify tension pneumocephalus and may be seen in a few subsets of patients with non-tension pneumocephalus. Other complex mechanisms rather than just physical compression of frontal lobes may be responsible for the clinical symptoms and require further elucidation. Pop *et al.*^[5] had proposed “Peaking sign” as another sign of tension pneumocephalus. “Peaking sign” is characterized by large collection of air over the anterior and lateral portion of bilateral frontal lobes causing its compression. The air does not cause any separation of the tips of the frontal lobe, thereby leading to an appearance of a single peak in the midline. Pop *et al.*^[5] thought that the peak was formed by bridging veins entering the superior sagittal sinus. In the present study, “Peaking sign” was not considered as sign of tension pneumocephalus as it was observed in two patients who showed a favorable prognosis and didn't require any specific treatment. Ishiwata *et al.*^[24] identified “Air Bubble sign” as a sign of tension pneumocephalus (the presence of multiple small air bubbles scattered through several cisterns). The air bubbles enter the subarachnoid space through a tear in the arachnoid membrane caused by increased tension of air in the subdural space. This sign was not seen in the present series. The present series was concomitant with what was reported by other authors^[17,22] who have concluded that Mount Fuji sign indicates more severe pneumocephalus than the Peaking sign and Air Bubble sign and this requires emergent management. Patients with suspected tension pneumocephalus should undergo serial imaging to ensure

gradual reduction of the volume of intracranial air. CT has proven to be a quick and reliable method to follow intracranial air collections.^[4]

Methods to decrease pneumocephalus

In our series, repeated saline irrigation and drainage were performed in all the cases. Postoperatively, drains were removed after 2–5 days. Zakaraia *et al.*^[9] compared the incidence of pneumocephalus with the burr hole craniotomy with irrigation with drainage with another technique of surgery without irrigation and drainage. They found a lower incidence of pneumocephalus with non irrigation group (26.2% versus 40%). The difference was not statistically significant. Similarly, Erol *et al.*^[2] compared the results of the cases of CSDH that underwent burr-hole craniostomy–irrigation (35 patients) with those undergoing burr-hole craniostomy–closed system drainage (35 patients). The postoperative pneumocephalus rate was higher in the irrigation group compared with non irrigation group (37% vs. 26%). The irrigation procedure may introduce air into the hematoma cavity increasing the incidence of pneumocephalus. The present study could not state this point as all the cases were operated using irrigation technique. It is thought that insertion of drainage tubes lead to tear of the arachnoid membrane and thus allowing air entering the subarachnoid space.^[12,24]

In the present series, the patients were nursed in a flat position postoperatively in an attempt to reduce the incidence of pneumocephalus by decreasing the potential space in the subdural area. This was matching with what was reported by Misra,^[25] however, others^[3,26,27] prefer to elevate the patient's head of bed during treatment to decrease the intracranial pressure. This helps to reduce the incidence of recurrence by decreasing the degree of venous congestion and thus reducing pneumocephalus.

Several methods have been reported for reducing the occurrence of pneumocephalus. These include; endolumbar infusion of isotonic saline, ringer's solution or air during surgery, hyperhydration of the patient, trendelenburg positioning of the patient with lowering of the head 30° horizontally and bed rest for up to a week, the replacement of the hematoma with carbon dioxide gas or oxygen, craniotomy without closure of the dura or replacing the bone plate, or an implant of a subcutaneous reservoir with a catheter introduced into the subdural cavity.^[17,18,26-31] The treatment of pneumocephalus with supplemental breathing of 100% O₂ had been demonstrated to be effective.^[4,6,32]

Treatment of pneumocephalus

In the present series, simple pneumocephalus did not require specific treatment, while in other two cases with tension pneumocephalus a specific management was followed. One case was managed conservatively in the form of adequate

hydration, nursing in a flat position, and supplemental breathing of 100% O₂. The second case was treated by simple aspiration of air using a syringe through the skin incision of the burr-hole. Similarly, Gelabert-González *et al.*^[8] had reported two cases (0.2%) of tension pneumocephalus in their retrospective study of 1000 patients harboring 1097 chronic subdural hematoma treated with burr-hole craniotomy with closed-system drainage. In one case, the air had to be aspirated through the burr-hole. Same finding was reported by Ishiwata *et al.*^[24] who treated tension pneumocephalus in their series by needle puncture of the subdural space through the frontal burr-hole. In contrast to the present study, Caron *et al.*^[17] presented a case of tension pneumocephalus after burr hole evacuation of bilateral chronic subdural hematomas. Their treatment was affected with combined twist drill closed system drainage and continuous intrathecal infusion of a physiological solution as a method of cerebral re-expansion. Also, Shaikh *et al.*^[33] reviewed 30 cases of tension pneumocephalus reported after burr-hole surgery for chronic subdural hematoma evacuation and all the patients had to undergo emergency decompression to reduce the increased subdural pressure due to tension pneumocephalus.

Pneumocephalus and recurrence

In the present study, recurrence of CSDH was observed in nine patients (18%). Pneumocephalus was a common finding in recurrent cases found in seven out of nine patients. Similarly, in Zakaraia *et al.*^[9] series, in the patients with pneumocephalus, the postoperative recurrence rate was 7.3%, while in patients without pneumocephalus, the postoperative recurrence rate was 4.9%. This study indicated that there was a slight increase in the recurrence rate in patients with pneumocephalus. The irrigation procedure may introduce air into the hematoma cavity increasing the incidence of pneumocephalus, and this air may inhibit brain expansion and increases the rate of recurrence. The difference in the outcome between the two groups was not statistically significant. Also, Stanisic *et al.*^[34] studied 99 patients with 121 CSDHs, and found that a large amount of residual subdural air within four days post-surgery was strongly correlated with a high postoperative recurrence rate (24.2%), although below the level of statistical significance.

Postoperative surgical results

In the present series, with regard to the 22 patients who had shown pneumocephalus; postoperative good results were found in 16 patients (73%), and bad results in 6 patients (27%). With regard to the 28 cases without pneumocephalus, postoperative good results were found in 24 patients (86%), bad results in 4 patients (14%). The two cases of tension pneumocephalus showed good postoperative results. No statistically significant difference in the outcome had been found between patients who had pneumocephalus after surgery and those who had not.

Conclusion

Pneumocephalus after surgical evacuation of CSDH is a common finding in the immediate CT scan as well as at time of discharge. Pneumocephalus is commonly associated with patients over 60 years as well those presenting with midline shift more than 5 mm on CT scan. Most cases of pneumocephalus are asymptomatic and respond to conservative therapy. In the present series, persistent headache and disturbed sensorium together with Mount Fuji sign in the CT scan were diagnostic for tension pneumocephalus. Tension pneumocephalus may not require surgical intervention and simple aspiration of air using a syringe may be sufficient for treatment. CT scans performed immediately postoperative as well as before discharge are important to exclude pneumocephalus as a cause for neurological deterioration after surgical evacuation of CSDH.

References

1. Nobuhiko A. Chronic subdural haematoma in infancy. Clinical analysis of 30 cases in CT-era. *J Neurosurg* 1990;73:201-5.
2. Erol FS, Topsisakal C, Faik Ozveren M, Kaplan M, Tiftikci MT. Irrigation vs. closed drainage in the treatment of chronic subdural hematoma. *J Clin Neurosci* 2005;12:261-3.
3. Miele VJ, Sadrolhefazi A, Bailes JE. Influence of head position on the effectiveness of twist drill craniostomy for chronic subdural hematoma. *Surg Neurol* 2005;63:420-3.
4. Schirmer CM, Heilman CB, Bhardwaj A. Pneumocephalus: Case illustrations and review. *Neurocrit Care* 2010;13:152-8.
5. Pop PM, Thompson JR, Zeinke DE, Hasso AN, Hinshaw DB. Tension pneumocephalus. *J Comput Assist Tomogr* 1982;6:894-901.
6. Standefer M, Bay JW, Trusso R. The sitting position in neurosurgery: A retrospective analysis of 488 cases. *Neurosurgery* 1984;14:649-58.
7. Markwalder TM, Steinsiepe KF, Rohner M, Reichenbach W, Markwalder H. The course of chronic subdural hematomas after burr-hole craniostomy and closed system. *J Neurosurg* 1981;55:390-6.
8. Gelabert-González M, Iglesias-Pais M, García-Allut A, Martínez-Rumbo R. Chronic subdural haematoma: Surgical treatment and outcome in 1000 cases. *Clin Neurol Neurosurg* 2005;107:223-9.
9. Zakaraia AM, Adnan JS, Haspani MS, Naing NN, Abdullah JM. Outcome of 2 different types of operative techniques practiced for chronic subdural hematoma in Malaysia: An analysis. *Surg Neurol* 2008;69:608-16.
10. Reasoner DK, Todd MM, Scamman FL, Warner DS. The incidence of pneumocephalus after supratentorial craniotomy. Observations on the disappearance of intracranial air. *Anesthesiology* 1994;80:1008-12.
11. Rychlicki F, Recchioni MA, Burchianti M, Marcolini P, Messori A, Papo I. Percutaneous twist drill craniostomy for treatment of chronic subdural haematoma. *Acta Neurochir* 1991;113:38-41.
12. Kawakami Y, Tamiya T, Shimamura Y, Yokoyama Y, Chihara T. Tension pneumocephalus following surgical evacuation of chronic subdural hematoma. *No Shinkei Geka* 1985;13:833-7.
13. Aoki N, Sakai T. Computed tomography feature immediately after replacement of haematoma with oxygen through percutaneous subdural tapping for the treatment of chronic subdural haematoma in adults. *Acta Neurochir* 1993;20:44-6.
14. Hong W, Yoo C, Park C, Lee S. Two cases of delayed tension pneumocephalus. *J Korean Neurosurg Soc* 2005;37:59-62.
15. Delgado JM, Ingley AP. Treatment of pneumocephalus after endoscopic sinus and microscopic skull base surgery. *Am J Otolaryngol* 2010;31:226-30.
16. Thapa A, Agrawal B. Mount Fuji Sign in tension pneumocephalus. *Indian J Neurotrauma* 2009;6:161-2.
17. Caron JL, Worthington C, Bertrand G. Tension pneumocephalus after

- evacuation of chronic subdural haematoma and subsequent treatment with continuous lumbar subarachnoid infusion and craniostomy drainage. *Neurosurgery* 1985;16:107-10.
18. Lavano A, Benvenuti D, Volpentesta G, Donato G, Marotta R, Zappia M, *et al.* Symptomatic tension pneumocephalus after evacuation of chronic subdural haematoma: Report of seven cases. *Clin Neurol Neurosurg* 1990;92:35-41.
 19. Thiagarajah S, Frost EA, Singh T, Shulman K. Cardiac arrest associated with tension pneumocephalus. *Anesthesiology* 1982;56:73-5.
 20. Cipriani NA, Hong AC, Rosenblum J, Pytel P. Air embolism with pneumocephalus. *Arch Neurol* 2009;66:1172-3.
 21. Eltorai IM, Montroy RE, Kaplan SL, Ho WH. Pneumocephalus secondary to cerebrospinal fluid leak associated with a lumbar pressure ulcer in a man with paraplegia. *J Spinal Cord Med* 2003;26:262-9.
 22. Yamashita S, Tsuchimochi W, Yonekawa T, Kyoraku I, Shiomi K, Nakazato M. The Mount Fuji Sign on MRI. *Intern Med* 2009;48:1567-8.
 23. Jakhere SG, Yadav DA, Jain DG, Balasubramaniam S. Does the Mount Fuji Sign always signify 'tension' pneumocephalus? An exception and a reappraisal. *Eur J Radiol Extra* 2011;78:e5-7.
 24. Ishiwata Y, Fujitsu K, Sekino T, Fujino H, Kubokura T, Tsubone K, *et al.* Subdural tension pneumocephalus following surgery for chronic subdural hematoma. *J Neurosurg* 1988;68:58-61.
 25. Misra BK. What is the best option for recurrent chronic subdural hematoma? *World Neurosurg* 2010;73:640-1.
 26. Stoodley M, Weir B. Contents of chronic subdural hematoma. *Neurosurg Clin N Am* 2000;11:425-34.
 27. Ueno K, Murata J, Sakuma S, Takano K, Lizuka T. Intraoperative lumbar injection of Ringer's solution for surgical treatment of chronic subdural haematomas. *Neurol Surg* 1991;19:511-6.
 28. Kitakami A, Ogawa A, Hakozaiki S, Kidoguchi J, Obonai C, Kubo N. Carbon dioxide gas replacement of chronic subdural haematoma using single burr-hole irrigation. *Surg Neurol* 1995;43:574-8.
 29. Aoki N. A new therapeutic method for chronic subdural haematoma with oxygen via percutaneous subdural tapping. *Surg Neurol* 1992;38:253-6.
 30. Beatty RA. Subdural haematomas in the elderly: Experience with treatment by trephine craniotomy and not closing the dura or replacing the bone plate. *Br J Neurosurg* 1999;23:60-4.
 31. Sato M, Iwatsuki K, Akiyama CH, Kumura E, Yoshimine T. Implantation of a reservoir for refractory chronic subdural haematoma. *Neurosurgery* 2001;48:1297-301.
 32. Gore PA, Maan H, Chang S, Pitt AM, Spetzler RF, Nakaji P. Normobaric oxygen therapy strategies in the treatment of postcraniotomy pneumocephalus. *J Neurosurg* 2008;108:926-9.
 33. Shaikh N, Ummunnisa F, Masood I, Hanssens Y. Tension pneumocephalus as complication of burr-hole drainage of chronic subdural hematoma: A case report. *Surg Neurol Int* 2010;1:27.
 34. Stanisic M, Lund-Johansen M, Mahesparan R. Treatment of chronic subdural hematoma by burr-hole craniostomy in adults: Influence of some factors on postoperative recurrence. *Acta Neurochir* 2005;147:1249-57.

How to cite this article: Ihab Z. Pneumocephalus after surgical evacuation of chronic subdural hematoma: Is it a serious complication?. *Asian J Neurosurg* 2012;7:66-74.

Source of Support: Nil, **Conflict of Interest:** None declared.