

CASE REPORT

Acute closed radial nerve injury

Umut Tuncel, Aydin Turan, Naci Kostakoglu

Department of Plastic Reconstructive and Aesthetic Surgery, Gaziosmanpasa University, Faculty of Medicine 60100, Tokat, Turkey

ABSTRACT

We present a 45-year-old patient who had acute radial nerve palsy following a blunt trauma without any fracture or dislocation. He was injured by striking in a combat three months ago. The patient has been followed by application of a long-arm plaster cast before referred to our clinic. Preoperative electromyoneurography and magnetic resonance imaging (MRI) indicated that there was a radial nerve injury on humeral groove. The British Medical Research Council (MRC) grade was 2/5 on his wrist preoperatively. The patient underwent an operation under general anesthesia. It was seen to be a second-degree nerve injury. The patient has subsequently regained full movement on his wrist and finger extension in six months. We suggest that a detailed clinical and electrodiagnosical evaluation is necessary in patients who have radial nerve injury when deciding the treatment, conservative or surgical.

Key words: Blunt trauma, compression, injury, pressure, radial nerve

Introduction

The radial nerve originates from the posterior cord of the infraclavicular brachial plexus provides the motor branches to the extensor muscles of arm and forearm. The nerve is responsible for the skin sensation over the dorsal surface of arm, forearm, wrist and hand. It can have communications with the intercostobrachial nerve, lateral antebrachial cutaneous nerve, and ulnar nerve.^[1,2] Owing to the communications, radial nerve paralysis cause loss of extension of the elbow, wrist and digits, but causes little sensory loss.

The radial nerve is the most frequently injured nerve in the upper extremity. Proximal part of the radial nerve injuries can result from a humerus fracture, direct trauma, and compression and rarely from tumors.^[2-4] Also, the radial nerve can be injured directly by stretch, division, rupture or avulsion, and indirectly along with a fracture and/or its manipulation and fixation.

We present an unusual case that has totally radial nerve palsy due to the blunt trauma on his upper arm. The pattern of the closed injury was attributed to contusion, direct trauma of the nerve resulting with axonamionosis. Non-degenerative nerve lesions which are named axonamionosis have been described in the literature.^[3] Axonamionosis represents a block to conductivity due to direct pressure on a nerve resulting in mechanical extrusion of myelin from a section of the nerve. Rapid recovery can be explained by the restoration of the myelin when the mechanical pressure is removed.^[3] In our case, the lesion was characterized by partial discontinuity pattern and thus full recovery was obtained by internal neurolysis and removing injured perineurium in six months.

Case Report

Pain and swelling immediately following blunt trauma appeared in a 45-year-old right handed patient. His past medical history revealed that he had been injured in a combat and struck on his left arm three months ago. He applied at the emergency department the following day because a weakness developed on his left wrist. On examination, his upper arm was swollen, tender, and ecchymotic. Unable of active finger and wrist extension with anesthesia over the first web space dorsally were observed. An X-ray did not show any fracture of humerus. A static splinting was initiated immediately to facilitate radial nerve recovery. Because the radial nerve injury could not be resolved, the patient was referred to our clinic posttraumatic three months. On our examination, wrist and finger extension was grade 2/5. Range of motion of his elbow and wrist was 10% of normal [Figure 1]. Magnetic Resonance Imaging (MRI) and Electromyoneurography EMNG noticed the moderate

Access this article online

Quick Response Code:



Website:

www.asianjns.org

DOI:

10.4103/1793-5482.92175

Address for correspondence:

Dr. Umut Tuncel, Department of Plastic Reconstructive and Aesthetic Surgery, Gaziosmanpasa University, Faculty of Medicine 60100, Tokat, Turkey. E-mail: drumuttuncel@gmail.com

nerve lesion on the humeral groove. The ENMG showed amplitude of motor nerve conduction velocity was low. Therefore, the patient underwent an operation. It was seen to be second-degree injury of the nerve in operation [Figure 2]. The nerve was edematous and contused. The lesion was characterized by partial discontinuity of axons internally. Epineurium has been disrupted on the traumatized area. Injured epineurium was removed from the area of the lesion and internal neurolysis was performed to the nerve. He was discharged postoperative three days and followed six months with a dynamic splinting. The patient has subsequently regained approximately full movement on his wrist and finger extension in six months after the operation [Figure 3].

Discussion

Dysfunction of peripheral nerves results from damage to the neuron.^[5] There are many mechanisms of injury to peripheral nerves. Each mechanism of injury cause specific nerve damage.

The first mechanism of nerve injury is mechanical injury. "Saturday-night paralysis" and tourniquet paralysis are two examples of mechanical injury.^[6] In a study by Kurihara and Goto, the authors reported radial nerve paralysis in 2 patients with previous humeral fractures after tourniquet use^[7] and the mechanical injury resulted in focal conduction block related to an acute compression injury.

The second mechanism of injury is crush injury. In crush injuries, fractures, hematomas, and compartment syndrome is among the causes. Compartment syndrome injuries cause high pressure in the surrounding tissue. In compartment syndrome injuries, pressure compresses the arterial blood supply of the nerve, predisposing the nerve to ischemic cell damage and cell death.^[8] Although the peripheral nervous system is relatively resistant to ischemia, long periods of stretch and compressive force can result in vascular compromise and neuronal ischemia.^[9] In case of delaying the treatment of compartment syndrome, it can lead to nerve injury in the forearm. Concussion or compression of the nerve causes neurapraxia. Other causes of neurapraxia include ischemia secondary to vascular compromise, metabolic derangement, and diseases or toxins causing demyelination of the nerve.^[9]

The third mechanism of injury is penetrating traumas. In this kind of injuries, peripheral nerves are partially or completely severed. Stab wound lacerations by glass and surgical incisions cause penetrating traumas.^[6,10] The nerves in these kind of injuries are not cleanly sectioned but are damaged in an irregular pattern.

The other mechanism of injury is stretch injury. The internal anatomy of nerves can permit the nerve to stretch approximately 10-20% before structural damage occurs.^[9] Stretch injury to a nerve cause axonotmesis. In axonotmesis,

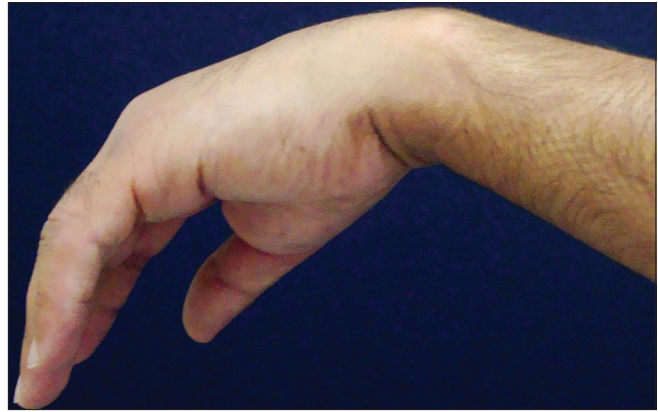


Figure 1: Preoperative appearance of the patient

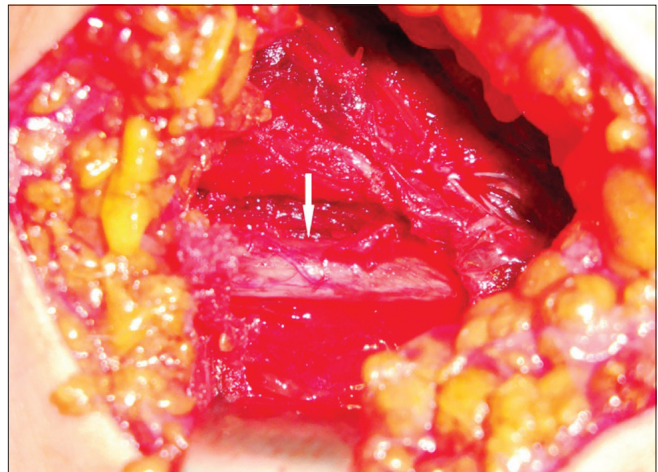


Figure 2: The white arrow shows epineurium was disrupted on the traumatized area

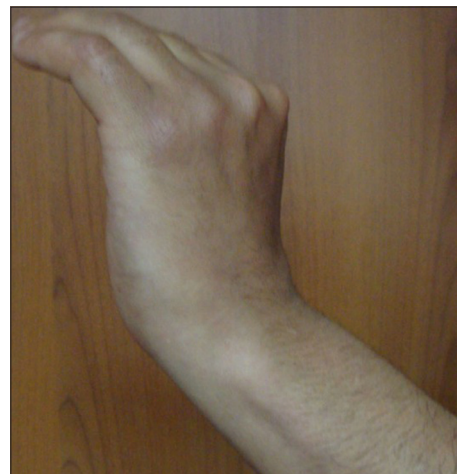

Figure 3: Shows early postoperative result

axons over long segments of nerve are disrupted and in cases of causing by severe blows, axons are disrupted only at the site of impact.^[8] Stretch injuries can be induced by traction as well. Displacement of fractures and dislocated joints can occur by stretch injury to peripheral nerves. Stretch injuries may result in during operative or other surgical procedures.^[6,7]

Classification of nerve injury depends on the damage sustained by the nerve components, nerve functionality, and the ability for spontaneous recovery.^[9,10] The grading system was published by Seddon, and expanded by Sunderland. The mildest grade is called neurapraxia. Neurapraxia is a reduction or complete block of conduction across a segment of a nerve with axonal continuity conserved.^[9,11] It is dysfunction and/or paralysis without loss of nerve sheath continuity and peripheral wallerian degeneration.^[12] Nerve conduction is maintained both proximal and distal to the lesion but not across the lesion.^[9] Axonotmesis is a more severe grade of nerve injury when compared with neurapraxia. Axonotmesis is a result of damage to the axons with preservation of the neural connective tissue sheath.^[8,9] Thus, the internal architecture is relatively preserved.^[12] Distal wallerian degeneration occurs in axonotmesis. The most severe grade of peripheral nerve injury is neurotmesis which occurs when the axon, myelin, and connective tissue components are damaged and disrupted or transected.^[7,12] Recovery through axonal regeneration cannot occur in neurotmesis. This grade of injury includes nerve lesions in which external continuity is preserved but intraneural fibrosis occurs and blocks axonal regeneration.^[12] Sunderland classified nerve injuries into five grades. Grades I and II correspond to Seddon's neurapraxic and axonotmetic grades of injury. Sunderland further divided Seddon's category of neurotmesis injuries into grades III, IV, and V based on the extent of damage to the axonal supporting structures.^[9] In grade III injuries, axon continuity is disrupted by loss of endoneurial tubes but the perineurium is protected. In these injuries, when the axons regenerate, they may enter an incorrect nerve sheath, resulting in abnormal regeneration. Intraneural scarring occurs accompanying the loss of the nerve sheath, which further obstructs axonal regrowth through the site of injury.^[8] In grade IV injuries, nerve fasciculi are damaged but nerve sheath continuity is maintained. However, intraneural scarring occurs.^[11] In grade V injuries, the endoneurium, perineurium, and epineurium are completely divided.^[7] Grade V corresponds to Seddon's classification of a neurotmesis lesion and in this grade of injury substantial perineural hemorrhage and scarring occur.

Surgical treatment for acute nerve injury is based on the extent of damage to the nerve and the nerve's functional viability. The location, the extent of the injury, the patient's age, and the patient's medical condition should be considered. Before surgery are whether function can be obtained from the repaired nerve and whether the potential benefit to the patient outweighs the surgical risks, costs, and loss of productivity is two important questions.^[12,13]

It is quite important to decide the timing of surgery in closed nerve injuries. In open lacerating injuries in which the nerve ends are visible in the wound immediate primary repair is indicated. However, in blunt transections resulting

from lacerations, a better surgical result may be obtained with delayed repair.^[14,15] Injuries that do not demonstrate evidence of early spontaneous recovery, such as those caused by crushing blows, traction, fractures, or injections, should be explored two months after the injury. Therefore, an additional delay of one month may be justified before surgical exploration. Because nerves in the elbow are anatomically vulnerable, many researchers recommend early surgical exploration after fractures of the humerus^[7]. In these cases, late exploration can be considered to allow sufficient time for spontaneous recovery. Different opinions exist with regard to how much time to allow for nerve function to return. If nerve function does not return within 1 week, surgical exploration is advised. On the other hand, Bromberg and Weiss suggested surgical exploration if nerve function has not returned within an 8- to 10-month period.^[16] Therefore, surgery should be done for patients who symptoms persist although appropriate conservative treatment. In cases of late nerve dysfunction from heterotopic ossification or scar tissue, several authors recommend surgical exploration as soon as the diagnosis becomes evident.^[16] Surgical intervention is indicated for patients with neurotmesis which corresponds to grade III-V according to the grading system of Sunderland. Therefore, accurate grading of an acute traumatic injury is essential and it is necessary for identifying high-grade injuries that may benefit from early surgery and for preventing unnecessary early exploration of grade I and II lesions.^[7] Evaluation of nerve injuries is important when deciding whether surgery will perform or not. If nerve function is progressively deteriorating as per electrodiagnostic study findings, surgery is indicated because the status of the connective tissue cannot be assessed without direct exploration. Also, surgery should not be performed when a poor outcome is expected.^[15]

In the present study, we report the patient who had radial nerve palsy about three months ago. The palsy began after he had a blunt trauma on his arm. X-ray did not show any fracture or any other bone pathology. But repeated EMNG tests indicated that there was a lesion of radial nerve at the level of the spiral groove and it was still moderate following three months. During the operation, the nerve was observed to be partial injured. The injured epineurium was removed from the area of the lesion and internal neurolysis was performed microsurgically. According to the literature, the optimal time for radial nerve exploration in closed injuries is controversial. An interval of six to eight weeks, two to three months, four to five months or even eight months have been suggested. Our experience suggests that the most appropriate time of exploration and nerve reconstruction is on the time when any clinical and/or electrodiagnostical improvement is not observed within three months. If the nerve is transected or injured, or if the recovery cannot be seen after three months, the nerve should be explored. If it is likely that the radial nerve is transected, early nerve exploration is mandatory.

When the nature of the injury of the radial nerve cannot be determined, repeated assessments are essential.^[17] If a Tinel's sign remains stationary over a few months, exploration is indicated.^[18] Electrodiagnostical studies are rarely helpful within the first three months. The clinical presentation and the type of the nerve injury are of importance to give the patient an appropriate treatment. In conclusion, we suggest a detailed clinical and electrodiagnostical evaluation should be performed to decide if the treatment is conservative or surgical.

References

- Green DP. Radial nerve palsy. In: Green DP, Hotchkiss RN, (Editors.) Operative hand surgery. New York: Churchill Livingstone; 1993. p. 1401-17.
- Pan CH, Chuang DC, Rodriguez Lorenzo A. Outcomes of nerve reconstruction for radial nerve injuries based on the level of injury in 244 operative cases. *J Hand Surg Eur* 2010;35:385-91.
- Marsh AJ, Singh B, Iossifidis A. Rapid nerve recovery following decompression—a case of post-traumatic axonotmesis. *Int J Clin Pract* 2004;58:96.
- Peel N, Kandler R. Localized neuropathy following jellyfish sting. *Postgrad Med J* 1990;66:953-4.
- Berkow R, editor. The Merck Manual of Medical Information. Whitehouse Station, NJ: Merck and Co; 1997. p. 330.
- Tuncali BE, Tuncali B, Kuvaki B, Cinar O, Doğan A, Elar Z. Radial nerve injury after general anaesthesia in the lateral decubitus position. *Anaesthesia* 2005;60:602-4.
- Ristic S, Strauch RJ, Rosenwasser MP. The assessment and treatment of nerve dysfunction after trauma around the elbow. *Clin Orthop Relat Res* 2000;370:138-53.
- Colohan AR, Pitts LH, Rosegay H. Injury to the peripheral nerves. In: Feliciano DV, Moore EE, Mattox KL, Editors. *Trauma*. 3rd ed. Stamford, Conn: Appleton and Lange; 1996. p. 853-62.
- Grant GA, Goodkin R, Kliot M. Evaluation and surgical management of peripheral nerve problems. *Neurosurgery* 1999;44:825-39; discussion 839-40.
- Greenfield LJ. *Surgery: Scientific Principles and Practice*. 2nd ed. Philadelphia, Pa: Lippincott-Raven; 1997. p. 2172-3.
- Ciaramitaro P, Mondelli M, Logullo F, Grimaldi S, Battiston B, Sard A, *et al.* Italian Network for Traumatic Neuropathies. Traumatic peripheral nerve injuries: Epidemiological findings, neuropathic pain and quality of life in 158 patients. *J Peripher Nerv Syst* 2010; 15:120-7.
- Schwartz SI. *Principles of Surgery*. 7th ed. New York, NY: McGraw-Hill; 1999. p. 2048-53.
- Perlmutter GS. Axillary nerve injury. *Clin Orthop* 1999;368:28-36.
- Artico M, Cervoni L, Nucci F, Giuffrè R. Birthday of peripheral nervous system surgery: The contribution of Gabriele Ferrara (1543-1627). *Neurosurgery* 1996;39:380-2; discussion 382-3.
- Trumble TE. Peripheral nerve injury: Pathophysiology and repair. In: Feliciano DV, Moore EE, Mattox KL, editors. *Trauma*. 4th ed. New York, NY: McGraw-Hill; 2000. p. 1047-55.
- Cornwall R, Radomski TE. Nerve injury in traumatic dislocation of the hip. *Clin Orthop* 2000;377:84-91.
- Berry H, Bril V. Axillary nerve palsy following blunt trauma to the shoulder region: A clinical and electrophysiological review. *J Neurosurg Psychiatry* 1982;45:1027-32.
- Mast JW, Spiegel PG, Harvey JP Jr, Harrison C. Fractures of the humeral shaft: A retrospective study of 240 adult fractures. *Clin Orthop Relat Res* 1975;112: 254-61.

How to cite this article: Tuncel U, Turan A, Kostakoglu N. Acute closed radial nerve injury. *Asian J Neurosurg* 2011;6:106-9.

Source of Support: Nil, **Conflict of Interest:** None declared.

Author Help: Reference checking facility

The manuscript system (www.journalonweb.com) allows the authors to check and verify the accuracy and style of references. The tool checks the references with PubMed as per a predefined style. Authors are encouraged to use this facility, before submitting articles to the journal.

- The style as well as bibliographic elements should be 100% accurate, to help get the references verified from the system. Even a single spelling error or addition of issue number/month of publication will lead to an error when verifying the reference.
- Example of a correct style
Sheahan P, O'leary G, Lee G, Fitzgibbon J. Cystic cervical metastases: Incidence and diagnosis using fine needle aspiration biopsy. *Otolaryngol Head Neck Surg* 2002;127:294-8.
- Only the references from journals indexed in PubMed will be checked.
- Enter each reference in new line, without a serial number.
- Add up to a maximum of 15 references at a time.
- If the reference is correct for its bibliographic elements and punctuations, it will be shown as CORRECT and a link to the correct article in PubMed will be given.
- If any of the bibliographic elements are missing, incorrect or extra (such as issue number), it will be shown as INCORRECT and link to possible articles in PubMed will be given.