

## CASE REPORT

# Low velocity penetrating head injury with impacted foreign bodies *in situ*

Rashim Kataria, Deepak Singh, Sanjeev Chopra, V. D. Sinha

Department of Neurosurgery, SMS Medical College, Jaipur, Rajasthan, India

## ABSTRACT

Penetrating head injury is a potentially life-threatening condition. Penetrating head injuries with impacted object (weapon) are rare. The mechanism of low velocity injury is different from high velocity missile injury. Impacted object (weapon) *in situ* poses some technical difficulties in the investigation and management of the victims, and if the anticipated problems are not managed properly, they may give rise to serious consequences. The management practice of eight patients with impacted object *in situ* in context of earlier reported similar cases in literature is presented.

**Key words:** Impacted weapon *in situ*, low-velocity penetrating head injury, skull stab wound

## Introduction

Brain is perforated by almost every conceivable object.<sup>[1]</sup> Gun-shot penetrating injuries are common but low-velocity penetrating injuries to the brain are rare in the western countries.<sup>[2]</sup> Incidence of low-velocity penetrating head injury cases in India and other under developing countries are usual particularly in rural areas due to interpersonal assault. The patients with the impacted assault weapon or foreign bodies rarely reach for surgery. Impacted object (weapon) poses difficulties in the investigation and normal operating procedure. If the impacted object is not removed carefully, it can cause further damage to the cerebral tissue or may lead to vascular injury. Unlike the penetrating injuries to the brain caused by missiles, injuries by stabbing are largely restricted to the wound tract. Early recognition, debridement, and judicious antibiotic therapy can limit or prevent complications in the management of stab wounds.

## Case Report

Eight patients of low-velocity penetrating head injury with impacted object *in situ* were admitted in

the neurosurgical department of SMS Hospital, Jaipur, Rajasthan, India, during 10-year period (1995 to 2006). The surgery and management practice adopted in context of earlier reported similar cases is mentioned in the following [Table 1].

## Discussion

Transcranial penetrating wounds are though not common but well known.<sup>[2]</sup> The method of killing a person by driving nails into the brain can be found in the Holy Bible, where it is described in the Book of Judges.<sup>[3]</sup> This method is also depicted in the novel "By the open sea"<sup>[4]</sup> of a well-known Swedish author, August Strindberg (1849-1912) with reference to the violent act as "the good old method of the nail" suggesting that the method has been known for long time in Sweden. Gun-shot injuries are more prevalent in the united states, with firearm injury being the second only to motor vehicle collisions in causing traumatic deaths.<sup>[5]</sup> In South Africa, because of very strict gun control laws, stab wounds of skull from sharp edge weapons are relatively common.<sup>[6]</sup>

Pilcher<sup>[1]</sup> observed that transcranial stab wounds have been caused by a variety of objects commonest being the knife blade. Others include pitch fork prongs,<sup>[7]</sup> door keys,<sup>[8]</sup> fishing harpoon,<sup>[9]</sup> rotor fan blade,<sup>[10]</sup> grinder tool,<sup>[11]</sup> ceramic stone,<sup>[12]</sup> iron rod, nail,<sup>[13,14]</sup> hunting arrow,<sup>[15]</sup> wood,<sup>[16]</sup> toilet brush handle,<sup>[17]</sup> coat hanger,<sup>[18]</sup> bicycle brake handle,<sup>[19,20]</sup> stone,<sup>[21]</sup> mains plug,<sup>[22]</sup> etc. In our cases, the assault weapons included sickle, scissors, compass, fan blade, metal strip, wood, and stone.

Penetrating head injuries of the head and neck are uncommon in children but are potentially life threatening. They are usually seen in adults.<sup>[23]</sup> The incidence of septic complication in children is significantly higher than that seen in adults.<sup>[24]</sup>

### Access this article online

#### Quick Response Code:



#### Website:

www.asianjns.org

#### DOI:

10.4103/1793-5482.85635

### Address for correspondence:

Dr. Rashim Kataria, Department of Neurosurgery, 53, Mauji Colony, Malviya Nagar, Jaipur, Rajasthan, India. E-mail: rashim\_kat@yahoo.com

**Table 1: Age, sex, mode of injury, impacted object, investigations, operation done and outcome**

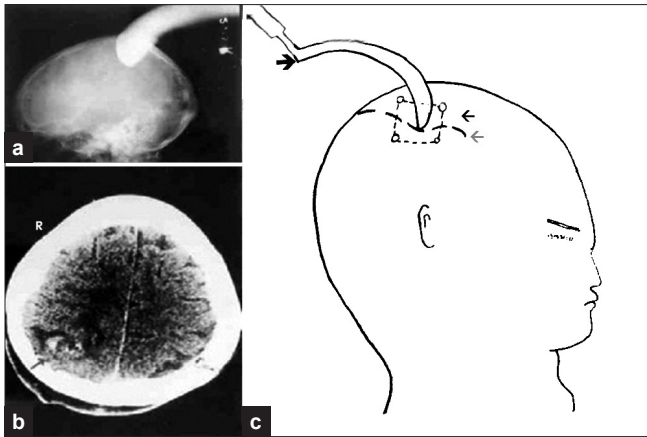
Case	Clinical picture	Radiological findings	Procedure done	Results
18 year male	Assault with sickle, conscious mild weakness of the left upper limb and lower limb	X-ray skull: Sickle in right parietal region [Figure 1a]. CT scan could not be done because of large handle of the sickle. Postoperative CT scan: Small contusion at the site of impaction [Figure 1b]	Multiple burr holes made around the entry point of the sickle into the skull. Craniotomy done and sickle removed [Figure 1c]. Dura closed with the help of the pericranial patch	Discharged from the hospital after 7 days with power 4 +/5 on the left side
7 year male	Assault by classmate with the compass (caliper) on right temporal region.	X-ray skull: Showed the compass going to the right temporal region [Figure 2a]. CT scan: Compass in the right temporal region near the sylvian fissure, no Intracerebral hematoma (ICH) seen. Cerebral angiography: no vascular injury	Multiple burr holes were made and craniectomy done all around it. Compass removed with bone. Dura closed primarily	Uneventful recovery discharged without neurological deficit
40 year male	Suicide, schizophrenic. scissor impacted over the vertex	X-ray skull: Scissors in midline going intracranial in the parietal region. CT scan [Figure 3a and b]: Scissor going into the superior saggital sinus in the parietal region. No intra cerebral hematoma seen	Multiple burr holes were made and craniotomy done. Scissors along with the bone was removed smoothly. Rent in the Superior saggital sinus sealed with oxidized cellulose and absorbable gelatin sponge	Uneventful recovery discharged without neurological deficit
30 year male	Accidental impaction of fan blade that broke off and flew to the patient left frontal region: unconscious, right hemiparesis	X-ray skull: Blade in the left frontal region [Figure 4a] CT scan: Metal artifact hence not much informative	Craniectomy done all around the metal fragment [Figure 4a] and fan blade was delivered. Frontal lobe was contused hence a frontal lobectomy was done	Gradually improved and was discharged in a conscious state with mild hemiparesis on the right side
2 year male	Fall from height, head landed over a metal strip with nails protruding out, left frontal region: conscious, crying. [Figure 5]	X-ray skull: Multiple nails penetrating the skull in the left frontal region. CT scan: no ICH	The metal strip along with the nails was pulled in the operation theatre and patient was watched for neurological status and serial CT scans	Uneventful recovery discharged without neurological deficit
2 year male	Fall from height, head landed over a pointed branch of a dried up tree: conscious	X-ray skull: Bone defect in the right parietal region [Figure 6a]. CT scan: Hypodensity (mimicking air) along with underlying contusion in right parietal region [Figure 6b]	Craniectomy [Figure 6c] done and wooden piece [Figure 6] recovered contusion sucked away. Duroplasty done	Uneventful recovery discharged without neurological deficit
2 year male	Fall from height, head landed on a stone. Left frontal region: conscious	X-ray skull: Bone defect and radio opaque shadow in the left frontal region [Figure 7a]. CT scan: Hyper dense lesion with bone defect in the left frontal region	Multiple burr holes were made, craniotomy done [Figure 7c], and the stone [Figure 7b] delivered. Duroplasty done	Uneventful recovery discharged without neurological deficit
5 year male	Fall from height, head struck to the stone in the left frontal region [Figure 8a]	X-ray skull: Bone defect and radio opaque shadow in the left frontal region [Figure 8b and c]. CT scan: hyper dense lesion with bone defect in the left frontal region	Craniectomy and delivery of impacted stone with repair of the dural defect done [Figure 8d]	Uneventful recovery discharged without neurological deficit

stab wounds passing through an air sinus or oropharyngeal mucosa before entering cranium increase wound infection in contrast to calvarial stab. The most commonly encountered types of penetrating head injuries are industrial accidents, suicidal attempts, and assault.

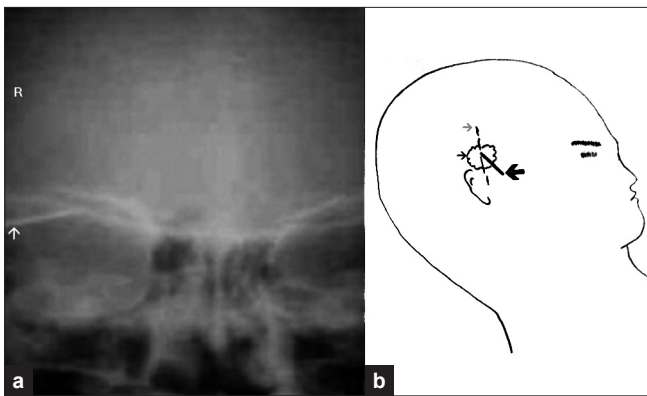
High incidences of stab on the left side of skull are probably due to right-handedness of the assailant except when the victim is hit from the back.<sup>[25]</sup> The most common injury site is the frontoparietal region.<sup>[25]</sup> Temporal stab wounds are more likely to demonstrate major neurological deficits. Penetration is facilitated by thinness of the temporal bone and because of short distance to the deep vital brain and

vascular structures.<sup>[26]</sup> Stab wounds at the craniocervical junction are also reported.<sup>[27]</sup> Intracranial complications of transorbital stab wounds include meningitis, injury to the carotid artery leading to carotid cavernous fistula, false aneurysm of the artery, and injury to the cavernous sinus.<sup>[28]</sup>

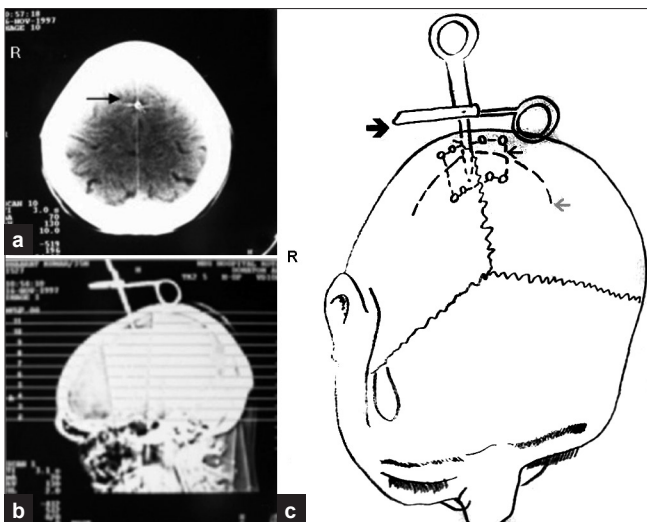
Injuries caused by stab wound evoke similar therapeutic consideration as in cases of missile injuries but these are modified primarily by a general absence of significant impact force and its deleterious secondary consequence resulting in good recovery. The kinetic energy ( $\frac{1}{2} \times \text{mass} \times \text{velocity}^2$ ) by an object dissipated into the tissues determines the



**Figure 1:** (a) X-ray skull (lat view) showing sickle *in situ*. (b) CT Scan head (Postoperative) after removal of the sickle, shows small contusion (arrow) at the operated site. (c) Line diagram of the skin incision (white arrow), craniotomy (thin black arrow)



**Figure 2:** (a) X-ray skull (AP view) showing compass *in situ* in the right temporal region (arrow) (b) Line diagram of the skin incision (white arrow), craniotomy done (thin black arrow) around the needle of compass (thick black arrow)



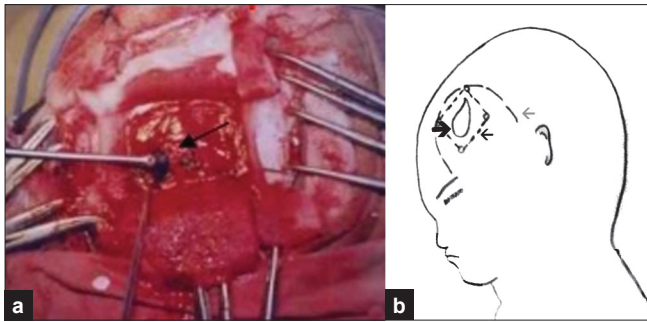
**Figure 3:** (a) CT scan head axial cut showing metal artifact in the midline (thin black arrow) (b) CT scan (topogram) head showing scissors *in situ* (c) Line diagram of the skin incision (white arrow), craniotomy (thin black arrow)

type of injury inflicted. Thus, velocity squarely affects the tissue destruction. At low velocity (i.e, below 300 m/sec) injury results from direct disruption and laceration of tissues while at high velocities, tissue cavitation and shock waves are the main cause of cerebral damage and poor prognosis.

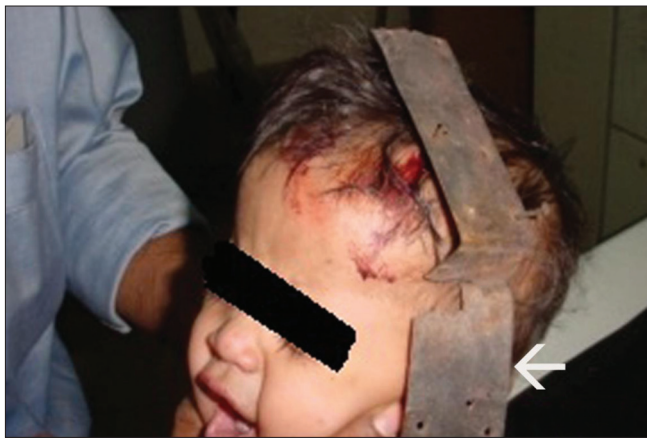Immediate radiological examination is mandatory because small entrance wound usually does not correspond with size of the foreign body and associated intracranial injury. A trivial wound in an asymptomatic patient may lead to death within few days to weeks later because of rupture of a traumatic intracranial aneurysm or infection.<sup>[29]</sup> Plain radiograph of the skull is useful to delineate the depth and direction of penetration.<sup>[2]</sup> It quickly reveals the presence of slot fracture beneath a trivial scalp laceration. CT scan is mandatory to diagnose intracranial injuries, associated contusion, hematoma, major vascular injury, or brainstem injury. It is an essential means in decision making of surgical strategy.<sup>[30]</sup>

It may be difficult to interpret CT scan due to the presence of metal artifact.<sup>[2]</sup> One may need to change CT “windows” levels to decrease the interference from metal artifact.<sup>[31]</sup> The computed tomography images obtained at standard window widths and window density levels may not reveal the presence of stony material because of the chemical structure similar to bone and it may not show any artifacts in the computed tomography scans.<sup>[22]</sup> Impacted wooden objects are often missed in routine investigation done for head trauma. Despite modern radiological imaging, a transorbital intracranial injury with a wooden foreign body can present a vexing diagnostic problem. Wood appear like air bubble on CT scan, so wooden foreign body can be missed. Misinterpretation of CT findings in these cases may delay the adequate treatment, whereas MRI is more sensitive and specific.<sup>[32]</sup>

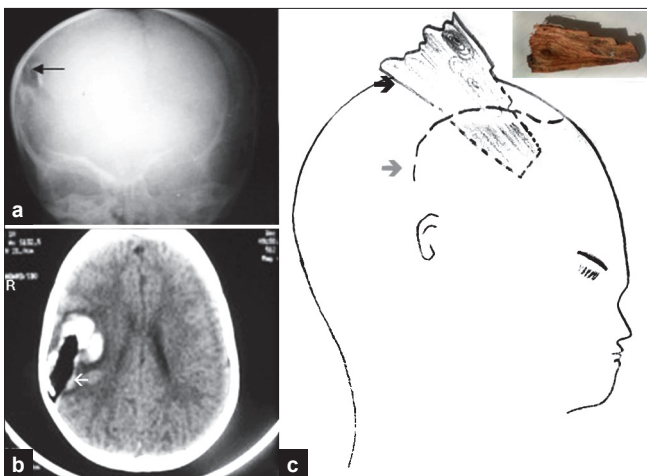
Cerebral angiography may be indicated if injury to a major cerebral vessel or venous sinus is suspected and in cases of delayed Subarachnoid hemorrhage or intracerebral hemorrhage.<sup>[2]</sup> If vascular injury is detected a decision regarding the advisability of endovascular or surgical treatment can be made with adequate exposure of the proximal vessels in the area of injury. Postoperative CT scan should be performed to exclude the presence of delayed hemorrhage. An interesting fact to the subject of penetrating knife injury of skull is that when knife blade is removed by the assailant the prognosis is worse as compared to the situation so long as it is left *in situ*. This is because the sea-saw movement of object during removal may cause further damage.<sup>[26]</sup> Retained knife may prevent hemorrhage by tamponade effect on an injured vessel.<sup>[31]</sup> Low-velocity injury with a smooth instrument reduces the amount of tissue damage.<sup>[33]</sup> If a patient has a relatively



**Figure 4:** (a) Pre-operative photograph of patient with fan blade injury, showing metal piece (arrow) embedded in the brain, (b) shows line diagram of the skin incision (white arrow), craniotomy (thin black arrow)

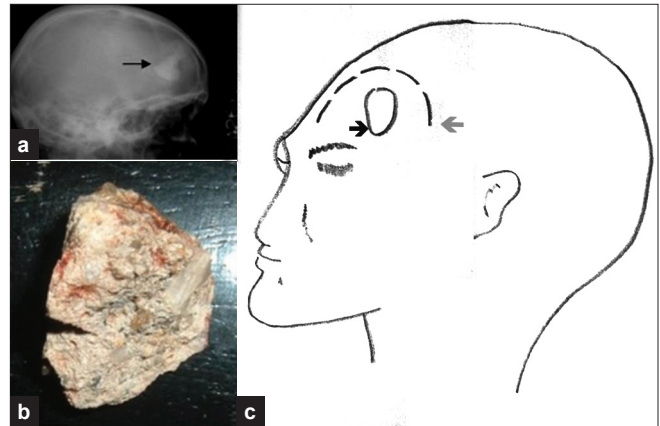


**Figure 5:** Child with impacted metal strip (white arrow). No incision was inflicted and it was removed in the operation theatre and the cranial CT scan did not reveal any abnormality

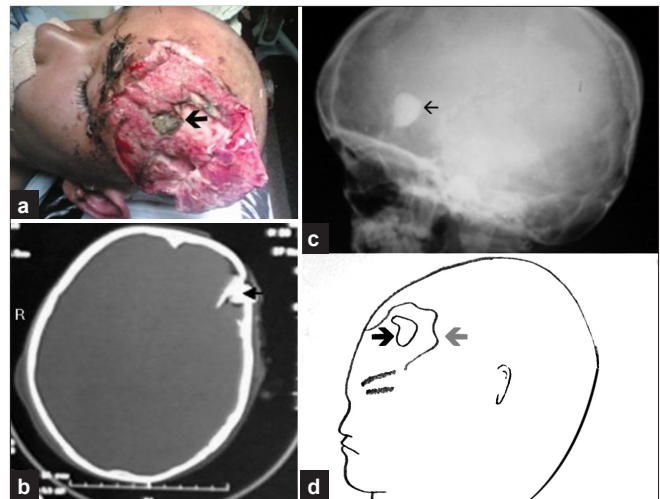


**Figure 6:** (a) X-ray skull AP view showing bone defect (arrow). Wood is radiolucent, (b) CT head showing hypodensity (mimicking air) at the site of impacted wooden object along with contusion along the anteromedial aspect, (c) Line diagram of the skin incision (white arrow). (d) Wooden piece delivered after surgery

superficial impacted object *in situ* is neurologically intact and without a demonstrable intracranial lesion on plain radiographs and CT scan, the risk of vascular injury is low.



**Figure 7:** (a) X-ray skull showing hyperdensity (stone) in frontal region (arrow), (b) Stone delivered after surgery, (c) shows line diagram of the skin incision (white arrow)



**Figure 8:** (a) Impacted stone in the left frontal region, (b) CT scan head showing a depressed fracture frontal region with impacted stone (arrow), (c) X-ray skull (AP view) showing radiopaque shadow (stone) in the frontal region, (d) shows line diagram of the lacerated wound (white arrow) around the impacted stone (black arrow)

The object could be removed under general anesthesia in the operation theatre without the need for preoperative cerebral angiography. The patient is then observed for neurological deterioration with postoperative CT scans. If the impacted object has deeply penetrated into the brain in the vicinity of a major vessel, cerebral angiography is necessary prior to surgical removal of the foreign objects. Our experience of managing patients with major vascular injury is limited. In our cases, we made multiple burr holes around the weapon (object) and craniectomy was done. The impacted weapon was gently removed along with the bone pieces. We ensured that rocking movements of the knife during withdrawal are minimized, as this could lead to further damage to the underlying brain. The weapon should always be withdrawn in a direct reverse path of trajectory.<sup>[34]</sup>

Van Dallen<sup>[26]</sup> advised skin incision extended vertically along the length of the wound produced by knife intrusion to enable skin and soft tissue reflection wherever possible. It may be necessary to make T-shaped incision and the safest method of bone removal is to make D-shaped craniectomy. The knife blade is allowed to rest against the flat vertical segment of the D providing stability, so as to provide sufficient access to control hemorrhage. A brain retractor is then gently slid alongside of the knife blade to expose tip of knife. The blade is then withdrawn. This provides a method of removal with least amount of additional trauma and access to a deeper structure.

## Results

Present study is confined over three adults and five children who were admitted in the neurosurgical ward, SMS Hospital, Jaipur, during 1995-2006. The patients were timely operated by standard operation procedures. The most commonly encountered types of penetrating head injuries are industrial accidents, suicidal attempts, and criminal assault. Two patients resulted from assault, one of them had self-inflicted injury in suicidal attempt and four were accidental. We have included only those cases who presented to us with impacted weapon *in situ*. We used intravenous Ceftriaxone and Gentamycin as prophylactic antibiotics in all cases. Phenytoin was used as prophylactic anticonvulsant in the cases where cerebral cortex injury was seen.

In context of earlier reviewed cases and from our own experience, we learnt that removal of impacted sharp weapons should only be done in the operation theatre so as to avoid further brain damage. Removal of the foreign object is in the direction of trajectory without zig-zag movements. The skin incision was made S-shaped around the site of entry of the weapon. Plain radiographs of the skull and preferably CT scan should be performed to ascertain the direction of the trajectory of the weapon.

## Conclusion

Low-velocity penetrating head injury injuries in developing countries like India are not uncommon and are usually seen in rural setup and mainly because of interpersonal assault. The extent of damage of tissues depends on the type, shape, size, site, and the velocity of sharp weapon as well as on the extent of its penetration at the impacted site. X-ray skull is essentially done to assess the location and the nature of injury, the driven bone fragment and foreign body within the brain. CT scan helps in the visualization of the entire head, nature of intracranial injury, hemorrhage, edema, tract of lesion, intracranial bony and metallic fragments, and intracranial air. Craniectomy around the foreign body, debridement, and removal of foreign body without zigzag motion is needed.

## References

- Pilcher C. Penetrating wounds of the brain: An experimental study. *Ann Surg* 1936;103:173-98.
- Herring CJ, Lumsden AB, Tindall SC. Transcranial stab wounds: A report of three cases and suggestions for management. *Neurosurgery* 1988;23:658-62.
- The holy Bible. Book of Judges 4. 21-22.
- August Strindberg: "By the open sea" Translated to English by Ellie Schleussner. New York: Heubsch; 1913. p. 310-2.
- From the centers for disease control and prevention. Deaths resulting from firearm- and motor-vehicle-related injuries- United States, 1968-1991. *JAMA* 1994;271:495-6.
- Taylor AG, Peter JC. Patients with retained transcranial knife blades: A high-risk group. *J Neurosurg*;1997;87:512-5.
- Kesteven WB, Harris FH. Case of a boy, aet.13, Who Lay for nine days after a fall, in which one of the prongs of a farming fork had passed through the brain. *Trans Path Soc of London*;1874;25:13.
- Seex K, Koppel D, Fitzpatrick M, Pyott A. Trans-orbital penetrating head injury with a door key. *J Craniomaxillofac Surg* 1997;25:353-5.
- López F, Martínez-Lage JF, Herrera A, Sánchez-Solís M, Torres P, Palacios MI, et al. Penetrating craniocerebral injury from an underwater fishing harpoon. *Childs Nerv Syst* 2000;16:117-9.
- Kumar A, Singh H, Sharma KC. Penetrating Head Injury from a Pedestal Fan Rotor Blade in a Child - An Unusual Case. *Pediatr Neurosurg* 2006;42:391-4.
- Abdoli A, Amirjamshidi A. Work-Related Penetrating Head Trauma Caused by Industrial Grinder Tool. *Arch Iran Med* 2009;12:496-8.
- Satyarthee GD, Borkar SA, Tripathi AK, Sharma BS. Transorbital penetrating cerebral injury with a ceramic stone: Report of an interesting case. *Neurol India* 2009;57:331-3.
- Lazic T, Strugar J. Nail in the midbrain. *Neurology* 2009;72:1531.
- Shakir A, Koehler SA, Wecht CH. A review of nail gun suicides and an atypical case report. *J Forensic Sci* 2003;48:409-13.
- O'Neill OR, Gilliland G, Delshaw JB, Purtzer TJ. Transorbital penetrating head injury with a hunting arrow: Case report. *Surg Neurol* 1994;42:494-7.
- Ferguson FN. A penetrating wound of the skull and brain. *NY Med J* 1896;64:360.
- Farhadi MR, Becker M, Stippich C, Unterberg AW, Kiening KL. Transorbital penetrating head injury by a toilet brush handle. *Acta Neurochir (Wien)* 2009;151:685-7.
- Solarino B, Reckentwald K, Burrows-Beckham. An unusual case of child head injury by coat hanger. *AM J Forensic Sci* 2008;53:1188-90.
- Chattopadhyay S, Sukul B, Das SK. Fatal transorbital head injury by bicycle brake handle. *J Forensic Leg Med* 2009;16:352-3.
- Agrawal A, Pratap A, Agrawal CS, Kumar A, Rupakheti S. Transorbital orbitocranial penetrating injury due to bicycle brake handle in a child. *Pediatr Neurosurg* 2007;43:498-500.
- Balak N, Aslan B, Serefhan A, Elmaci I. Intracranial retained stone after depressed skull fracture: Problems in the initial diagnosis. *Am J Forensic Med Pathol* 2009;30:198-200.
- Kanagarajan A, Sgouros S. Unusual penetrating cranio-cerebral injuries in children from mains plugs. *Childs Nerv Syst* 2007;23:1181-3.
- Orbay A. S Unusual penetrating faciocranial injury caused by a knife: A case report. *J Craniomaxillofacial Surg* 1997;25:279-81.
- Domingo Z, Peter JC, de Villiers JC. Low-velocity penetrating craniocerebral injury in childhood. *Pediatr Neurosurg* 1994;21:45-9.
- Van Dallen JR, Lipschitz R. Stab wounds of the skull. *Surg Neurol* 1978; 10:110-4.
- Haworth CS, De Villiers JC. Stab wounds to the temporal fossa. *Neurosurgery* 1988;23:431-5.
- de Villiers JC, Grant AR. Stab wounds at the craniocervical junction. *Neurosurgery* 1985;17:930-6.
- De Villiers JC, Sevel D. Intracranial complications of transorbital stab wounds. *Br J Ophthalmology* 1975;59:52-6.
- Kieck CF, de Villiers JC. Vascular lesions due to transcranial stab wounds. *J Neurosurgery*1984;60:42-46.
- Nakayama Y, Tanaka A, Atria T, Kumate S, Yoshiga S. Penetrating

- head injury caused by weed: Case report. *Brain and Nerve* 1995;47: 1192-4.
31. Taylor AG, Peter JC. Patients with retained transcranial knife blades: A high-risk group. *J Neurosurg* 1997;87:512-5.
  32. Smely C, Orszagh M. Intracranial transorbital injury by a wooden foreign body: Re-evaluation of CT and MRI findings. *Br J Neurosurg* 1999;13:206-11.
  33. Gurdjian ES, Webster JE. *Head Injury*. Boston and Toronto: Little Brown and Co.; 1958. p. 222-93.
  34. Domingo Z, Peter JC, de Villiers JC. Low-velocity penetrating craniocerebral injury in childhood. *Pediatr Neurosurg* 1994;21:45-9.

**How to cite this article:** Kataria R, Singh D, Chopra S, Sinha VD. Low velocity penetrating head injury with impacted foreign bodies in situ. *Asian J Neurosurg* 2011;6:39-44.

**Source of Support:** Nil, **Conflict of Interest:** None declared.

### Staying in touch with the journal

**1) Table of Contents (TOC) email alert**

Receive an email alert containing the TOC when a new complete issue of the journal is made available online. To register for TOC alerts go to [www.asianjns.org/signup.asp](http://www.asianjns.org/signup.asp).

**2) RSS feeds**

Really Simple Syndication (RSS) helps you to get alerts on new publication right on your desktop without going to the journal's website. You need a software (e.g. RSSReader, Feed Demon, FeedReader, My Yahoo!, NewsGator and NewzCrawler) to get advantage of this tool. RSS feeds can also be read through FireFox or Microsoft Outlook 2007. Once any of these small (and mostly free) software is installed, add [www.asianjns.org/rssfeed.asp](http://www.asianjns.org/rssfeed.asp) as one of the feeds.