

Surgical strategies and outcomes for distal anterior cerebral arteries aneurysms

Yasser Orz

Department of Neurosurgery, Neuroscience Center, King Fahad Medical City, Riyadh, Saudi Arabia and Department of Neurosurgery, Alexandria University Faculty of Medicine, Alexandria, Egypt

ABSTRACT

Background: Distal anterior cerebral artery (DACA) aneurysms are rare and their surgical treatment presents some unique difficulties. In this report, we present our experience of cases with DACA aneurysms.

Materials and Methods: Among 80 patents with cerebral aneurysm operated on in the three-year period, 15 patients (18.75%) had DACA aneurysms, who were studied retrospectively. We analyze the specific clinical and radiological features, surgical strategies and prognostic factors affecting the surgical outcomes of these DACA aneurysms.

Results: There were 10 male and 5 female patients harboring 16 DACA aneurysms. All patients presented with subarachnoid hemorrhage, 11 patients (73%) had intracerebral hematoma in their initial CT scan and four of them had associated intraventricular hemorrhage. Thirteen of the ruptured DACA aneurysms (86%) were small in size (less than 7 mm in diameter). Three patients (20%) had other associate aneurysms. In 14 patients (93%), a unilateral interhemispheric approach was used in their treatment, while pterional approach was used in one patient. Eleven patients (73%) had favorable outcomes and only one patient (7%) died. The follow-up data suggested that poor admission grade and initial Intracerebral hematoma (ICH) on brain scan portend an unfavorable prognosis.

Conclusions: DACA aneurysms are usually small even when ruptured, they are usually associated with ICH more frequently than intracranial aneurysms in other locations. They should be aggressively treated even if very small because of their tendency to early rupture.

Key words: Cerebral aneurysm, distal anterior cerebral artery, subarachnoid hemorrhage

Introduction

Aneurysms of distal anterior cerebral artery (DACA) are rare and comprise about 1.5-9% of all aneurysms in the cerebral circulation.^[1-7] They are usually located at the pericallosal-callosomarginal bifurcation and these aneurysms are usually small in size, distal in location, embedded between cerebral hemispheres and with wide neck.^[8,9] These features make both microsurgical and endovascular treatments difficult because patency of the parent vessels is at risk, therefore,

a unique different microsurgical approaches are required than the aneurysms on the A1 segment of the anterior cerebral artery or the anterior communicating artery complex.^[2,10]

In this report, our experience with DACA aneurysms is presented and discussed focusing on their clinical and radiological features, surgical strategies used in their treatment and the surgical outcome of these rare aneurysms.

Materials and Methods

Out of 80 patients with cerebral aneurysms treated in our institutions during the three-year period, 15 patients of them had DACA aneurysms (18.7%), who were studied retrospectively.

Data were reviewed including the patients' age, gender, admission grade according to Hunt and Hess grading system (H & H grading). Characteristics of imaging studies including size, location, multiplicity and presence of Intracerebral hematoma (ICH) were studied. Also, surgical approaches used for patients' management were reviewed.

Access this article online	
Quick Response Code:	Website: www.asianjns.org
	DOI: 10.4103/1793-5482.85628

Address for correspondence:

Dr. Yasser Ismail Orz, Department of Neurosurgery, Neuroscience Center, King Fahad Medical City, P.O. Box: 59046, Riyadh 11525, Saudi Arabia. E-mail: orz163@gmail.com

The surgical outcome was assessed according to Glasgow Outcome Scale (GOS) classifying the results into “good recovery”, “moderate disability”, “severe disability”, “persistent vegetative state”, or “death”. Among them, “good recovery” and “moderate disability” were judged as a favorable outcome. Table 1 shows a summary of the 15 patients.

Management strategy

A multidisciplinary discussion for every patient was done with our neurointervention team for selection of the best way of treating every patient. In all of these 15 patients surgical clipping was chosen due to small aneurysm size in 13 patients and aneurysm complex configuration in 2 patients and parent artery origin form the base of the aneurysm in 1 patient.

Our surgical strategy for DACA aneurysms involved surgical intervention as early as possible to prevent rebleeding and to evacuate the accompanying hematoma and to treat the vasospasm aggressively. Surgical approach was modified according to the location and multiplicity of the aneurysms.

A unilateral interhemispheric approach was chosen in DACA aneurysms at the origin of the callosomarginal artery, while pterional approach was selected in DACA aneurysms at the origin of the frontopolar artery. In case of multiple aneurysms, the unruptured aneurysms were treated with a second scheduled operation.

Results

Clinical features

Among the 15 patients included in this study, 10 patients were males (66%) and 5 were females (33%). The patients age ranged from 30 to 70 years (mean age 51 years).

Of the 15 patients, 11 were in grades I and II, three were

in grade III and one patient was in grade IV on admission according to H and H grading system [Table 1].

Radiological features

The 15 patients had 16 DACA aneurysms. All the 15 patients had subarachnoid hemorrhage (SAH) due to ruptured aneurysm in their initial CT scan. ICH on the callosal area or medial frontal lobe was found in 11 patients (73%), intraventricular extension of the ICH was found in 4 of these 11 patients (36%). Figure 1 shows some different shapes of ICH.

With respect to the location, 14 patients (93%) had their DACA aneurysms located at the pericallosal-callosomarginal bifurcation (A3), and only one patient (7%) had aneurysm located proximally at the frontopolar branching (A2). Nine patients had aneurysms located in the right side and 6 had them located on the left side.

The size of aneurysms ranged from 2 to 16 mm with a mean size of 4.8 mm, 13 patients (86%) had small aneurysms (diameter <7 mm), one patient had medium-sized aneurysm (diameter 10 mm), and one patient had large aneurysm (diameter 16 mm).

Three patients had associated aneurysms; one patient had another DACA aneurysm of a kissing mirror image type clipped at the same operation, one patient had carotid bifurcation aneurysm that was coiled in another stage, and the third patient had anterior communicating aneurysm, which was clipped in a separate operation. Figure 2 shows some angiographic features of the DACA aneurysms.

Surgical approaches

Anterior interhemispheric approach was used in 14 patients (93%) to treat their DACA aneurysms that located at A3, in 12 patients the right side was used, while the left side was used

Table 1: Summary of the 15 patients with DACA aneurysms

Age/ Sex	Admission Grade (H and H)	ICH/IVH	Aneurysm size	Location	Multiple aneurysm	VP shunt	Outcome (GOS)
40/M	II	+/-	4 mm	A3		-	S
31/M	I	+/-	3 mm	A3		-	G
50/M	II	-/-	2 mm	A3	Acom an	-	G
70/M	II	+/+	5 mm	A3		+	S
35/F	I	+/-	3 mm	A3		-	G
45/M	IV	+/+	16 mm	A3		-	D
55/F	II	+/-	4 mm	A3	ICA bif.	+	M
60/M	III	+/-	5 mm	A3		-	G
32/M	I	-/-	4 mm	A2		-	G
65/M	II	+/-	4 mm	A3	Kissing DACA an	-	G
46/F	I	+/+	2 mm	A3		-	M
35/M	III	+/+	10 mm	A3		+	S
41/F	II	-/-	2 mm	A3		-	G
38/M	III	-/-	5 mm	A3		-	M
53/F	I	+/-	4 mm	A3		-	G

M: Male; F: Female; H and H: Hunt and Hess grading, A3: Pericallosal-callosomarginal bifurcation, A2: Pericallosal-frontopolar branching, Acom an.: Anterior communicating aneurysm, ICA bif.: Internal carotid artery bifurcation, DACA an.: Distal anterior cerebral artery aneurysm, GOS: Glasgow Outcome Scale; G: Good recovery; M: Moderate disability; S: Severe disability; D: Dead

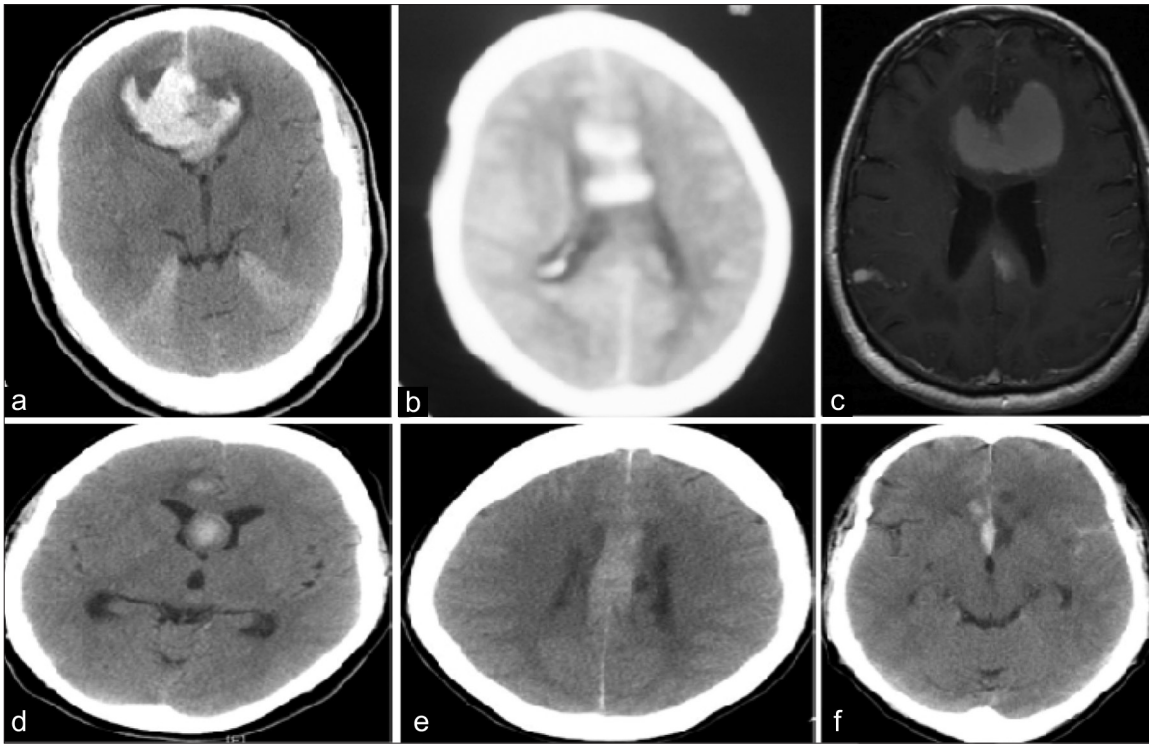


Figure 1: Radiological features of some ICH due to rupture distal anterior cerebral arteries (DACA). (a) CT brain showing large interhemispheric and callosal ICH with ventricular compression. (b) CT brain showing interhemispheric ICH with intraventricular extension. (c) T1 MRI brain with large interhemispheric ICH. (d) CT brain showing ICH and IVH. (e) CT brain showing interhemispheric ICH. (f) CT brain showing ICH at the base of brain due to ruptured DACA located at A2

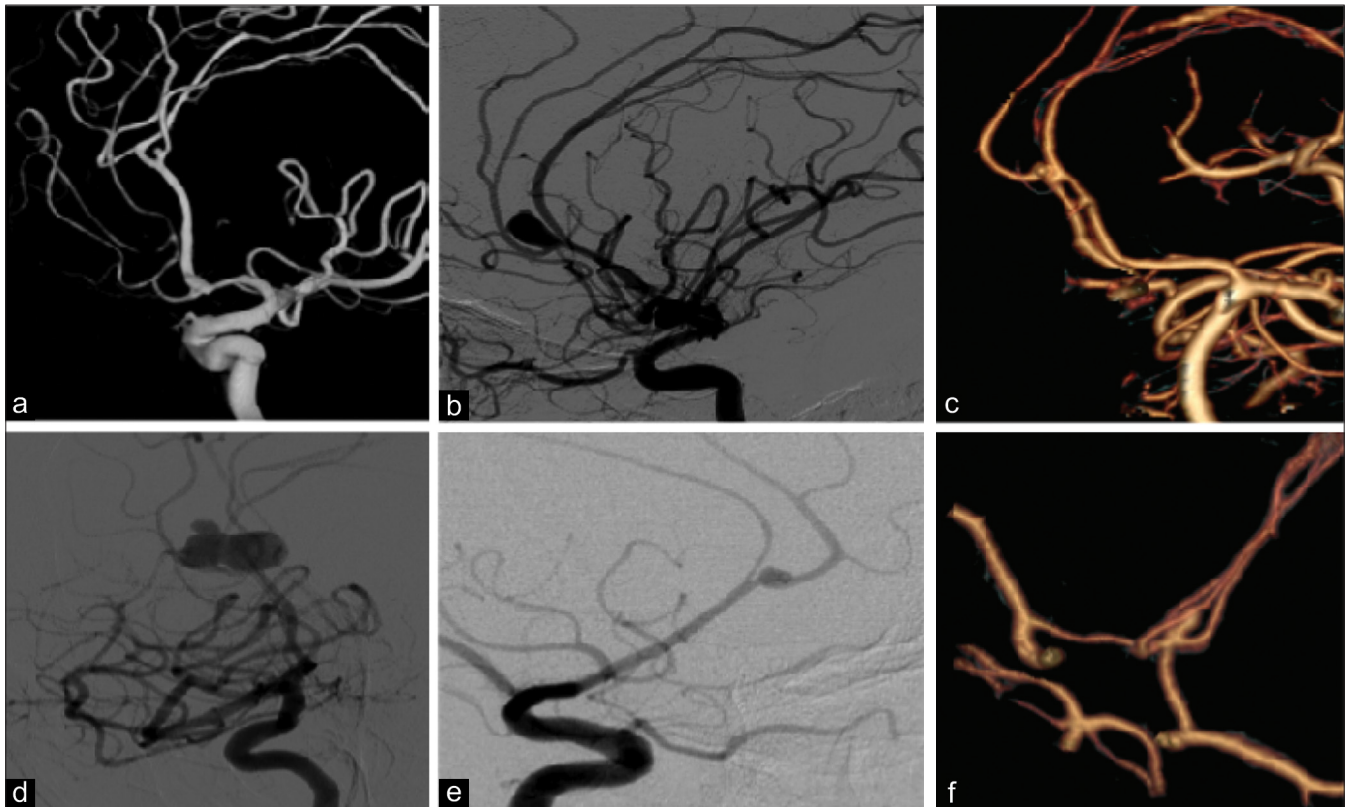


Figure 2: Angiographic features of some distal anterior cerebral arteries aneurysms (DACA). (a) 3D angiogram showing very small DACA at A3. (b) Angiogram showing medium size DACA at A3. (c) 3DCTA showing 2 kissing DACA at Bil. A3. (d) Angiogram showing large trilobed DACA at A3. (e) Angiogram showing small DACA at A3 with vessels straightening due to ICH. (f) 3DCTA showing small DACA at A2

in only 2 patients whose aneurysms were embedded in the right frontal lobes. The left pterional approach was used in only one patient with proximal DACA aneurysm located at A2.

Surgical outcomes

According to GOS, eight patients had good recovery, three had moderate disability, and other three had severe disability and one patient died.

So, 11 patient (73%) had a favorable outcome, 3 patients (20%) had unfavorable outcome due to infarction in the DACA territories, and one patient died.

The relation between the outcome grade and the H and H admission grade was shown in [Table 1]. Two patients with severe disability outcome were in good H and H admission grade but in these 2 patients large ICH was found in their admitting CT.

Perioperative hydrocephalus and shunt

Three of our patients had VP shunts inserted, 2 patients had preoperative hydrocephalus and the other patient developed hydrocephalus after aneurysm clipping that necessitates VP shunt insertion.

Discussion

The incidence of DACA aneurysms has been estimated to be from 1.5 to 9% of all intracranial aneurysm based on the large series in the literatures.^[1-3,5,7] The incidence in our series was 18.7%; this high incidence may be attributed to referral bias from other hospitals as we serve as a referral center for neurovascular patients.

Although female predominance is reported,^[1,5] in our series most of the patients (66%) were males and that have been reported in other studies.^[11,12]

The association of multiple aneurysms with DACA aneurysms was frequent, Hernesniemi *et al.*,^[2] reported an incidence of 46.4%, Ohno *et al.*,^[5] reported 42.9% and Yasergil *et al.* reported 38.5%.^[10] In our series there were three patients with multiple aneurysms (21%).

Most DACA aneurysms are saccular and located at the pericallosal-callosomarginal bifurcation on the genu of the corpus callosum.^[1,2,12,13] Aneurysms at the junction of pericallosal and frontopolar arteries and distal to pericallosal-callosomarginal bifurcation are rare.^[1,3,12,14]

All aneurysms in our series are saccular and in 14 patients (93%) located at the pericallosal-callosomarginal bifurcation and only one patient had an aneurysm located at pericallosal-frontopolar branching.

In general, DACA aneurysms are rather small.^[1,2,5,7,9,15,16] In our series, 13 patients (86%) had small aneurysms (<7 mm), Ohno

et al.^[5] had 36 out of 49 patients with small aneurysms of 5 mm or less and Leheka *et al.*,^[3,16] in their series reported that 51% of their ruptured DACA aneurysms had aneurysms less than 7 mm in diameter. Accordingly, considering the characteristic of easy rupture even for a small-sized aneurysm, DACA aneurysms must not be overlooked and need a definitive treatment even if it is incidentally discovered in unruptured state.

In previous reports, ICH is more frequent with DACA aneurysms ranging from 17 to 73% compared with those aneurysms in other locations.^[2,3,7,17,18]

Leheka *et al.*,^[3] reported that 53% of their patients with ruptured DACA aneurysms had ICH in their initial CT scan compared with 25% for the ruptured aneurysms in general. In our series, 11 patients out of 15 patients (73%) had ICH. This high incidence of ICH may be related to the narrow pericallosal cistern and dense attachment to the adjacent brain surfaces.

Thomas and Paterson reported no direct relation between the presence of ICH and the final outcome.^[19] However, Wisoff and Flamm^[10] noted that patients with good grade did not have ICH, while ICH and clinically significant vasospasm were observed in poor grade patients.

In our study, all four patients with unfavorable outcome had ICH in their initial CT scan; this may indicate that the presence of ICH had negative implications for both the clinical course and final surgical outcomes.

DACA aneurysms were observed to be a surgical challenge due to certain specific characteristics when compared with other aneurysm locations.^[1,2,4-7,10,12,20,21,22] These difficulties are related to the deep approach inside the interhemispheric space, lack of anatomic landmarks, dense attachment and embedding of the aneurysm dome in the surrounding brain tissue and also morphological features of the DACA aneurysms such as small size and broad base with branching arteries close to the base. The dome of the aneurysm projects towards the surgeon is mostly exposed before the aneurysm neck is seen, even gentle retraction of the falx or medial surface of the frontal lobe can cause aneurysm rupture.^[12,13] So, intraoperative rupture is a frequent complication.

In our series, 14 patients were treated with interhemispheric approach and only one patient with proximal DACA aneurysm was operated by left pterional approach; intraoperative rupture occurred in 5 of our patients (35%). This may be due to difficulties in establishing an early proximal control of the aneurysm.

Endovascular occlusion of DACA aneurysms is demanding because of their small size, relatively wide-neck, branches originating close to the base, small caliber of parent artery and distal location of the aneurysms; some authors reported good results after coiling of DACA aneurysms.^[23,9] However,

despite their challenging features, microsurgical clipping still remains the primary treatment modality for DACA aneurysms, and endovascular treatment of ruptured DACA aneurysms shall be considered as an alternative method to surgical clipping.

So, in our patients with DACA aneurysms, poor H and H grade, rebleeding before treatment, presence of ICH and preoperative hydrocephalus are independent factors predicting unfavorable outcome.

Conclusions

Despite all improvements in the microsurgical techniques and anesthesia, DACA aneurysms still have higher morbidity and mortality rates than other supratentorial aneurysms.

However, with the help of further understanding of the relationship between the DACA aneurysms and the surrounding vessels, the appropriate microsurgical techniques and the skill and experience of the neurosurgeon, the surgical treatment of these aneurysms with a significant low morbidity and mortality rates can be achieved.

Early treatment of DACA aneurysms is advisable, even if small, because of their tendency to early rupture.

References

- de Sousa AA, Dantas FL, de Cardoso GT, Costa BS. Distal anterior cerebral artery aneurysms. *Surg Neurol* 1999;52:128-36.
- Hernesniemi J, Tapaninaho A, Vapalahti M, Niskanen M, Kari A, Luukkonen M. Saccular aneurysms of the distal anterior cerebral artery and its branches. *Neurosurgery* 1992;31:998-9.
- Leheka M, Lehto H, Niemela M, Juvela S, Dashti R, Koivisto T, *et al.* Distal anterior cerebral artery aneurysms: Treatment and outcome analysis of 501 patients. *Neurosurgery* 2008;60:590-601.
- Miyazawa N, Nukui H, Yagi S, Yamagata Z, Horikoshi T, Yagishita T, *et al.* Statistical analysis of factors affecting the outcome of patients with ruptured distal anterior cerebral artery aneurysms. *Acta Neurochir (Wien)* 2000;142:1241-6.
- Ohno K, Monma S, Suzuki R, Masaoka H, Matsushima Y, Hirakawa K. Saccular aneurysms of the distal anterior cerebral artery. *Neurosurgery* 1990;27:907-12.
- Otani N, Takasato Y, Masaoka H, Hayakawa T, Yoshino Y, Yatsushige H, *et al.* Clinical features and surgical outcomes of ruptured distal anterior cerebral artery aneurysms in 20 consecutively managed patients. *J Clin Neurosci* 2009;16:802-6.
- Steven DA, Lownie SP, Ferguson GG. Aneurysms of the distal anterior cerebral artery: Results in 59 consecutively managed patients. *Neurosurgery* 2007;60:227-34.
- Cohen JE, Rajz G, Itshayek E, Shoshan Y, Umansky F, Gomori JM. Endovascular management of traumatic and iatrogenic aneurysms of the pericallosal artery. Report of two cases. *J Neurosurg* 2005;102:555-7.
- Menovsky T, van Rooij WJ, Sluzewski M, Wijndal D. Coiling of ruptured pericallosal artery aneurysms. *Neurosurgery* 2002;50:11-4.
- Wisoff JH, Flamm ES. Aneurysms of the distal anterior cerebral artery and associated vascular anomalies. *Neurosurgery* 1987;20:735-41.
- Dinc C, Iplikcioglu AC, Bikmaz K. Distal anterior cerebral artery aneurysms: report of 26 cases. *Neurol Med Chir (Tokyo)* 2006;46:575-80.
- Yaşargil MG, Carter LP. Saccular aneurysms of the distal anterior cerebral artery. *J Neurosurg* 1974;40:218-23.
- Kawashima M, Matsushima T, Sasaki T. Surgical strategy for distal anterior cerebral artery aneurysms: microsurgical anatomy. *J Neurosurg* 2003;99:517-25.
- Leheka M, Dashti R, Hernesniemi J, Niemelä M, Koivisto T, Ronkainen A, *et al.* Microneurosurgical management of aneurysms at A3 segment of anterior cerebral artery. *Surg Neurol* 2008;70:135-52.
- Chhabra R, Gupta SK, Mohindra S, Mukherjee K, Bapuraj R, Khandelwal N, *et al.* Distal anterior cerebral artery aneurysms: bifrontal basal anterior interhemispheric approach. *Surg Neurol* 2005;64:315-9.
- Leheka M, Porras M, Dashti R, Niemela M, Hernesniemi J. Anatomic features of distal anterior cerebral artery aneurysms: A detailed angiographic analysis of 101 patients. *Neurosurgery* 2008;63:219-29.
- Kassell NF, Torner JC, Haley EC, Jr, Jane JA, Adams HP, Kongable GL. The International Cooperative Study on the Timing of Aneurysm Surgery. Part 1: Overall management results. *J Neurosurg* 1990;73:18-36.
- Kwon TH, Chung HS, Lim DJ, Park JY, Park YK, Lee HK, *et al.* Distal anterior cerebral artery aneurysms: Clinical features and surgical outcome. *J Korean Med Sci* 2001;16:204-8.
- Thomas DG, Paterson A. Results of surgical treatment of pericallosal aneurysms. *J Neurol Neurosurg Psychiatry* 1975;38:826.
- Carvi y Nievas MN. The influence of configuration and location of ruptured distal cerebral anterior artery aneurysms on their treatment modality and results: analysis of our casuistry and literature review. *Neurol Res* 2010;32:73-81.
- Leheka M, Niemelä M, Seppänen J, Lehto H, Koivisto T, Ronkainen A, *et al.* No long-term excess mortality in 280 patients with ruptured distal anterior cerebral artery aneurysms. *Neurosurgery* 2007;60:235-40.
- Lee JW, Lee KC, Kim YB, Huh SK. Surgery for distal anterior cerebral artery aneurysms. *Surg Neurol* 2008;70:153-9.
- Keston P, White PM, Horribine L, Sellar R. The endovascular management of pericallosal artery aneurysms. *J Neuroradiol* 2004;31:384-90.

How to cite this article: Orz Y. Surgical strategies and outcomes for distal anterior cerebral arteries aneurysms. *Asian J Neurosurg* 2011;6:13-7.

Source of Support: Nil, **Conflict of Interest:** None declared.

Announcement

Android App



Download
**Android
application**

FREE

A free application to browse and search the journal's content is now available for Android based mobiles and devices.. The application provides "Table of Contents" of the latest issues, which are stored on the device for future offline browsing. Internet connection is required to access the back issues and search facility. The application is compatible with all the versions of Android. The application can be downloaded from <https://market.android.com/details?id=comm.app.medknow>. For suggestions and comments do write back to us.