

# Unilateral Fenestrated A1 Segment of Anterior Cerebral Artery Multiple Aneurysms: Case Reports and Literature Review

## Abstract

The fenestration of the cerebral arteries is infrequent anomaly mostly occurring in the posterior communicating artery, the vertebral artery, the basilar artery, and the middle cerebral artery.<sup>[1]</sup> We report a case of unilateral A1 fenestration associated saccular aneurysm, focusing on its features of surgical treatment.

**Keywords:** *A1 segment, anterior cerebral artery, arterial fenestrations*

## Introduction

Vascular anomalies of the brain are not very frequent in surgical practice; they represent a wide spectrum of congenital conditions that result from development disorders which are mainly found in anatomical cadaveric dissection studies. Such abnormalities like arterial fenestrations may be physiologically silent and clinically asymptomatic, but in some cases, due to weakened arterial wall, it causes aneurysms. When surgeon encounters intraoperatively fenestration with aneurysm, it is challenging case that requires unique surgical management. We have to know these lesions to deal with them.

Fenestrations of the A1 segment of the anterior cerebral artery (ACA) are not common and found only in 0.14% of the specimens in cadaveric study.<sup>[2]</sup> Furthermore, it has been reported 19 cases of aneurysms associated with A1 fenestration between 1983 and 2011 years by different authors.<sup>[3]</sup>

## Case Reports

### Case 1

A 62-year-old man with a no family history of aneurysms has been admitted to our hospital by screening program. In his life history, he has no hypertension, dislipidemia, and has a smoking habit only. A three-dimensional computed tomography (3DCT) with angiography was performed

at our institution revealed a small aneurysm at the proximal end of fenestrated right A1 segment [Figures 1a-d and 2]. The patient underwent surgical clipping of the aneurysm using pterional craniotomy. During the operation, we have used as an adjunct intraoperative controlling modalities – indocyanine green videoangiography (ICG-VA) and endoscopic visualization to precisely detect the aneurysmal anatomy. Surgical exploration revealed the aneurysm just proximal to the right fenestrated A1 segment [Figure 2a] which is also confirmed with ICG-VA and by endoscopy [Figure 2b and c]. The aneurysm was clipped successfully using two clips, size of 6 mm first straight and then another fenestrated clip across the aneurysmal neck [Figure 3]. Postclipping ICG-VA and endoscopic control showed complete obliteration of the aneurysm and preserved normal patency of both two channels of fenestration [Figure 4]. Postoperative period passed without any complications and the patient was discharged home neurologically intact. The patient is doing well for the 2 years of follow-up period. Postoperative follow-up 3DCT was performed 1 month later, which reveals normal position of clip regular position of the vessels [Figure 5].

### Case 2

A 63-year-old man with a no family history of aneurysms has been admitted to our hospital by screening program. In

**Dilshod Mamadaliev,**  
**Yoko Kato<sup>1</sup>,**  
**Sandeep Talari<sup>2</sup>,**  
**Tushit Mewada<sup>3</sup>,**  
**Yasuhiro Yamada<sup>1</sup>,**  
**Yamashiro Kei<sup>1</sup>,**  
**Tsukasa Kawase<sup>1</sup>**

*Republican Scientific Center of Neurosurgery, Tashkent, Uzbekistan, <sup>1</sup>Department of Neurosurgery, Fujita Health University, Banbuntane Hotokukai Hospital, Nagoya, Aichi, Japan, <sup>2</sup>Department of Neurosurgery, Andhra Medical College, Visakhapatnam, Andhra Pradesh, <sup>3</sup>Department of Neurosurgery, G.B. Pant Institute of Postgraduate Medical Education and Research, New Delhi, India*

### Address for correspondence:

*Dr. Dilshod Mamadaliev,  
Fujita Health University,  
Banbuntane Hotokukai  
Hospital, 3-6-10, Otobashi,  
Nakagawa-Ward, Nagoya,  
Aichi 454-0012, Japan.  
E-mail: dr.mdm@mail.ru*

### Access this article online

**Website:** [www.asianjns.org](http://www.asianjns.org)

**DOI:** 10.4103/1793-5482.258113

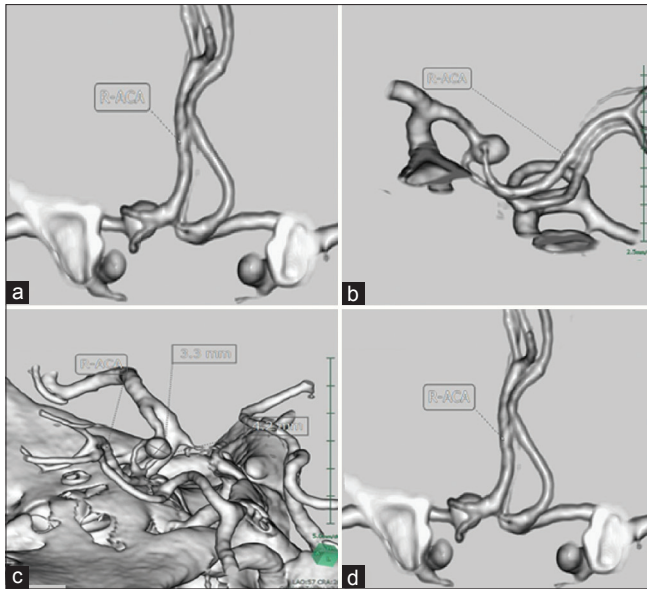
### Quick Response Code:



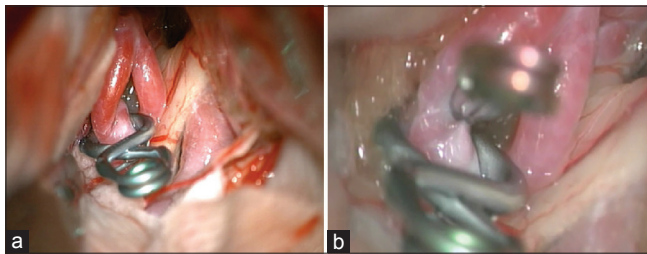
**How to cite this article:** Mamadaliev D, Kato Y, Talari S, Mewada T, Yamada Y, Kei Y, et al. Unilateral fenestrated A1 segment of anterior cerebral artery multiple aneurysms: Case reports and literature review. *Asian J Neurosurg* 2019;14:957-60.

This is an open access journal, and articles are distributed under the terms of the Creative Commons Attribution-NonCommercial-ShareAlike 4.0 License, which allows others to remix, tweak, and build upon the work non-commercially, as long as appropriate credit is given and the new creations are licensed under the identical terms.

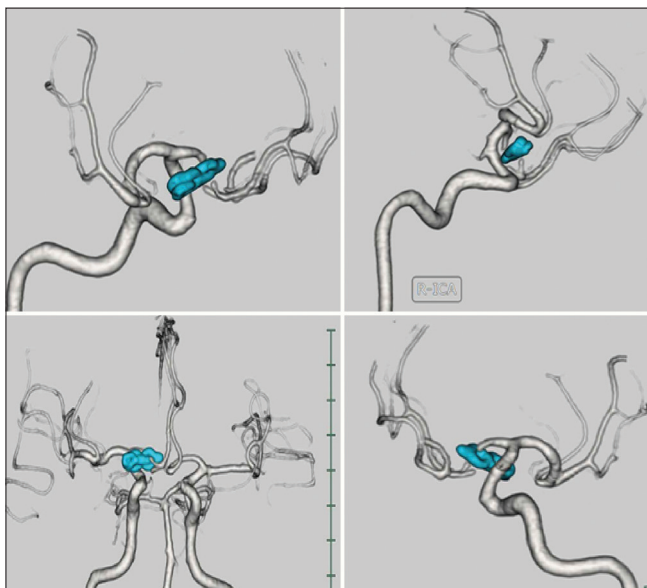
**For reprints contact:** [reprints@medknow.com](mailto:reprints@medknow.com)



**Figure 1:** Three-dimensional reconstructed computed tomography angiogram demonstrating right A1 segment fenestration and an aneurysm just before communicating artery (a, b and d). The diameter of aneurysmal sac is 3.3 mm × 4.2 mm (c)



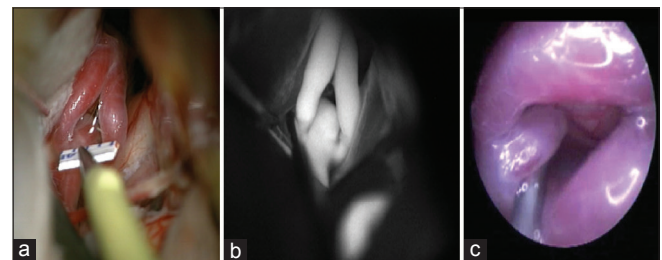
**Figure 3:** The process of clipping. A fenestrated clip applied through fenestration of A1 (a and b). Two channels of A1 fenestration preserved successfully



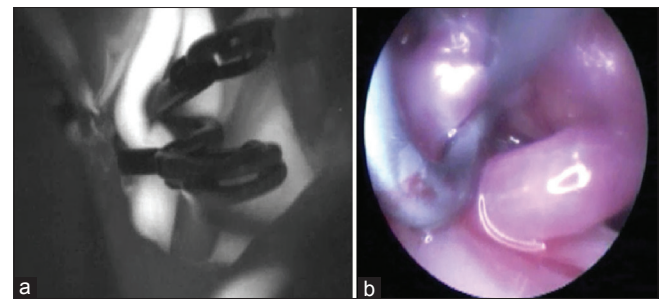
**Figure 5:** Postoperative 3D CT angiography the patient. A fenestrated clip has been applied to the neck of the aneurysm and second clip applied additionally to the dome. Patency is preserved

his history, he has diabetes mellitus, gout and underwent operation on removing mediastinal tumor 12 years ago.

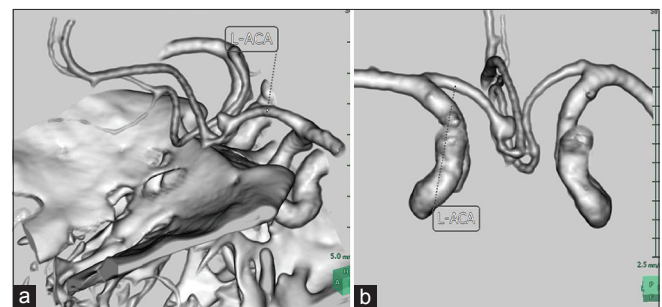
A 3DCT with angiography were performed at our institution revealed a small aneurysm at the proximal end of fenestrated right A1 segment [Figure 6a and b]. The patient underwent operation, with the pterional craniotomy approach. During the operation, we have encountered another small aneurysm on bifurcation point of A1 into two channels. The major aneurysm was projecting laterally, to the right side [Figure 7]. Intraoperative view also confirmed with ICG-VA and by endoscopy [Figure 7b and c] The aneurysms were clipped successfully, size of 4 mm Sujita II curved clip for the minor aneurysm, another Sujita I straight clip size of 6 mm for the bigger one [Figure 8]. Postclipping ICG-VA and endoscopic control confirmed obliteration of the aneurysms, preserving normal patency of both two channels of fenestration [Figure 8]. Postoperative



**Figure 2:** Intraoperative microscopic (a), indocyanine green videoangiography (b) and endoscopic (c) views and measuring of aneurysm



**Figure 4:** Endoscopic (b) and indocyanine green videoangiography (a) view of after clipping. A fenestrated clip has been applied to the neck of the aneurysm and second clip applied additionally to the dome. Normal patency of right anterior cerebral artery preserved



**Figure 6:** A three-dimensional computed tomography angiogram showing left A1 fenestration (a-semisagittal view, b-frontal view) analogous with localization to previous case

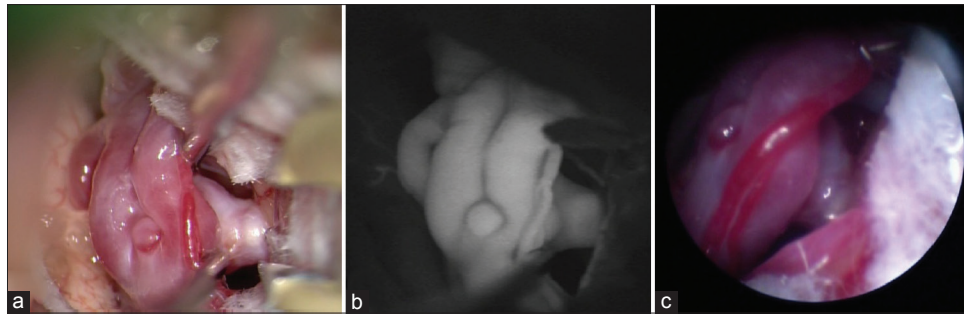


Figure 7: Intraoperative microscopic (a), indocyanine green videoangiography (b) and endoscopic (c) views of aneurysms a recurrent artery arising from middle part of the left channel of fenestration

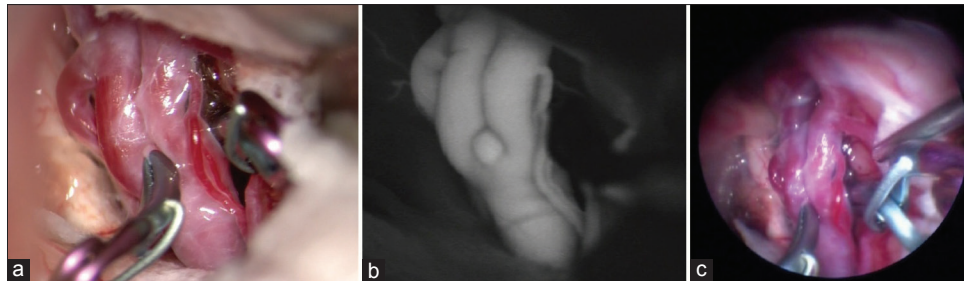


Figure 8: Two clips has been applied, first minor Sujita II clip with the size of 4 mm, and bigger Sujita I clip with the size of 6 mm. The occlusion checked on ICG (b) and endoscopic visualization (c) Two channels of A1 fenestration preserved successfully

period passed uneventful and the patient was discharged home neurologically intact. The patient is doing well until the last follow-up period. Postoperative follow-up 3DCT was performed 1 month later, which shows adequate lumen of fenestrated A1 [Figure 9].

## Discussion

The fenestrations are usually clinically silent, but, weakening of the vessels wall decreases the resistance to hemodynamic changes, so in proximal part of fenestration aneurysm may develop. During segmental duplication of the lumen into distinct channels while having same endothelial lining, they may or may not share adventitial layer.<sup>[2]</sup>

According to the literature, fenestrations of the cerebral arteries mostly occur in the posterior circulation, the vertebral artery, the basilar artery, and the middle cerebral artery.<sup>[1,2]</sup> According to Yamada *et al.*, fenestrations have angiographical incidence of 0.3–0.9% and frequently associated with aneurysms.<sup>[3]</sup>

The fenestration of cerebral arteries is congenital anomalies with reported prevalence ranging from 0.3% to 28.0% depending on the study methods.<sup>[4]</sup> The fenestration of the A1 segment of the ACA was first described by Fawcett and Blachford in 1905. They found its incidence to be 0.14% in 700 brains. In 1976, Perlmutter and Rhoton reported two cases of unilateral A1 fenestrations in fifty cadaver brains.<sup>[5]</sup>

Fenestrations of the cerebral vessels are frequently associated with other vascular anomalies and saccular

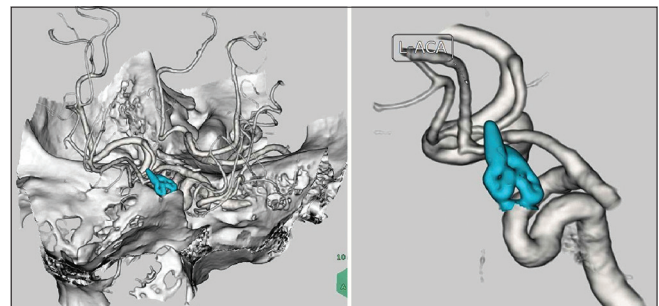


Figure 9: Postoperative three-dimensional computed tomography angiogram depicts a obliteration of the aneurysms and normal functioning fenestrated A1 segment. The clip was colored into blue

aneurysms. Of the 76 reported cases, 25 were associated with an aneurysm at the fenestrated segment itself, with one interpreted as fusiform and the remaining being saccular. Saccular aneurysms involved the proximal segment of the fenestration except for one case.<sup>[6]</sup> In our first case, the saccular aneurysm arose from the proximal part of the fenestration of right A1, and the left A1 was smaller than the right one.

## Anatomical aspects

Arterial fenestration is a segmental duplication of arterial vessels which is a rare anomaly, resulting in incomplete fusion of primitive embryological vessels. In fenestration, the vessels lumen divides into two parallel channels then rejoins distally. From anatomic point of view, these two channels have their own intima and muscular layers, but may or may not share an adventitial sheath.<sup>[7]</sup> Duplication or fenestration of arteries are the second most common

variants after hypoplastic arteries and are found more frequent in the anterior circulation of the brain. Fenestration usually considered to be the result of the incomplete fusion of arteries during embryonic development. However some authors believe fenestration can be induced by the transarterial course of a nerve, a bony structure or enlarged vasa vasorum along the path of the artery.<sup>[8-10]</sup>

### Surgical aspects

The origin of the A1 perforators in a fenestrated A1 segment is important in both endovascular and open surgical approaches for the treatment of associated aneurysms. The A1 segment generally supplies the optic chiasm, anterior third ventricle and hypothalamus, medial third of the anterior commissure, caudate head, globus pallidus, anterior limb of internal capsule, and rostral thalamus.<sup>[11,12]</sup> Thus, the origins of the major perforators should be identified if occlusion of the fenestrated arm is being considered. The presence of perforators arising from both limbs suggests that perforator distribution infarction may occur if sacrifice of either limb is contemplated during treatment of fenestration-associated aneurysms.

### Conclusion

We demonstrated two cases of unilateral fenestration and aneurysm of the A1 segment ACA which is usually uncommon. The fenestration of the A1 segment is known to be associated with various anomalies, in our case, it is the aneurysms, so existing fenestration, predisposing to the development of even multiple aneurysms and the fact that the perforators can arise from the neck of aneurysm is important in the planning of the clipping surgery.

### Financial support and sponsorship

Nil.

### Conflicts of interest

There are no conflicts of interest.

### References

1. Yasargil M. Operative anatomy. In: Microneurosurgery. Vol. 1. New York: Georg Thieme Verlag; 1984. p. 99-116.
2. Menshawi K, Mohr JP, Gutierrez J. A Functional Perspective on the Embryology and anatomy of the cerebral blood supply. *J Stroke* 2015;17:144-58.
3. Yamada T, Inagawa T, Takeda T. Ruptured aneurysm at the anterior cerebral artery fenestration. Case report. *J Neurosurg* 1982;57:826-8.
4. Fawcett E, Blachford JV. The circle of Willis: An examination of 700 specimens. *J Anat Physiol* 1905;40(Pt 1):63.2-70.
5. Perlmutter D, Rhoton AL Jr. Microsurgical anatomy of the anterior cerebral-anterior communicating recurrent artery complex. *J Neurosurg* 1976;45:259-72.
6. Koh JS, Kim EJ, Lee SH, Bang JS. Ruptured aneurysm arising from the distal end of a proximal A1 fenestration: Case report and review of the literature. *J Korean Neurosurg Soc* 2009;45:43-5.
7. Leyon JJ, Kaliaperumal C, Choudhari KA. Aneurysm at the fenestrated anterior cerebral artery: Surgical anatomy and management. *Clin Neurol Neurosurg* 2008;110:511-3.
8. Kachhara R, Nair S, Gupta AK. Fenestration of the proximal anterior cerebral artery (A1) with aneurysm manifesting as subarachnoid hemorrhage – Case report. *Neurol Med Chir (Tokyo)* 1998;38:409-12.
9. Aktüre E, Arat A, Niemann DB, Salamat MS, Baskaya MK. Bilateral A1 fenestrations: Report of two cases and literature review. *Surg Neurol Int* 2012;3:43.
10. Sonda I, Basso LS. Fenestrated A1 segment of right anterior cerebral artery associated to duplicated anterior communicating artery. *Anatomy* 2015;9:42-4.
11. Kwon WK, Park KJ, Park DH, Kang SH. Ruptured saccular aneurysm arising from fenestrated proximal anterior cerebral artery: Case report and literature review. *J Korean Neurosurg Soc* 2013;53:293-6.
12. Dunker RO, Harris AB. Surgical anatomy of the proximal anterior cerebral artery. *J Neurosurg* 1976;44:359-67.