

## Coccygectomy for Coccygodynia: A Single Center Experience Over 5 Years

### Abstract

**Introduction:** Coccygodynia refers to a pathological condition in which pain occurs in the coccyx or its immediate vicinity. The pain is usually provoked by sitting or rising from sitting. Several studies have reported good or excellent results after coccygectomy especially in patients who are refractory to conservative treatment. **Aims and Objectives:** This study aims to evaluate the role and effectiveness of coccygectomy in chronic refractory coccygodynia. **Materials and Methods:** Between January 2011 and January 2015, 16 consecutive patients (4 males and 12 females) who underwent surgical coccygectomy were enrolled prospectively in the study. All patients suffered from treatment-resistant coccygodynia and had exhausted conservative therapeutic options for at least 6 months before undergoing surgery. The same surgeon performed a complete coccygectomy on all patients. Postoperative outcomes included measurements of pain relief and degree of patient satisfaction with the procedure's results. **Results:** The average age of patient was 37.93 years (range: 25–53 years), and the male to female ratio was 1:3. The median duration of patient-reported symptoms prior to surgery was 24 months. The most common cause of coccygodynia was direct or indirect trauma, recorded in 11 patients (68.75%). Idiopathic coccygodynia was five cases (31.25%). The number of patients with outcomes rated as “excellent,” “good,” “fair,” and “poor” were 12, 2, 1, and 1, respectively. The favorable result (excellent or good) was 87.5%. The self-reported visual analog scale (VAS) was significantly improved by surgery. The mean VAS preoperatively was 9.62, and postoperatively it was 2.25 ( $P < 0.001$ ). There were two infections (12.5%) among the 16 patients which were managed conservatively. **Conclusions:** Coccygectomy for chronic intractable coccygodynia is simple and effective, with a low complication rate.

**Keywords:** Coccygectomy, coccygodynia, sacrococcygeal joint

### Introduction

The coccyx is the terminal segment of the spine. The term “coccyx” is derived from the Greek word for the beak of a cuckoo bird because of the similarity in appearance when the latter is viewed from the side.<sup>[1-3]</sup>

Coccygodynia refers to a pathological condition in which pain occurs in the coccyx or its immediate vicinity.<sup>[4]</sup> Notably, when a seated individual leans back, the weight load is borne almost entirely by the coccyx and gives rise to classic pain syndrome when a person leans backward.<sup>[5]</sup>

Surgical treatment for coccygodynia has been viewed with caution historically<sup>[4]</sup> as it has been associated with high complication rates and variable effectiveness. Better outcomes with coccygectomy have been reported more recently.<sup>[6]</sup>

This is an open access journal, and articles are distributed under the terms of the Creative Commons Attribution-NonCommercial-ShareAlike 4.0 License, which allows others to remix, tweak, and build upon the work non-commercially, as long as appropriate credit is given and the new creations are licensed under the identical terms.

For reprints contact: reprints@medknow.com

### Materials and Methods

Between January 2011 and January 2015, 16 consecutive patients (4 males and 12 females) who underwent surgical coccygectomy were enrolled in the study. All patients suffered from treatment-resistant coccygodynia and had exhausted conservative therapeutic options for at least 6 months before undergoing surgery. The nonoperative treatment included cushions, nonsteroidal anti-inflammatory drugs (NSAIDs), physiotherapy, and steroid injections. Special note was made regarding whether patients' believed that they had been misdiagnosed prior to surgery, and whether there was a history of a fall onto the buttocks or other inciting trauma. In addition, none of the patients had a reported psychiatric disorder.

On preoperative clinical examination, all patients showed marked tenderness on palpation over the coccyx. A digital rectal

**How to cite this article:** Sarmast AH, Kirmani AR, Bhat AR. Coccygectomy for coccygodynia: A single center experience over 5 years. *Asian J Neurosurg* 2018;13:277-82.

**Arif Hussain  
Sarmast,  
Altaf Rehman  
Kirmani,  
Abdul Rashid Bhat**

*Department of Neurosurgery,  
Sher-I-Kashmir Institute of  
Medical Sciences, Soura,  
Srinagar, Jammu and Kashmir,  
India*

### Address for correspondence:

*Dr. Arif Hussain Sarmast,  
Dalipora Kawadara,  
Srinagar - 190 002,  
Jammu and Kashmir, India.  
E-mail: arifhsarmast@gmail.  
com*

### Access this article online

**Website:** www.asianjns.org

**DOI:** 10.4103/1793-5482.228568

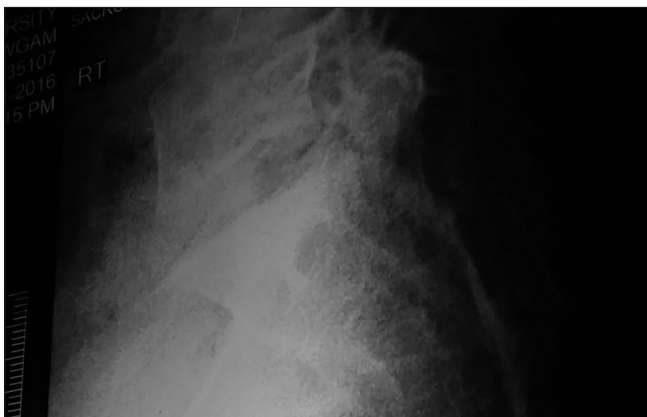### Quick Response Code:



examination was performed to rule out a rectal-based pathology. All patients had undergone preoperative noncontrast radiographic imaging of the sacrum in two planes and a magnetic resonance imaging (MRI) scan of the region [Figures 1 and 2]. The senior author (Altaf Rehman Kirmani) performed surgery in all cases with subperiosteal dissection. We used a nonvalidated standardized questionnaire designed specifically for this study. Patients were asked to describe their symptoms before surgery, to quantify their pain before and after surgery by using a visual analog scale (VAS). Finally, the patients were asked whether their quality of life had improved after surgery and whether they would choose the operation if they had to make the choice a second time, whether they would choose to have the operation sooner after the symptoms had started, and whether they would recommend the operation to others.

The success of the operation was determined on the basis of collected data. An “excellent” result was achieved with complete absence of pain or significant improvement of pain; this was operationalized as a VAS <2 of 10 and an increase in quality of life. A significant improvement in pain (relief of most pain but mild discomfort after prolonged sitting) and a VAS <3 out of 10 was classified as a “good” result. A moderate improvement of pain (minimal or no pain relief) and a VAS <6 out of 10 was classified as a “satisfactory” outcome. Unchanged pain symptoms, an increase in complaints, or a VAS at the time of the investigation of more than 6 out of 10 was classified as a “poor” result. A note was made of the duration of stay in the hospital and any postoperative complication.

Statistical analysis of the data was performed using the Statistical Package for the Social Sciences (SPSS), version 16.0 (SPSS, Inc., Chicago, IL, USA). Continuous variables were expressed as the mean  $\pm$  standard deviation, and categorical variables were expressed as frequencies and percentages. Odds ratios and 95% confidence intervals were calculated by means of simple logistic regression analysis.  $P < 0.05$  was considered statistically significant.



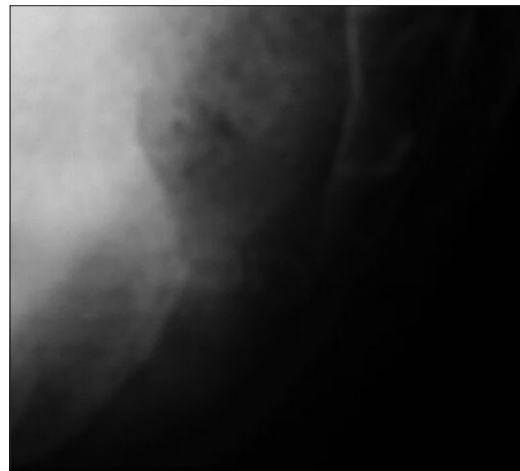
**Figure 1:** X ray Lateral view of the coccyx showing type III coccyx with an angulation of >90 degrees

## Results

The average patient age was 37.93 years (range: 25–53 years), and the male to female ratio was 1:3. The median duration of patient-reported symptoms prior to surgery was 24 months. The most common cause of coccygodynia was direct or indirect trauma, recorded in 11 patients (68.75%). Idiopathic coccygodynia was five cases (31.25%). Patients had been evaluated with lateral sacrococcygeal radiographs we could classify the coccyx according to the schema described by Postacchini and Massobrio. Of these coccyges, five were Type I (31.25%), two were Type II (12.5%), four were Type III (25%), and five were Type IV (31.25%). The number of patients with outcomes rated as “excellent,” “good,” “fair,” and “poor” were 12, 2, 1, and 1, respectively. The favorable result (excellent or good) was 87.5%. The self-reported VAS was significantly improved by surgery. The mean VAS preoperatively was 9.62, and postoperatively it was 2.25 ( $P < 0.001$ ). There were two infections (12.5%) among the 16 patients which were managed conservatively. There were no cases of any rectal injury. No significant difference in outcome could be detected based on traumatic versus nontraumatic causes ( $P = 0.33$ ). In summary, the self-reported VAS was significantly improved by surgery, and the overall favorable result (excellent or good) was 84.6% as shown in Table. Our numbers were small, but the outcome appeared to be durable over time and not dependent on the cause of pain. The median duration of patient-reported symptoms prior to surgery was 21.68 months. A total of 31% of patients claimed they had been misdiagnosed as having some other pathological condition explaining their coccygodynia, 87% of patients stated they would undergo the operation again if faced with the same situation, 93% of patients would have had the procedure sooner if they had been given the option, and 87% would recommend the surgery to others.

## Discussion

The term “coccygodynia” was coined by Simpson in 1859.<sup>[7]</sup> The pain is usually provoked by sitting or rising



**Figure 2:** X ray Lateral view (enlarged view) of the coccyx showing abnormally angulated coccyx

**Table: Overview of the enrolled cases**

Case number	Age in years	Gender	History	Conservative Mx*	Conservative Mx* duration (months)	Radiological finding type of coccyx	Complications	VAS preoperative	VAS postoperative	Outcome
1	37	Female	Traumatic	1, 2 <sup>+</sup>	12	IV	None	10	2	Excellent
2	37	Male	Traumatic	1, 2, 3, 4	7	IV	None	9	1	Excellent
3	45	Female	Traumatic	1, 2, 3	9	I	None	10	2	Excellent
4	53	Female	Idiopathic	1, 2, 4	24	II	None	10	2	Excellent
5	34	Female	Traumatic	1, 2, 3	34	III	Wound infection	8	3	Good
6	25	Male	Idiopathic	1, 3	32	I	None	10	1	Excellent
7	27	Female	Traumatic	1, 2, 3, 4	23	IV	None	10	2	Excellent
8	34	Female	Traumatic	1, 2, 3	12	II	None	9	5	Fair
9	46	Male	Traumatic	1, 2, 3	23	I	None	10	1	Excellent
10	48	Female	idiopathic	1, 3	12	III	Wound infection	10	3	Good
11	32	Female	Traumatic	1, 3	18	II	None	10	2	Excellent
12	33	Female	Idiopathic	1, 2, 3	23	IV	None	9	7	Poor
13	34	Male	Traumatic	1, 2, 3, 4	26	I	None	10	1	Excellent
14	45	Female	Traumatic	1, 2, 3	29	II	None	10	2	Excellent
15	34	Female	Traumatic	1, 2, 3	33	IV	None	9	1	Excellent
16	43	Female	Idiopathic	1, 3, 4	30	I	None	10	1	Excellent

\*Mx – Management; <sup>+</sup>1 – Oral pain medications; 2 – Physical therapy; 3 – Local injection; 4 – Pericoccygeal steroid injection. VAS – Visual analog scale

from sitting.<sup>[8]</sup> Most cases are associated with abnormal mobility of the coccyx, which may trigger a chronic inflammatory process leading to degeneration of this structure.<sup>[9]</sup>

Postacchini and Massobrio described four types of configuration of the coccyx and designated them Type I through Type IV. In Type I, the coccyx is curved slightly forward with its apex directed downward and caudally. In Type II, the forward curvature is more marked, and the apex extends straightforward. In Type III, the coccyx most sharply angles forward. Finally in Type IV, the coccyx is subluxated at the sacrococcygeal or intercoccygeal joint. The coccygeal configuration also appears to influence the prevalence and causative lesion. Types II, III, and IV are more prone to become painful than those with Type I.<sup>[10]</sup> Anterior subluxation is a rare lesion and tends to occur in Type III and Type IV patterns. Posterior subluxation is more common in the straighter Type I configuration.<sup>[11]</sup>

Maigne *et al.*<sup>[11]</sup> described three types of coccygeal configuration, designating them from Type I through Type III. In Type I forward curvature of coccyx is more than 25°, in Type II coccyx is displaced or subluxed posteriorly and in Type III, coccyx is immobile with a spicule in the dorsal surface of the last coccygeal segment.

### Incidence and etiology

The exact incidence of coccydynia has not been reported; however, factors associated with increased risk of developing coccydynia include obesity and female gender. Women are 5 times more likely to develop coccydynia than

men. Adolescents and adults are more likely to present with coccydynia than children. Minor trauma can also occur from repetitive or prolonged sitting on hard, narrow, or uncomfortable surfaces.<sup>[11-13]</sup>

However, a study conducted by Maigne *et al.* has suggested that only a traumatic event occurring within 1 month of onset is significant in increasing the risk of instability and subsequent coccydynia.<sup>[11,14]</sup>

Nontraumatic coccydynia can result from a number of causes, including degenerative joint or disc disease, hypermobility or hypomobility of the sacrococcygeal joint, infectious etiology, and variants of coccygeal morphology. Coccydynia can also be radicular or referred pain, although this type of pain usually is not associated with the hallmark coccygeal tenderness on physical examination. Less commonly, neoplasms have been associated with coccydynia. Coccydynia can also be associated with nonorganic causes, such as somatization disorder and other psychological disorders. Idiopathic coccydynia has been described in the absence of any obvious pathologic changes involving the coccyx, although this is considered a diagnosis of exclusion; in these patients, the pain may actually result from spasticity or other abnormalities affecting the musculature of the pelvic floor.<sup>[15]</sup>

### Presentation

The classic presentation of coccydynia is localized pain over the coccyx. Patients present complaining of “tailbone pain.” The pain will usually be worse with prolonged sitting, leaning back while seated, prolonged standing, and

rising from a seated position. Pain may also be present with sexual intercourse or defecation. History may be significant for a recent trauma with an acute onset of pain, or the onset of pain may have been insidious with no clear inciting factor. Physical examination will reveal tenderness over the coccyx. Rectal examination allows the coccyx to be grasped between the forefinger and thumb. Manipulation will elicit pain and may reveal hypermobility or hypomobility of the sacrococcygeal joint.<sup>[11]</sup> Coccygodynia is also qualified as acute or chronic. Chronic coccygodynia is defined as lasting >2 months.<sup>[16]</sup>

### Differential diagnosis

The differential diagnosis of coccygodynia is large and includes lumbar spondylosis or disc herniation, proctalgia fugax, levator ani syndrome, Alcock canal syndrome, descending perineal syndrome, piriformis syndrome, anogenital syndrome, perianal abscess or fistula, and rectal tumors or teratomas.<sup>[17]</sup> Tarlov cyst has been reported as a rare cause of coccygodynia.<sup>[18]</sup> Care must be taken to exclude patients with offending local pathological conditions or atypical symptoms from consideration for coccygectomy. Primary coccygodynia is distinguished from referred coccygodynia (so-called pseudococcygodynia)<sup>[19]</sup> by infiltrating the periosteum at the tender point with 10 ml of 0.25% bupivacaine and 40 mg of methylprednisolone acetate, which will elicit temporary symptomatic relief in primary coccygodynia.

### Diagnosis: Imaging studies

#### Dynamic radiographs

Single position radiographs seldom demonstrate any definitive morphologic differences between normal individuals and patients with coccydynia; hence, these views are not diagnostic.<sup>[10]</sup> Dynamic radiographs obtained in both the sitting and standing positions may be more useful than static X-rays because they allow for measurement of the sagittal rotation of the pelvis and the coccygeal angle of incidence. A comparison of sitting and standing films will yield radiographic abnormalities in up to 70% of symptomatic coccydynia cases.<sup>[14]</sup>

A coccyx normally pivots between 5° and 25° when the patient sits and returns to its original angle once the subject stands. In contrast, individuals with coccydynia frequently exhibit coccygeal displacement, immobility (<5° motion) or hypermobility (described as flexion of >25° of motion) on lateral radiographs.<sup>[14,20]</sup>

#### Computed tomography/magnetic resonance imaging

Advanced imaging modalities may be also be utilized to establish a diagnosis of coccydynia, although these techniques may not be as accurate as dynamic radiographs. Lumbosacral MRI with contrast is recommended in all patients to define normal and abnormal bony anatomy and to rule out less common causes of coccygodynia, such as abscess or tumors. Computed tomography (CT) is superior to MRI in

defining normal and abnormal bony anatomy. CT should be ordered in cases of acute pelvic trauma, and as an adjunct to MRI in evaluating neoplastic disease. MRI and technetium Tc-99m bone scans may demonstrate inflammation of the sacrococcygeal area indicative of coccygeal hypermobility. Provocative testing of the coccyx, such as pressing on the region with a blunted needle to elicit pain, and pain relief with the injection of local anesthetic under fluoroscopic guidance may also be useful in diagnosis as well.<sup>[14]</sup>

### Nonoperative management

Several nonoperative interventions are currently used for the management of coccydynia including NSAIDs, hot baths, ring-shaped cushions, intrarectal massage, and manipulation (manual therapy steroid injection dextrose prolotherapy ganglion impar blocks radiofrequency thermocoagulation and psychotherapy.<sup>[15,21-28]</sup>

In a published report by Foye *et al.*, nerve blocks using local anesthetics with a fast onset (e.g., lidocaine) were shown to provide substantial relief even by the time a patient sat up on the procedure table. After the local anesthetic block wears off, some of the coccyx pain may start to return, but generally it returns at a much lower severity than existed prior to the injection. Physical medicine and rehabilitation coccydynia physicians and researchers at the New Jersey Medical School refer to this new plateau of severity as “resetting the thermostat.” Published reports document that some patients with coccydynia receive complete and permanent relief through a single ganglion impar block.<sup>[27]</sup>

Thermocoagulation of the ganglion impar using radiofrequency ablation has been reported.<sup>[28,29]</sup> Ablation can also be accomplished chemically (e.g., by carefully injecting neurotoxic agents such as phenol and/or ethyl alcohol directly onto the targeted nerve tissues). These coccygeal ablation injections have been in clinical use for multiple decades and thus are no longer considered experimental.<sup>[1]</sup>

Maigne *et al.*<sup>[21]</sup> reported intrarectal manipulation had only mild effectiveness in the treatment of chronic coccydynia and tended to be more successful in patients with posttraumatic etiology, a stable coccyx, and shorter duration of symptoms. Khatri *et al.*<sup>[22]</sup> reported that intrarectal manipulation was effective for treating idiopathic coccydynia.

### Operative management-coccygectomy

Several studies have reported good or excellent results after coccygectomy.<sup>[3,10,30-41]</sup>

### Surgical technique

#### Preoperative preparation

Before being listed for coccygectomy, each patient must have failed medical therapy and nonsurgical treatment. This

includes the failure of manipulation under anesthesia and at least two attempts at local anesthetic and steroid infiltration.

Some surgeons prefer to create a subperiosteal plane on both sides of tip by sharp dissection and leave the ligamentous and muscular attachments along with periosteum behind. Coccyx is separated from the surrounding tissues in a subperiosteal plane using monopolar electrocautery, elevating the coccyx posteriorly, and proceeding with an *en bloc* resection in a rostral to caudal direction according to the method of key.<sup>[36]</sup>

Dissection from a proximal to distal direction limits the risk of rectal injury, especially in the case of an anteverted coccyx. *En bloc* resection prevents treatment failures secondary to incomplete resection. The results of a recent study show that periosteum preservation and closure result in low risk of postoperative infection. Care is taken in excising the coccyx as it lies close to the rectum. Gardener described a technique in mobilizing the rectum and dense fascia deep to sacrococcygeal joint with advantages of protecting the rectum, less risk of infection, and more rapid healing.<sup>[36]</sup>

After the coccyx is removed, the distal prominent end of the sacrum is beveled. Usually, a small drain is placed if the dead space is left and a small dressing is applied.<sup>[36]</sup>

Nevertheless, wound infection is the most important complication of this procedure. Apart from total coccygectomy, a partial resection of the coccyx has also been described for the surgical treatment of coccygodynia. Postacchini and Massobrio reported no difference in the outcome for partial resection compared to that of complete coccygeal resection.<sup>[10]</sup> However, other authors have demonstrated superior postoperative outcomes with complete coccygectomy in comparison to partial coccygectomy.<sup>[34]</sup> In our series, only a complete resection was performed.

### Complications

Coccygectomy may seem to be a technically facile procedure. However, myriad complications have been documented in the extant literature. In a review of 24 studies involving 671 patients, an overall 11% complication rate has been reported. Complication rates in studies varied from 0%<sup>[42]</sup> to 50%.<sup>[43]</sup> The most common complications cited were wound infections (8.34%), and wound healing problems with dehiscence. Delayed healing (0.9%) and wound hematomas (0.3%) were also reported.<sup>[6]</sup> Wound infections were in the majority of cases superficial. Serious complications, such as severe infections or injuries of the intestinal tract and rectal prolapse, have also been described; however, these were extremely rare.<sup>[6]</sup> In myriad studies, perioperative antibiotic prophylaxis was administered. The local skin flora, proximity to the anus, and hygiene difficulties due to the anatomical location of the operative site increase the risk of contamination.

The most common causative agents of postoperative wound infection were gram-negative rods.<sup>[31]</sup> Several studies have shown that a 5-day course of postoperative antibiotics (second-generation cephalosporins) can effectively reduce the infection rate.<sup>[20,35,40,43]</sup>

### Conclusion

Coccygectomy for chronic incapacitating coccygodynia is a valid treatment option with high success and low complication rate .

### Financial support and sponsorship

Nil.

### Conflicts of interest

There are no conflicts of interest.

### References

1. Howorth B. The painful coccyx. Clin Orthop 1959;14:145-60.
2. Sugar O. Coccyx. The bone named for a bird. Spine (Phila Pa 1976) 1995;20:379-83.
3. Pennekamp PH, Kraft CN, Stütz A, Wallny T, Schmitt O, Diedrich O. Coccygectomy for coccygodynia: Does pathogenesis matter? J Trauma 2005;59:1414-9.
4. Duncan GA. Painful coccyx. Arch Surg 1937;34:1088-104.
5. Johnson PH. Coccygodynia. J Ark Med Soc 1981;77:421-4.
6. Karadimas EJ, Trypsiannis G, Giannoudis PV. Surgical treatment of coccygodynia: An analytic review of the literature. Eur Spine J 2011;20:698-705.
7. Powers JA. Coccygectomy. South Med J 1957;50:675-8.
8. Kerr EE, Benson D, Schrot RJ. Coccygectomy for chronic refractory coccygodynia: Clinical case series and literature review. J Neurosurg Spine 2011;14:654-63.
9. Patel R, Appannagari A, Whang PG. Coccydynia. Curr Rev Musculoskelet Med 2008;1:223-6.
10. Postacchini F, Massobrio M. Idiopathic coccygodynia. Analysis of fifty-one operative cases and a radiographic study of the normal coccyx. J Bone Joint Surg Am 1983;65:1116-24.
11. Maigne JY, Doursounian L, Chatellier G. Causes and mechanisms of common coccydynia: Role of body mass index and coccygeal trauma. Spine (Phila Pa 1976) 2000;25:3072-9.
12. Maigne JY, Pigeau I, Aguer N, Doursounian L, Chatellier G. Chronic coccydynia in adolescents. A series of 53 patients. Eur J Phys Rehabil Med 2011;47:245-51.
13. Schapiro S. Low back and rectal pain from an orthopedic and proctologic viewpoint; with a review of 180 cases. Am J Surg 1950;79:117-28.
14. Fogel GR, Cunningham PY 3<sup>rd</sup>, Esses SI. Coccygodynia: Evaluation and management. J Am Acad Orthop Surg 2004;12:49-54.
15. Nathan ST, Fisher BE, Roberts CS. Coccydynia: A review of pathoanatomy, aetiology, treatment and outcome. J Bone Joint Surg Br 2010;92:1622-7.
16. Mlitz H, Jost W; German Society of Coloproctology; Germany Society of Dermatology. Coccygodynia. J Dtsch Dermatol Ges 2007;5:252-4.
17. Schrot RJ. Coccygodynia. Epocrates Online. Available from: <https://www.online.epocrates.com/u/29411067/Coccygodynia>. [Last accessed on 2010 Dec 15].
18. Ziegler DK, Batnitzky S. Coccygodynia caused by perineural

- cyst. *Neurology* 1984;34:829-30.
19. Traycoff RB, Crayton H, Dodson R. Sacrococcygeal pain syndromes: Diagnosis and treatment. *Orthopedics* 1989;12:1373-7.
  20. Maigne JY, Lagauche D, Doursounian L. Instability of the coccyx in coccydynia. *J Bone Joint Surg Br* 2000;82:1038-41.
  21. Maigne JY, Chatellier G, Faou ML, Archambeau M. The treatment of chronic coccydynia with intrarectal manipulation: A randomized controlled study. *Spine (Phila Pa 1976)* 2006;31:E621-7.
  22. Khatri SM, Nitsure P, Jatti RS. Effectiveness of coccygeal manipulation in coccydynia: A randomized control trial. *Indian J Physiother Occup Ther* 2011;5:110-2.
  23. Wu CL, Yu KL, Chuang HY, Huang MH, Chen TW, Chen CH. The application of infrared thermography in the assessment of patients with coccygodynia before and after manual therapy combined with diathermy. *J Manipulative Physiol Ther* 2009;32:287-93.
  24. Khan SA, Kumar A, Varshney MK, Trikha V, Yadav CS. Dextrose prolotherapy for recalcitrant coccygodynia. *J Orthop Surg (Hong Kong)* 2008;16:27-9.
  25. Datir A, Connell D. CT-guided injection for ganglion impar blockade: A radiological approach to the management of coccydynia. *Clin Radiol* 2010;65:21-5.
  26. Demircay E, Kabatas S, Cansever T, Yilmaz C, Tuncay C, Altinors N. Radiofrequency thermocoagulation of ganglion impar in the management of coccydynia: Preliminary results. *Turk Neurosurg* 2010;20:328-33.
  27. Foye PM, Buttaci CJ, Stitik TP, Yonclas PP. Successful injection for coccyx pain. *Am J Phys Med Rehabil* 2006;85:783-4.
  28. Mitra R, Cheung L, Perry P. Efficacy of fluoroscopically guided steroid injections in the management of coccydynia. *Pain Physician* 2007;10:775-8.
  29. Atim A, Ergin A, Bilgiç S, Deniz S, Kurt E. Pulsed radiofrequency in the treatment of coccygodynia. *Agri* 2011;23:1-6.
  30. Balain B, Eisenstein SM, Alo GO, Darby AJ, Cassar-Pullicino VN, Roberts SE, *et al.* Coccygectomy for coccydynia: Case series and review of literature. *Spine (Phila Pa 1976)* 2006;31:E414-20.
  31. Bayne O, Bateman JE, Cameron HU. The influence of etiology on the results of coccygectomy. *Clin Orthop Relat Res* 1984;190:266-72.
  32. Doursounian L, Maigne JY, Faure F, Chatellier G. Coccygectomy for instability of the coccyx. *Int Orthop* 2004;28:176-9.
  33. Grosso NP, van Dam BE. Total coccygectomy for the relief of coccygodynia: A retrospective review. *J Spinal Disord* 1995;8:328-30.
  34. Hellberg S, Strange-Vognsen HH. Coccygodynia treated by resection of the coccyx. *Acta Orthop Scand* 1990;61:463-5.
  35. Hodges SD, Eck JC, Humphreys SC. A treatment and outcomes analysis of patients with coccydynia. *Spine J* 2004;4:138-40.
  36. Key JA. Operative treatment of coccygodynia. *J Bone Joint Surg Am* 1937;19:759-64.
  37. Perkins R, Schofferman J, Reynolds J. Coccygectomy for severe refractory sacrococcygeal joint pain. *J Spinal Disord Tech* 2003;16:100-3.
  38. Pyper JB. Excision of the coccyx for coccydynia; a study of the results in twenty-eight cases. *J Bone Joint Surg Br* 1957;39:733-7.
  39. Sehrioglu A, Ozturk C, Oguz E, Emre T, Bek D, Altinmakas M. Coccygectomy in the surgical treatment of traumatic coccygodynia. *Injury* 2007;38:182-7.
  40. Wood KB, Mehdod AA. Operative treatment for coccygodynia. *J Spinal Disord Tech* 2004;17:511-5.
  41. Wray CC, Easom S, Hoskinson J. Coccydynia. Aetiology and treatment. *J Bone Joint Surg Br* 1991;73:335-8.
  42. Traub S, Glaser J, Manino B. Coccygectomy for the treatment of therapy-resistant coccygodynia. *J Surg Orthop Adv* 2009;18:147-9.
  43. Cebesoy O, Guclu B, Kose KC, Basarir K, Guner D, Us AK. Coccygectomy for coccygodynia: Do we really have to wait? *Injury* 2007;38:1183-8.