

Neurocysticercosis in Japan

Abstract

Neurocysticercosis is a condition rarely reported in Japan, and therefore, the specific route of infestation in our set up has not been conclusively elucidated. Preoperative diagnosis remains difficult to make with certainty due to the slowly evolving nature of the disease and the fact that there are no typical characteristic clinical findings particularly associated with the disease. The hematological, serological, serum biochemistry, stool, and radiological tests were nonspecific for neurocysticercosis. The characteristic neuro-imaging findings were demonstrated in this case, and histopathology confirmed *Taenia solium* parenchymal infestation.

Keywords: Neurocysticercosis, neuro-imaging, *Taenia solium*

Introduction

Inadvertent ingestion of the eggs of pork tapeworm *Taenia solium* through food contaminated by people with teniasis, eating of raw meat or inadequately cooked pork may predispose to neurocysticercosis.^[1,2]

Human beings are the definitive hosts, whereas pigs are secondary. The affected patients may present with single, or multiple parenchymal lesions. Neurocysticercosis is the most common cause of acquired epilepsy in areas where the disease is endemic.^[3]

However, due to migration and movement of people, there may be occurrences in the developed parts of the world as well as we hereby report.

Case Report

A previously immunocompetent 63-year-old woman presented at the Nagano Municipal Hospital in June 2010 complaining of dizziness. There were no significant findings on physical examination, and radiological investigations were essentially normal [Figure 1a and b].

A year later, follow-up magnetic resonance imaging (MRI) scan demonstrated an area of hyper-intensity on the fluid-attenuated inversion recovery sequence [Figure 1c]. This was repeated in July 2012, and the signal area was noted to be larger than in the previous scan [Figure 1d]. In April

2013, further imaging studies showed a progressive increase in the size of the nodular lesion and calcification was noted on the computed tomography (CT) scan as a new finding [Figure 1e-g].

She had a history of travel to Singapore for sightseeing 18 years ago, although she had lived in Japan for the better part of her life. She enjoyed a plate of venison every summer but had never eaten raw or semi-cooked pork. Ten years ago, she ate raw Iwana mountain trout (*Salvelinus pluvinus*). Her family history was non-contributory and she had no significant past medical history.

On examination, her vital signs were essentially within normal limits and she had no neurological deficits. Radiological examination of her chest demonstrated areas of chronic inflammation on the lung fields. Her lower and upper limbs X-rays showed no calcifications. There were no parasites noted in her stool examination. Hematological tests revealed that the basophils were within the normal range 1.5% (0.2–7.3%) and a slightly raised lymphocytes count 51.5% (21.3–50.2%). Immunoglobulin E (IgE) titers were noted to be approximately twice the upper limit 517.7 IU/ml (reference range of <295 IU/ml). The C-reactive protein reading was 0.04 (<15) and the erythrocyte sedimentation rate 34 mm (<15 mm) at 1 h and 64 mm at 2 h (<40 mm). The serum chemistry showed no abnormalities.

How to cite this article: Kwasi V, Kodama K, Uchiyama T, Kusano Y, Shimizu T, Tokushige K, et al. Neurocysticercosis in Japan. Asian J Neurosurg 2018;13:518-21.

**Victor Kwasi,
Kunihiko Kodama,
Toshiya Uchiyama,
Yoshikazu Kusano,
Toshiyuki Shimizu,
Kazuo Tokushige,
Toshiki Takemae**

Department of Neurosurgery,
Nagano Municipal Hospital,
Japan

Address for correspondence:

Dr. Kunihiko Kodama,
Department of Neurosurgery,
Nagano Municipal Hospital
Tomitake 1333-1,
Nagano, 381-8551, Japan.
E-mail: kunikodama@gmail.com

Access this article online

Website: www.asianjns.org

DOI: 10.4103/1793-5482.228561

Quick Response Code:



This is an open access journal, and articles are distributed under the terms of the Creative Commons Attribution-NonCommercial-ShareAlike 4.0 License, which allows others to remix, tweak, and build upon the work non-commercially, as long as appropriate credit is given and the new creations are licensed under the identical terms.

For reprints contact: reprints@medknow.com

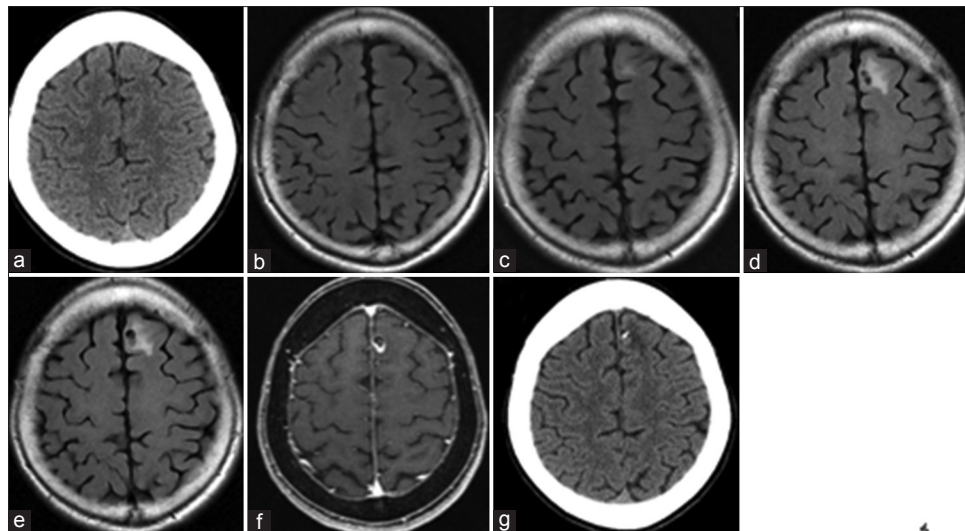


Figure 1: Preoperative magnetic resonance imaging scans done in June 2010, axial sections (a) and (b) with no visible lesion(s) noted within the brain parenchyma. A localized area of hyper-intensity was noted on the left frontal lobe in the fluid-attenuated inversion recovery sequence done in June 2012 as shown in (c) and an increase in the size was observed on the follow-up image as shown in (d) progressive increase in the size of lesion was seen on follow-up fluid-attenuated inversion recovery scan done in April 2013 as shown in (e) and the contrast enhanced T1 magnetic resonance imaging scan shown in (f) computed tomography scan done in April 2013 demonstrates calcification of the lesion as shown in (g)

Indications for surgery

Surgical extirpation of the lesion was considered in this case due to a gradually increasing left frontal lobe mass on sequential imaging. In addition, it was also considered prudent to obtain a histological specimen to make a proper diagnosis so as to plan for the definitive treatment.

Intra-operative findings

After durotomy, the arachnoid matter was seen to be thickened and the lesion noted to be hard in consistency [Figure 2a and b].

It was removed in *en bloc* fashion [Figure 2c].

Pathology results

Gross tissue specimen were sectioned and prepared for light microscopy as shown in Figure 3a. Histological examination demonstrated a shell-like structure with evidence of calcification on the surface with a small hook located within the calcified shell noted around the parasite's body [Figure 3b].

Granulomatous tissue surrounded the calcification with increased accumulation of lymphocytes. This observation was consistent with a diagnosis *T. solium* parasitic infestation and therefore, confirmed the histological diagnosis of neurocysticercosis.

Postoperative course

The patient recovered uneventfully and MRI scan done confirmed that the contrast enhanced nodular lesion had been removed completely [Figure 4a and b].

The blood lymphocytes count was 51.5% during the immediate postoperative period and 33.4% 1 month later,

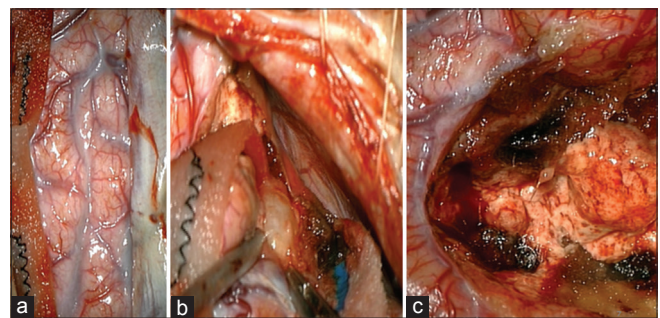


Figure 2: Intra-operative micrographs showing thickening of arachnoid matter (a), and the lesion located adjacent to the falx cerebri before and after en bloc removal as shown in (b) and (c), respectively

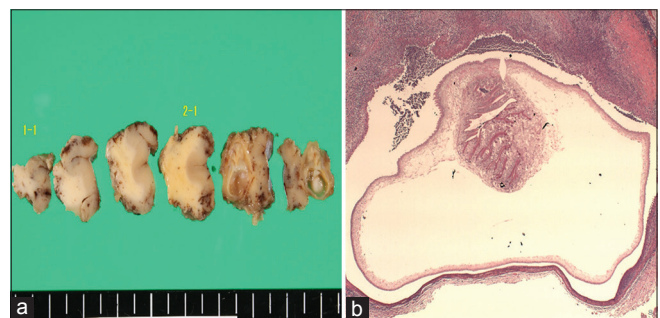


Figure 3: Histological sections preparation for light microscopy are shown in (a) the mounted slide demonstrated a shell with evidence of calcification on the inner surface and a hook like structure was noted on the parasite's body with surrounding granulation tissue (b)

whereas the basophils decreased from 1.5% to 0.8%. IgE titers dropped from 517.7 IU/ml to 310.7 IU/ml after 1 month.

Specific immunological antibody tests for *T. solium* in the blood were negative [Figure 5].

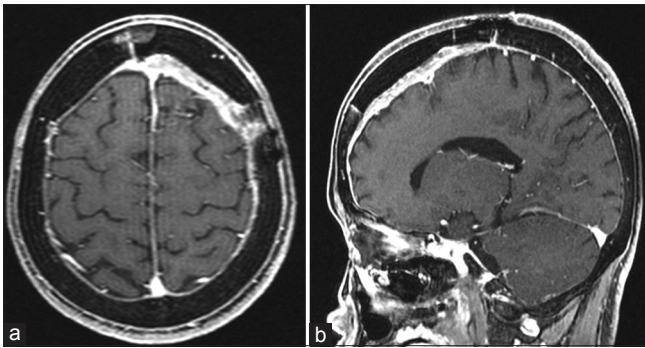


Figure 4: T1 contrast-enhanced post-operative magnetic resonance imaging scans on axial (a) and sagittal sections (b) respectively showing complete excision of the lesion

Discussion

Neurocysticercosis is the most common parasitic infestation of the central nervous system, and approximately 2.5 million people worldwide are infested with the adult tapeworm and others with cystic forms.^[1,2]

Clinical presentation depends on the location of the lesion, the number of parasites, and the host's immune response. Although most patients are asymptomatic, epilepsy is the most common initial presentation and accounts for 70% of the cases. Other symptoms include headaches, dizziness, psychiatric disturbances, reduced cognitive function, dysarthria, extra-ocular muscle movement weakness, hemiplegia or hemiparesis, sensory loss, movement disorders, gait disturbances, meningeal irritation, and hyper or hypo-reflexia depending on areas of the central nervous system where the parasites may be lodged.^[1,3-5]

Radiological diagnosis has been routinely made with the aid of CT or MRI scans. In this particular case, the chronological neuro-imaging findings showed the typical characteristics of neurocysticercosis. In the vesicular stage with viable larvae hypo-dense nonenhancing lesions were visible on CT scan whereas in the colloidal stage the lesions looked hypo- or iso-dense to the brain parenchyma with peripheral enhancement and peri-lesional edema. Nodular enhancing lesions may be seen in the nodular-granular stage. MRI scan was noted to be very useful in detecting changes, especially during the early stages of the disease.^[1,6,7]

In cases whereby the parasite was disseminated to other parts of the body, there may be evidence of calcification on X-ray imaging of the limbs or lung fields. Other tests included stool examination and 10–15% of neurocysticercosis patients usually demonstrate evidence of teniasis on stool microscopy studies.^[4,8]

Cerebrospinal fluid (CSF) studies are indicated for all patients presenting with new onset of seizures or neurological deficits and neuro-imaging may demonstrate solitary or multiple lesions. CSF findings include mononuclear pleocytosis, normal or low glucose levels,




Figure 5: Specific immuno-diagnostic test for *Taenia solium*, control on the left and the patients serum on the right column illustrating positive and negative antibody tests, respectively

elevated protein levels, high Immunoglobulin G index, oligoclonal bands, and eosinophilia (normal range 5–500 cells per microliter). CSF ELISA has a sensitivity of 50% and a specificity of 65%. However, these investigations were performed and found to be negative in this particular case.^[4,8,9]

Brain specimen biopsy may be considered to establish the definitive diagnosis only in situations whereby the potential benefits outweigh risks of surgery. Indications for surgical intervention and the recommended procedures may depend on the location and viability of cysts.^[4,6]

According to the American Academy of Neurology, parenchymal neurocysticercosis may be treated with albendazole and steroids. Anticonvulsants may be used, and monotherapy was usually adequate for the control of seizures, although there were still no clear guidelines regarding the standard duration of treatment for neurocysticercosis.^[4,5]

Conclusion

A surgical case of neurocysticercosis was reported, and the chronological neuro-imaging findings demonstrated the typical characteristic changes associated the disease. The diagnosis was confirmed on histology. Therefore, it would be important to understand the mode of transmission in our region, especially in patients with a high index of suspicion.

In Japan, this diagnosis may be too rare to be listed as a differential diagnosis, and therefore, we recommend that the possibility of neurocysticercosis should be considered and thus properly managed, especially for intracranial nodular lesions seen within our set up.

Acknowledgments

We would like to express our most sincere appreciation to Professor Pierre Chapuis and Jayne Seward, Discipline of

Surgery, The University of Sydney, for taking time out of their busy schedules in order to proof read the final draft of the manuscript. In addition, the authors are very grateful to Doctor Hiroshi Yamazaki, Department of Parasitology, National Institute of Infectious Diseases, Japan for the definitive diagnosis.

Financial support and sponsorship

Nil.

Conflicts of interest

There are no conflicts of interest.

References

1. Mewara A, Goyal K, Sehgal R. Neurocysticercosis: A disease of neglect. *Trop Parasitol* 2013;3:106-13.
2. Gubbay AD, Brophy BP, Henley S, Sage M. Neurocysticercosis. *J Clin Neurosci* 1998;5:203-7.
3. Gaffo AL, Guillén-Pinto D, Campos-Olazábal P, Burneo JG. Cysticercosis as the main cause of partial seizures in children in Peru. *Rev Neurol* 2004;39:924-6.
4. Baird RA, Wiebe S, Zunt JR, Halperin JJ, Gronseth G, Roos KL. Evidence-based guideline: Treatment of parenchymal neurocysticercosis: Report of the Guideline Development Subcommittee of the American Academy of Neurology. *Neurology* 2013;80:1424-9.
5. Proaño JV, Madrazo I, Avelar F, López-Félix B, Díaz G, Grijalva I. Medical treatment for neurocysticercosis characterized by giant subarachnoid cysts. *N Engl J Med* 2001;345:879-85.
6. Del Brutto OH. Neurocysticercosis: New thoughts on controversial issues. *Curr Opin Neurol* 2013;26:289-94.
7. Garg RK. Medical management of neurocysticercosis. *Neurol India* 2001;49:329-37.
8. Sinha S, Sharma BS. Neurocysticercosis: A review of current status and management. *J Clin Neurosci* 2009;16:867-76.
9. Rodriguez S, Wilkins P, Dorny P. Immunological and molecular diagnosis of cysticercosis. *Pathog Glob Health* 2012;106:286-98.