

Silent Migration of Ventriculoperitoneal Shunt per Anus in a Child: Management and Review of Literature

Abstract

The aim of this paper is to report a case of ventriculoperitoneal (VP) shunt tube coming out through the anus in a 6-year-old boy, who had undergone shunt revision surgery for the malfunctioning of the peritoneal end 6 months back. Among the complications of VP shunt surgery, such unusual migration of peritoneal end of the VP shunt is very rare. The possible factors responsible for this complication, in our case, were abdominal adhesions and thin bowel wall in the children. Although this complication has been previously reported, it remains an exceedingly rare case. Risk factors and possible mechanisms of migration are discussed.

Keywords: Anus, complications, migration, ventriculoperitoneal shunt

**Sachin Parshuram Guthe,
Survashe Pravin,
Poonam Darade¹,
Vernon Velho**

Departments of Neurosurgery and ¹Radiology, Grant Medical College and Sir JJ Group of Hospitals, Mumbai, Maharashtra, India

Introduction

Ventriculoperitoneal (VP) shunt placement is one of the common procedures done in neurosurgical practice. However, it can have many serious complications. In this study, we report a case of migrated peritoneal end of VP shunt which silently came out through the anus. Migration of peritoneal end of the VP shunt into the rectum, vagina, scrotum, abdominal wall, and mediastinum are other known rare complications. Risk factors and possible mechanisms of migration are discussed.

Case Report

A 6-year-old boy presented to us with a history of tube protruding per anus. He had undergone VP shunt (Chhabra-slit-in-spring silicone shunt) at the age of 4 years for congenital hydrocephalus followed by shunt revision 6 months back. After this revision surgery, in the postoperative period, he had mild abdominal pain and distension for 3 days which was settled with conservative management. The child was discharged on the postoperative day 10 with no complaints.

Six months later, the child presented to us with tube protruding through the anus. There was no history of fever, abdominal distension. Child did not have vomiting, headache, and loss of appetite. Clinical

examination did not reveal any signs of peritonitis or meningitis. Peritoneal end of the VP shunt was protruding through the anus [Figure 1]. There was dribbling of cerebrospinal fluid (CSF) at the distal end of VP shunt. Child was investigated with plain X-ray abdomen erect and ultrasonography of abdomen. X-ray abdomen erect confirmed the peritoneal end of the shunt tube going well beyond the pubic symphysis [Figure 2]. There was no knotting of the shunt tube seen. No gas under diaphragm was noted. Ultrasonography of the abdomen and pelvis could not trace the distal end of shunt tube. The absence of ascites further supported the diagnosis. After preoperative evaluation and counseling with parents, he was posted for surgery. A small incision was taken at the neck and the tube was cut. Then migrated peritoneal end of VP shunt which was visible per anus was gently pulled, and the shunt was delivered out. Remaining shunt system with shunt chamber was removed after exploring previous parietal incision. Postoperatively, the patient was kept nil by mouth for 1 day and then gradually started on oral feeds, after confirming the presence of peristalsis. Postoperatively, he did not have any features of raised intracranial pressure. After 3 weeks, repeat computed tomography of the brain showed no hydrocephalus; hence, no further CSF

Address for correspondence:

*Dr. Sachin Parshuram Guthe,
"Shrikant", C/O,
P D Guthe, Sant Sena
Nagar, Behind Jayakwadi
Office, Parbhani - 431 401,
Maharashtra, India.
E-mail: spgutte@gmail.com*

Access this article online

Website: www.asianjns.org

DOI: 10.4103/1793-5482.228559

Quick Response Code:



How to cite this article: Guthe SP, Pravin S, Darade P, Velho V. Silent migration of ventriculoperitoneal shunt per anus in a child: Management and review of literature. *Asian J Neurosurg* 2018;13:446-8.

This is an open access journal, and articles are distributed under the terms of the Creative Commons Attribution-NonCommercial-ShareAlike 4.0 License, which allows others to remix, tweak, and build upon the work non-commercially, as long as appropriate credit is given and the new creations are licensed under the identical terms.

For reprints contact: reprints@medknow.com

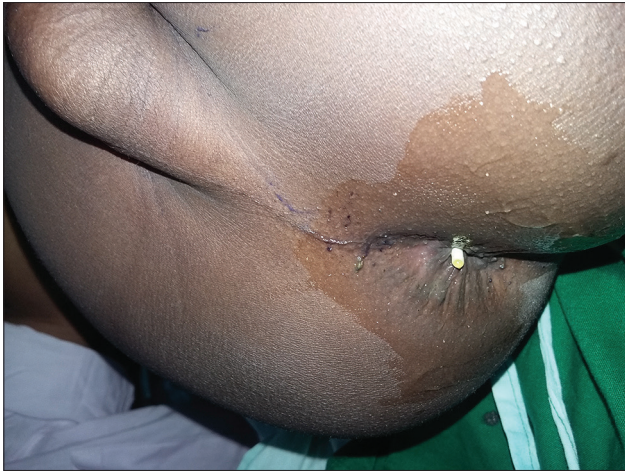

Figure 1: Shunt tube coming out per anus

diversion procedure needed. Shunt tip showed no bacterial growth on the routine aerobic culture.

Discussion

The term hydrocephalus is derived from the Greek words “hydro” meaning water and “cephalus” meaning head. As the name implies, it is a condition in which the primary characteristic is an excessive accumulation of fluid in the brain. It is a commonly encountered entity in neurosurgical practice. Shunt remains the most common procedure done for hydrocephalus. Shunts can be VP, theco-peritoneal, ventriculoatrial, or ventriculopleural. VP shunt is associated with a complication rate of 24–47%, of which mechanical blockage of the shunt is most common.^[1]

The risk of abdominal complication associated with VP shunt is 25%, and incidence of bowel perforation with protrusion of VP shunt per anus is 0.1–0.7%.^[2,3]

Bowel perforation is a rare but serious complication of VP shunt surgery. It has high mortality rate around 15%.^[4] It is very important to identify this unusual serious complication as it carries a risk of ascending infection to the brain in the form of meningitis, encephalitis, or brain abscess.^[5,6]

Sharma *et al.*^[7] reported a similar case of a child of 2 years who presented with the lower end of the ventriculoperitoneal shunt tube coming out through the anus. The child was asymptomatic on presentation. Colonoscopy revealed the site of perforation to be in the rectum, 10 cm from the anal verge. After disconnecting the cranial end of the shunt, it was removed endoscopically without any further complications.

Teegala and Kota^[8] reported two cases of anal extrusion and pointed that the poor nutritional status along with infection could have been the precipitating cause.

In the majority of the cases, bowel perforation is asymptomatic. A few can present with complications such as intestinal obstruction, adhesion, and tube knotting, which

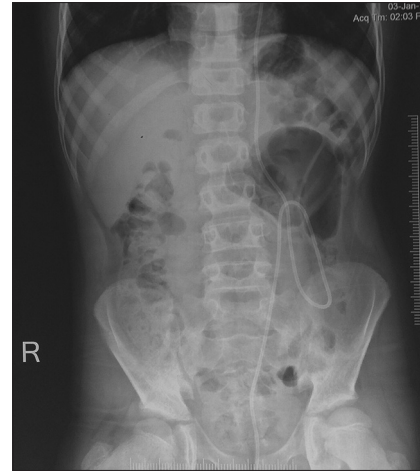


Figure 2: X-ray abdomen erect showing distal end of ventriculoperitoneal shunt tube going well beyond pubic symphysis

warrant skilled management.^[9-11] Because of weak bowel musculature, children are more susceptible to intestinal perforation.^[12]

Various mechanisms have been suggested with regard to the pathogenesis of the perforation, namely, foreign body reaction, pressure necrosis of intestinal wall by the tube, and silicon tube allergy. The catheter, most commonly associated with perforations, is the Raimondi spring coiled catheter. The introduction of softer, more flexible silastic tubing has reduced but not totally eliminated the incidence of bowel perforation.^[13] There have been suggestions to anchor the distal end of the peritoneal tube to the peritoneum in children. This simple method does not add much to the operation time and has prevented shunt-tube migration in the group studied.^[14] The perforation of the bowel lumen can also occur when the freely moving catheter gets adherent to the serosa of a viscus and the beveled end of the tube, coupled with the continuous water hammer effect of the CSF pulsations, penetrate the walls, and eventually perforate the viscus. Thereafter, the peristaltic waves drive the “foreign body” forward.^[15]

In our case, the patient was operated for the malfunctioning of peritoneal end 6 months prior and postoperatively had abdominal distension. We suggest abdominal adhesions and thin bowel wall in a child were possible mechanism leading to bowel perforation and subsequently anal extrusion of VP shunt.

The management of these cases involves shunt removal/exteriozation, control of infection, and reinsertion of the shunt at an appropriate time. Asymptomatic cases without peritonitis and meningitis can safely be managed by simply removing shunt per anus, after disconnecting the shunt tube in the neck. Rest of the shunt system can then be removed through parieto occipital incision. This will obviate the need for laparotomy. However, in cases where serious abdominal complications such as peritonitis,

infected pseudocyst, or an abscess develop, exploratory laparotomy is required for removing the shunt catheter and tackling the problem accordingly.^[7] It is also important to check knotting of the shunt tube on the plain radiograph abdomen. Knotting of shunt tube can create difficulties during shunt removal per anus. In such case, it is better to go for exploratory laparotomy rather than simply removing shunt per anus.

Bowel perforation in patients with VP shunt should be considered with Gram-negative meningitis or abdominal symptoms. The optimum treatment of such a patient would be decided by the presence of features of sepsis, perforation peritonitis, or intraperitoneal abscess. In a patient with simple bowel perforation and no other complications, a formal exploratory laparotomy is not required. The shunt should be disconnected at the abdominal wall, and the lower end should be removed through the rectum by colonoscopy or sigmoidoscopy/proctoscopy. The distal end of the VP shunt should not be pulled back into the peritoneal cavity to prevent contamination of the tract. External ventriculostomy should be established at least for 3 weeks and the patient should be put on broad spectrum antibiotics to prevent infection of CSF. After repeated CSF cultures are sterile, the patient should undergo repeat VP shunt on the opposite side. In patients with bowel perforation peritonitis, they should undergo exploratory laparotomy with removal of the shunt, thorough lavage, and primary closure of the bowel wall.^[16]

The treatment of a VP shunt perforating the bowel is a medical emergency. The perforating part of the catheter must be removed, and an external drainage of the proximal part is needed together with antibiotic prophylaxis. In general, there are three methods by which the catheter can be removed: By pulling it through the anus, by endoscopic removal, or by surgical removal. Nevertheless, the management of the bowel perforation must be individualized. The shunt is externalized at its upper end, and once the CSF cultures are negative, a new peritoneal shunt catheter can be placed intra-abdominally few weeks later. If there is no accompanying peritonitis or abdominal abscess, then percutaneous or endoscopic removal of the abdominal shunt catheter can be performed without surgery. The fibrous tissue surrounding the perforation does not permit the spillage of bowel contents into the peritoneal cavity. Laparotomy must be performed in cases of intra-abdominal infection (peritonitis or abscess) or when the fistulous tract does not close spontaneously after percutaneous or endoscopic removal.^[17]

Awareness of this unusual complication among general surgeons and physicians is very important so that early recognition, management, and timely intervention can save the life of the patient. Our case highlights the rarity of this complication, pathogenesis, and its management. There is

no need to hurry for CSF diversion procedures unless the patient is clinically symptomatic.

Financial support and sponsorship

Nil.

Conflicts of interest

There are no conflicts of interest.

References

- Grewal SS, Jhavar SS, Gupta B, Bedi NK. Silent bowel perforation with per anal protrusion of ventriculoperitoneal shunt. *CHRISMED Journal of Health and Research* 2014;1:113-5.
- Ghritlaharey RK, Budhwani KS, Shrivastava DK, Gupta G, Kushwaha AS, Chanchlani R, et al. Trans-anal protrusion of ventriculo-peritoneal shunt catheter with silent bowel perforation: Report of ten cases in children. *Pediatr Surg Int* 2007;23:575-80.
- Yilmaz N, Krymaz N, Yilmaz C, Casken H, Yuca SA. Anal protrusion of ventriculoperitoneal shunt catheter: Reports of two infants. *J Pediatr Neurol* 2004;2:241-4.
- Snow RB, Lavyne MH, Fraser RA. Colonic perforation by ventriculoperitoneal shunts. *Surg Neurol* 1986;25:173-7.
- Ibrahim AW. *E. coli* meningitis as an indicator of intestinal perforation by V-P shunt tube. *Neurosurg Rev* 1998;21:194-7.
- Jindal A, Kansal S, Mahapatra AK. Unusual complication – VP shunt coming out per rectum and brain abscess. *Indian J Pediatr* 1999;66:463-5.
- Sharma A, Pandey AK, Diyora B, Shah S, Sayal P. Management of ventriculo-peritoneal shunt protruding through anus. *Indian J Surg* 2006;68:173.
- Teegala R, Kota LP. Unusual complications of ventriculo-peritoneal shunt surgery. *J Neurosci Rural Pract* 2012;3:361-4.
- Sridhar K, Karmarkar V. Peroral extrusion of ventriculoperitoneal shunt: Case report and review of literature. *Neurol India* 2009;57:334-6.
- Yousfi MM, Jackson NS, Abbas M, Zimmerman RS, Fleischer DE. Bowel perforation complicating ventriculoperitoneal shunt: Case report and review. *Gastrointest Endosc* 2003;58:144-8.
- Sharma A, Pandey AK, Radhakrishnan M, Kumbhani D, Das HS, Desai N. Endoscopic management of anal protrusion of ventriculoperitoneal shunt. *J Gastroenterol* 2003;22:29-30.
- Jang HD, Kim MS, Lee NH, Kim SH. Anal extrusion of distal VP shunt catheter after double perforation of large intestine. *J Korean Neurosurg Soc* 2007;47:232-4.
- Hornig GW, Shillito J Jr. Intestinal perforation by peritoneal shunt tubing: Report of two cases. *Surg Neurol* 1990;33:288-90.
- Azzam NI. An attempt to prevent the problem of shunt-tube migration. *Childs Nerv Syst* 1988;4:50-1.
- Handa R, Kale R, Harjai MM. Unusual complication of ventriculoperitoneal shunt: Anal extrusion. *MJAFI* 2007;63:82-4.
- Hai A, Rab AZ, Ghani I, Huda MF, Quadir AQ. Perforation into gut by ventriculoperitoneal shunts: A report of two cases and review of the literature. *J Indian Assoc Pediatr Surg* 2011;16:31-3.
- Birbilis T, Zezos P, Liratzopoulos N, Oikonomou A, Karanikas M, Kontogianidis K, et al. Spontaneous bowel perforation complicating ventriculoperitoneal shunt: A case report. *Cases J* 2009;2:8251.