

Pseudo Primary Abscess of the Cavum Septum Pellucidum due to Pus Entrapment: A Rare Case Report

Abstract

The cavum septum pellucidum (CSP) is defined as a crevice-like space of variable width between the left and right transparent septum. In this report, a rare case of pseudo primary abscess formed in the CSP due to ventriculitis is presented.

Keywords: *Cavum septum pellucidum, pseudo primary abscess, ventriculitis*

Introduction

The cavum septum pellucidum (CSP) is defined as a crevice-like space of variable width between the left and right transparent septum. The CSP and other ventricles communicate with each other, and cerebrospinal fluid (CSF) enters the CSP from the third and lateral ventricles, in which CSF is produced. In this report, a rare case of a pseudo primary abscess formed in the CSP due to ventriculitis is presented.

Case Report

A 22-year-old man was admitted to the hospital because of fever, vomiting, headache, and altered sensorium. His temperature was 38°C. Neurological evaluation showed that he was in a state of confusion. His neck was stiff and Kernig and Lasague signs were positive. A lumbar puncture yielded white cloudy CSF. The CSF contained 1800 white cells/mm³, of which 85% were neutrophils; and the protein concentration was 100 mg/100 ml. Initial computed tomography (CT) and magnetic resonance imaging performed showed a CSP in his brain. The CSP was enhanced by contrast materials [Figures 1 and 2]. The patient was treated with intravenous administration broad spectrum antibiotics. On the 4th day in hospital, the patient's condition deteriorated and he went in no motor response. A repeat scan showed ventriculomegaly [Figure 3] and immediately a ventriculoperitoneal

shunt was inserted. An abscess in CSP was suspected, and the patient was planned for drainage of the abscess through interhemispheric approach. The patient continued to receive intravenous broad spectrum antibiotics. The size of the abscess decreased markedly on a CT, which was performed after the surgery [Figure 4].

Discussion

The width of CSP is between 6 mm and 20 mm. In addition, expansion or inside lesions of the cava can produce symptoms by distorting the vessels, compressing the hypothalamo-septal triangle, or compressing the optic pathways.^[1-3] Fenestration to the lateral ventricles, cystoventriculoatrial shunts or cystoperitoneal shunts have been recommended in symptomatic cases because spontaneous regressions have only occurred in three cases reported in the literature.^[1,4-6]

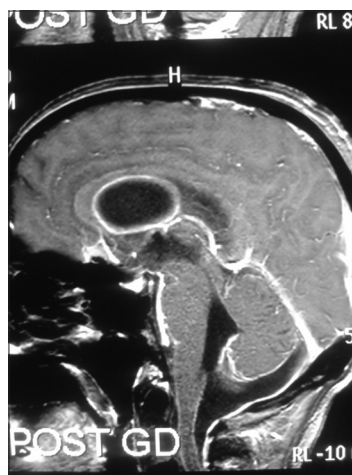


Figure 1: Sagittal contrast magnetic resonance showing abscess in cava

How to cite this article: Ansari A, Gandhi A, Mittal RS, Sharma A. Pseudo primary abscess of the cavum septum pellucidum due to pus entrapment: A rare case report. *Asian J Neurosurg* 2018;13:394-5.

**Ahmed Ansari,
Ashok Gandhi,
R. S. Mittal,
Achal Sharma**

*Department of Neurosurgery,
SMS Medical College, Jaipur,
Rajasthan, India*

Address for correspondence:

*Dr. Ahmed Ansari,
Department of Neurosurgery,
SMS Medical College, Jaipur,
Rajasthan, India.
E-mail: ahmed.ansari2@gmail.
com*

Access this article online

Website: www.asianjns.org

DOI: 10.4103/1793-5482.228514

Quick Response Code:



This is an open access journal, and articles are distributed under the terms of the Creative Commons Attribution-NonCommercial-ShareAlike 4.0 License, which allows others to remix, tweak, and build upon the work non-commercially, as long as appropriate credit is given and the new creations are licensed under the identical terms.

For reprints contact: reprints@medknow.com

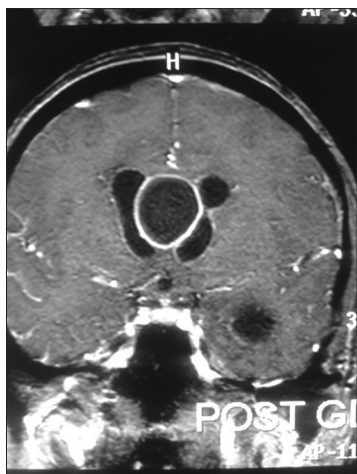


Figure 2: Coronal contrast magnetic resonance imaging showing abscess in cava

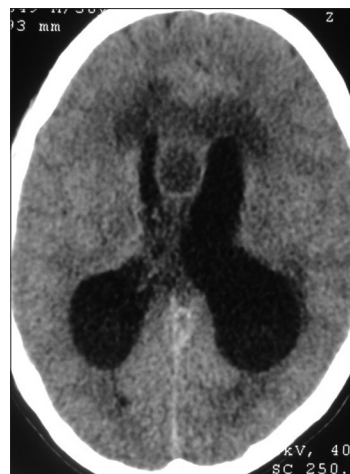


Figure 3: Axial computed tomography scan showing ventriculomegaly

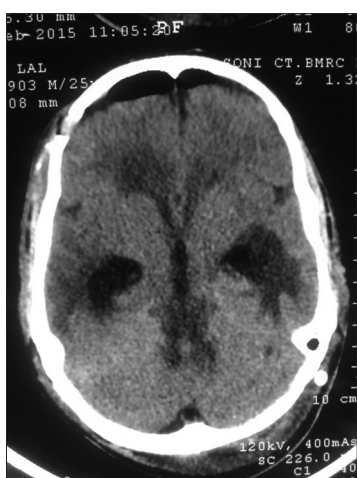


Figure 4: Axial computed tomography scan showing reduced abscess in cavum septum pellucidum

In this case, an abscess was formed in the CSP, probably due to ventriculitis. One explanation for this phenomenon is the slow filling and delayed clearance theory.^[7] It seems that there was delayed filling of purulent CSF and clearance of CSF from the CSP to other ventricles is slow. Some CSPs might be noncommunicating, the CSF of which might filter through the septal laminae and be reabsorbed by vessels of the septa.^[8] In this form of CSP, however, purulent CSF would not directly enter the CSP and it is unlikely that abscess formation or clearance of the abscess would occur. In the case of a communicating CSP, the CSF flow continues and purulent CSF would enter the CSP. Clearance of the CSF would be delayed because of its pouched shape with one

entrance. This condition is very rare and it is important to look for ventriculomegaly if the condition of the patient deteriorated.

Financial support and sponsorship

Nil.

Conflicts of interest

There are no conflicts of interest.

References

1. Li ST, Chiu NC, Hsu CH, Chiang MF. Empyema of the cavum septum pellucidum. *Pediatr Neurol* 2002;26:391-3.
2. Lancon JA, Haines DE, Raila FA, Parent AD, Vedanarayanan VV. Expanding cyst of the septum pellucidum. Case report. *J Neurosurg* 1996;85:1127-34.
3. Bikmaz K, Dinc C, Cakabay M, Iplikcioglu AC. Epidermoid cyst of the cavum septum pellucidum. *Acta Neurochir (Wien)* 2007;149:1271-2.
4. Koçer N, Kantarci F, Mihmalli I, Islak C, Cokyüksel O. Spontaneous regression of a cyst of the cavum septi pellucidi. *Neuroradiology* 2000;42:360-2.
5. Sencer A, Sencer S, Turantan I, Devecioglu O. Cerebrospinal fluid dynamics of the cava septi pellucidi and vergae. Case report. *J Neurosurg* 2001;94:127-9.
6. Sayama CM, Harnsberger HR, Couldwell WT. Spontaneous regression of a cystic cavum septum pellucidum. *Acta Neurochir (Wien)* 2006;148:1209-11.
7. Abe H, Tsuchida T, Mori S. Empyema of cavum septi pellucidi and cavum vergae – Case report. *No Shinkei Geka* 1986;14:1271-4.
8. Oteruelo FT. On the cavum septi pellucidi and the cavum Vergae. *Anat Anz* 1986;162:271-8.