

## “Sinking Bone” Flap Presenting as Reversible Postural Hemiparesis

Sir,

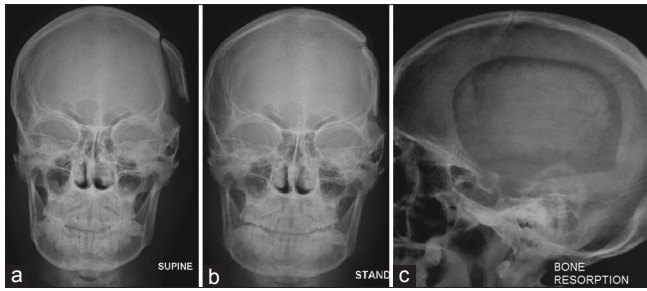
A 35-year-old man underwent decompressive craniotomy for left temporal contusion with acute subdural hematoma. His bone flap was stored in the abdomen. He underwent cranioplasty 6 months later. The bone was anchored to the craniotomy margins with sutures. At the time of cranioplasty, he had no detectable motor deficit. One-year after cranioplasty, he presented with complaints of unease, headache and heaviness and weakness of the right upper and lower limbs which increased as the day progressed with improvement over the night. There was a subjective sensation of mobility of the implanted flap as well. There was no history of seizures, and his electroencephalogram was unremarkable. Imaging showed no infarct or hydrocephalus. He was given anti-anxiety medications. Over the next 1 year, his problems progressed. X-rays in supine and sitting positions showed the clear movement of the flap inward when he was seated [Figure 1a and b] with evidence of bone resorption at the margins [Figure 1c]. The patient was reoperated, and the flap was fixed rigidly with mini-plates and screws and his symptoms subsequently abated.

We only found six previous reports of symptomatic sinking bone flap times in literature in which postural variation of symptoms was found in three [Table 1]. Rengachary *et al.*<sup>[1]</sup> have described a case of reversible constructional apraxia from a floating bone flap and reported that the flap depression was not prominent early in the morning after he got up from sleep but was worse in the evening after ambulating the whole day. While this occurred 1 year after flap replacement, Anei *et al.*<sup>[2]</sup> have described delayed bone flap sinking, leading to hemiparesis, 15 years after the initial surgery and have emphasized the need for tight cranial-fixation. In both these cases, the flap had been replaced at the initial surgery. On the other hand, Reddy *et al.*<sup>[3]</sup> and Di Rienzo *et al.*<sup>[4]</sup> have described cases where the bone flap that sunk inward was not replaced primarily but rather after interval cranioplasty. They have held bone resorption to be responsible for the same. In all these cases, either the same bone was refixed, or hydroxyapatite cranioplasty was performed with complete recovery, thus indicating that the cause of fresh neurological deficits was not a permanent structural damage to the brain by the mobile bone flap.

**Table 1: Summary of cases of sinking bone flap described in literature**

Author (year)	Duration from initial surgery to sunken flap	Presenting complaints	Outcomes
Rengachary <i>et al.</i> (1979) <sup>[1]</sup>	1 year	Dizziness, gait disturbance, memory impairment Flap movement noticeable with diurnal postural variation	Refixation done with addition of methylmethacrylate Prompt resolution of symptoms
Anei <i>et al.</i> (2010) <sup>[2]</sup>	15 years	Contralateral hemiparesis	Refixation done Symptoms improved
Reddy <i>et al.</i> (2013) <sup>[3]</sup>	6 years after cranioplasty	Progressive hemiplegia	Refixation done
Di Rienzo <i>et al.</i> (2013) <sup>[4]</sup>	First patient - 1 year after cranioplasty Second patient - 4 years after cranioplasty	Headache on getting up followed by confusion, difficulty in walking progressing to third nerve palsy and hemiplegia. Symptoms aggravated by erect position and relieved on lying down. Flap movement noticeable with postural variation Fatigue, confusion, worsening of hemiparesis, diplopia and ptosis on assuming erect posture and hemiparesis with regression on lying down	Flap replaced by hydroxyapatite implant. Complete neurological recovery Flap replaced by hydroxyapatite implant. Complete neurological recovery
del Mar Carmona Abellán <i>et al.</i> (2012) <sup>[5]</sup>	2 months	Hemiparesis, speech disorder, depressed sensorium	Bone refixed Significant improvement
Present case	1 year after cranioplasty	Headache, heaviness and weakness of contralateral limbs with change in posture. Flap movement noticeable with postural variation	Bone refixed with complete recovery

The cases with postural variation have been provided in bold



**Figure 1:** Anteroposterior skull X-rays in (a) supine and (b) standing views showing mobility of flap with posture and (c) lateral skull X-ray showing resorption of the bone flap

del Mar Carmona Abellán *et al.*<sup>[5]</sup> described a case where a patient had hemiparesis, speech disturbances, and decreased level of consciousness with a sunken bone flap and performed a fludeoxyglucose positron emission tomography (FDG-PET) study before and after refixation. This showed hemispheric hypometabolism in the area below the sunken flap that reverted to normal after surgery with corresponding clinical improvement of the patient. Hence, they hypothesized that deficits were due to impaired brain metabolism secondary to hemodynamic derangement.

We felt that neurological symptoms in our patient were likewise consequent to a decreased cerebral perfusion in the erect position due to compression of the brain by the skull flap. However, as comparative FDG-PET or computed tomography perfusion study would not be possible preoperatively since it would require studies in both erect and supine positions, we had to proceed with the X-ray findings alone.

In our case too, an interval cranioplasty had been performed. The bone had been placed in an abdominal pocket where it might have undergone resorption – which might have precipitated its sinking in. In many centers, such as ours, sutures remain the mainstay of fixation – and we would like to emphasize the role of firm fixation particularly in cases of interval cranioplasty where the bone flap might undergo some resorption during storage *in vivo*.

To conclude, the surgeon must be aware that complications may occur even long after satisfactory performance of a cranioplasty. There is a need to investigate any change in the patients' neurological status carefully and not attribute it to the original insult for which the decompressive craniotomy was performed. The sinking bone flap syndrome may present initially with protean manifestations that may be related to changes in posture and may not show up on conventional imaging done in a supine posture. Getting an X-ray done in lying down and standing position is a simple tool by which this diagnosis can be confirmed. Literature suggests that these patients have a good outcome on refixation of the bone

flap and surgery must be offered to these individuals if other causes of deterioration can be ruled out.

### Financial support and sponsorship

Nil.

### Conflicts of interest

There are no conflicts of interest.

### Prasad Krishnan, Rajaraman Kartikueyan, Sachinkumar Maheshbhai Patel, Sayan Das<sup>1</sup>

Department of Neurosurgery, National Neurosciences Centre,  
<sup>1</sup>Department of Radiodiagnosis, Peerless Hospital and B K Roy Research Centre, Kolkata, West Bengal, India

#### Address for correspondence:

Dr. Prasad Krishnan,  
 National Neurosciences Centre, Peerless Hospital Campus, 2<sup>nd</sup> Floor, 360 Panchasayar, Garia, Kolkata - 700 094, West Bengal, India.  
 E-mail: prasad.krishnan@rediffmail.com

### References

1. Rengachary SS, Amini J, Batnitzky S. Reversible constructional apraxia from a floating bone flap. *Neurosurgery* 1979;5:365-7.
2. Anei R, Uemori G, Orimoto R, Saito M, Hiroshima S, Mitsui N, *et al.* A case of brain herniation due to delayed bone flap sinking. *No Shinkei Geka* 2010;38:923-6.
3. Reddy S, Alugolu R, Kumar A. Sinking of bone flap-looking beyond cosmesis and costs. *Surg Neurol Int* 2013;4:20.
4. Di Rienzo A, Iacoangeli M, Alvaro L, Colasanti R, Dobran M, Di Somma LG, *et al.* The sinking bone syndrome? *Neurol Med Chir (Tokyo)* 2013;53:329-35.
5. del Mar Carmona Abellán M, Murie Fernández M, Esteve Belloch P. Cranioplasty sinking should affect normal brain function mimicking other neurologic illness. *AJNR Am J Neuroradiol* 2012;33:E65.

This is an open access journal, and articles are distributed under the terms of the Creative Commons Attribution-NonCommercial-ShareAlike 4.0 License, which allows others to remix, tweak, and build upon the work non-commercially, as long as appropriate credit is given and the new creations are licensed under the identical terms.

Access this article online	
<b>Quick Response Code:</b> 	<b>Website:</b> <a href="http://www.asianjns.org">www.asianjns.org</a>
	<b>DOI:</b> 10.4103/1793-5482.228513

**How to cite this article:** Krishnan P, Kartikueyan R, Patel SM, Das S. "Sinking Bone" flap presenting as reversible postural hemiparesis. *Asian J Neurosurg* 2018;13:534-5.

© 2018 Asian Journal of Neurosurgery | Published by Wolters Kluwer - Medknow